

Dissociation of Color From Object in Amnesia

Armin Schnider, MD; Theodor Landis, MD; Marianne Regard, PhD; D. Frank Benson, MD

• A patient with persistent amnesia after bilateral medial temporal and left inferotemporo-occipital infarction could not match colors to objects in verbal, visual, or visuoverbal tasks. A severe naming disorder for objects was present but the patient could name colors and point to colors whose name was given. The matching disorder appeared to be a deficit in the semantic classification of objects rather than a problem in identifying colors.

(*Arch Neurol.* 1992;49:982-985)

Colors appear to follow anatomically distinct pathways in the visual system, as do form, movement, and depth,¹ and color perception can be disturbed separately. A mass of terms has been used to identify variations in color identification. *Central achromatopsia*, the acquired loss of color perception with preserved form recognition, indicates a lesion of the lingual and fusiform gyrus of the occipital lobe.^{2,3} These patients, of course, cannot name colors. *Color anomia* has been used to designate an inability to name colors despite preserved color perception as evidenced by correct color-color matching. The term is not precise, color anomia also includes an inability to point to named colors.^{4,5} Color anomia has also been termed *color-name aphasia*.⁵ *Color agnosia*, as used by most authors, describes the inability of patients with preserved color perception to name the specific colors of objects on verbal request (eg, "what is the color of a tomato?") or to color line drawings.^{4,6-8} Other authors have termed this disorder *color amnesia* and reserved the term color agnosia to describe an inability to select all colors of the same hue from a group of colors in patients who could still match colors and objects.^{9,10} In this article, color agnosia will be used to designate an inability to indicate the specific colors of objects despite preserved color perception.

Initial studies of patients with color agnosia suggested an association with aphasia and alexia,^{11,12} an observation since corroborated.^{9,10,13} The typical lesion involves the posterior part of the left hemisphere.^{9,10,14} Disturbances in attributing colors to objects are rare in patients with right-

hemisphere lesions and are associated with color perception deficits.⁹

Descriptions of patients with disturbances in attributing colors to objects routinely describe color anomia as well. We present a patient with a global amnesia due to bilateral medial temporal lobe and left-sided inferotemporo-occipital infarction who could not indicate the color of common objects nor appropriately color line drawings of objects despite preserved recognition and naming of colors.

REPORT OF A CASE

A 66-year-old man was admitted to hospital because of sudden disorientation. He was a heavy smoker and had been treated for hypertension for several years. He had suffered two myocardial infarctions and had undergone three aortocoronary bypasses 6 years previously with good recovery. On the morning of admission he was confused on awakening, could not orient himself in his bedroom, spoke incoherently, and complained of weakness of his right leg.

On admission, his blood pressure was 160/90 mm Hg and the pulse was regular. There was a right homonymous upper quadrantanopia and a moderate right hemiparesis involving the arm and the leg that resolved within a few days. A computed tomographic scan showed a questionable left posterior hypodensity involving the medial part of the occipital lobe. Doppler ultrasound examination showed nonstenotic plaques in the carotid bifurcation on both sides, while the vertebral and basilar arteries were normal. An echocardiogram evidenced an anterior myocardial aneurysm with mural thrombi, which prompted oral anticoagulation therapy. Magnetic resonance imaging on the seventh day (Fig 1) showed bilateral medial temporal lobe infarcts. On the left side, the hippocampus, the parahippocampal, fusiform, and posterior inferior temporal gyri as well as the inferior aspect of the occipital lobe were involved. On the right side, a smaller infarct involved the body of the hippocampus and the anterior half of the parahippocampal and fusiform gyri.

The patient remained severely disoriented in time and space, could give no account of his personal and medical history and repeatedly asked the same questions about where he was and what had happened. The only people he recognized were his wife and his children. When he left his hospital bedroom for only a few seconds, he could not find his way back. He was friendly and cooperated fully in the examinations, but could not recall either the examiners or the events of previous examinations.

Digit span was five forward and three backward for numbers and five forward and five backward for the Corsi cubes. His speech was fluent and correct without paraphasia. Repetition was normal. Auditory comprehension was good, even for syntactically complex sentences. Long sentences could not be repeated and multistep commands executed to the extent the sentence could be repeated. Confrontation naming was severely impaired

Accepted for publication March 12, 1992.

From the Department of Neurology, University Hospital, Zürich, Switzerland (Drs Schnider, Landis, and Regard), and Department of Neurology, UCLA School of Medicine, Los Angeles, Calif (Drs Schnider and Benson).

Reprint requests to the Neurobehavior Program, UCLA Department of Neurology, 710 Westwood Plaza, Los Angeles, CA 90024-1769 (Dr Schnider).

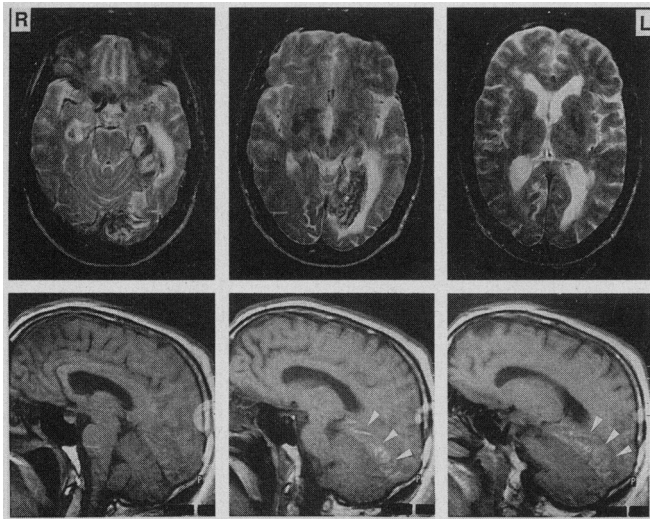


Fig 1.—Magnetic resonance imaging of the brain. Top, Horizontal sections (TR 2000, TE 100, gadolinium enhanced) showing infarcts of the hippocampal area bilaterally. The lesion on the left side is much larger and involves the inferior temporal and occipital lobe. The medial temporo-occipital junction is spared; bottom, sagittal sections (TR 600, TE 15) of the left hemisphere. The most medial section shows no involvement of the medial temporo-occipital junction. More laterally, the infarct involves the inferior posterior temporal and inferior occipital lobe (arrows).

(see below). In a sentence completion task (eg, “a chair has four . . .”), however, correct object names were presented in 18 of 20 cases. Reading was fluent without paralexia but comprehension was impaired as only the very last item was recalled. Writing was correct with both the right and left hand. Oral calculations of two-digit numbers and written calculations of three-digit numbers were done flawlessly. There was no ideomotor apraxia to verbal command.

Both anterograde and retrograde amnesia were severe. In the auditory verbal learning test of Rey,¹⁵ he immediately recalled two, two, three, four, and four of the 15 words in five trials. He recalled none after 5 minutes and cuing was not helpful. Of 10 drawings chosen from the figural learning test of Rey,¹⁵ he recalled only the last one on four trials and after 5 minutes, he recalled none. His recall of the correctly copied complex figure of Rey¹⁶ was zero. Retrograde amnesia was probed through an extensive interview concerning autobiographic memory and knowledge about important events and famous people from all decades since his birth with the answers checked by his wife. He had some vague ideas of major events (eg, that “Chernobyl” was “a bad event”), but could not tell details or dates. The retrograde amnesia extended back to his childhood years and provided no clear time gradient except for the last premorbid year, for which even vague ideas were lacking.

Naming to confrontation was strikingly deficient and independent of the modality of presentation. In the visual modality, only one (7%) of 15 line drawings of common objects could be named. In the tactile modality two (8%) of 25 common objects, in the auditory modality zero of nine environmental sounds, and in the olfactory modality two (17%) of 12 common smells could be named. Recognition was much better than naming as evidenced by correct designation of the use or characteristics of materials or by appropriate gestures indicating the use of objects, even though deficient for some materials (common objects, visual modality 67% correct; real objects, tactile modality 100%; environmental sounds 40%; smells 92%). Color naming was largely spared (seven [70%] of 10) and color recognition was normal (100% of named colors recognized). Photographs of family members were correctly named (eight [100%] of eight) but famous people (politicians and movie stars) could not be named at all (zero of six) and were only occasionally recognized (two [33%] of six). Finally, he

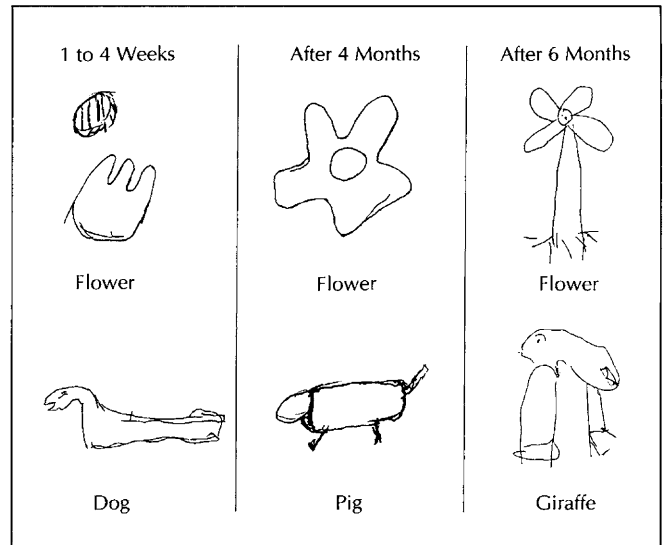


Fig 2.—Examples of drawings on command, which the patient performed within the first 4 weeks after stroke, and after 3 and 6 months. The drawing of a flower improved and is recognizable after 6 months. Drawings of animals show only slight improvement with more details.

correctly named places within his own home displayed on photographs (seven [88%] of eight; 100% recognized), while he could rarely name and recognize photographs of famous Swiss sites (five [36%] of 14; 50% recognized when tested 3 months after stroke).

Color Tests

Color perception was preserved as evidenced by a normal performance on the 16 hue Farnsworth Color Perception Test¹⁷ and mostly, colors could be named (70%). The patient had no difficulties pointing to the color whose name was given within an array of 10 color chips or to match color chips with each other. However, when given the name of an object like fruit or animals with typical colors he named the wrong color in four (50%) of eight cases. For example, he indicated “brown” as the color of a banana or “red” as the color of the sky without clouds. His performance was equally deficient when he had to point to the chip with the color typical of an object whose name was given (three [43%] of seven correct). His performance was even worse when he was requested to color line drawings of common scenes or objects (one [14%] of seven correct), all of which he seemed to recognize reasonably precisely as estimated from his description of the meaning of the drawings. For example, he chose dark green as the color of a banana, brown for strawberries, and yellow for the sky. He had considerable difficulties producing line drawings of common objects; even though the object’s category was mostly recognizable, details were either lacking or wrong and the drawings were strongly simplified (Fig 2). For example, a dog was recognizable as an animal but lacked the legs.

Course

Over the following 6 months, the amnesia persisted and the patient remained entirely dependent on his wife. He did not remember any event occurring after his stroke. The retrograde amnesia remained practically complete. Naming improved slightly for several categories (common objects, visual 36%; real objects, tactile 29%, environmental sounds 54%, common smells 25%), and the pattern of better preserved naming of colors (100% by 3 months, 71% at 6 months), familiar persons (100% as opposed to 0% of famous people) and familiar places (88% as opposed to 36% of famous places) persisted. Visual recognition of common objects normalized (100% correct). The performance in color name-object name matching improved, so that he could indicate the color of common objects in eight (72%) of 11 cases. Drawings of common

objects were slightly better but still deficient. For example, he drew a clock correctly but put the numbers in the anticlockwise direction.

COMMENT

This patient with global amnesia following a bilateral medial temporal lobe and left-sided occipital infarct presented with an unusual disorder of the handling of colors. Even though he perceived colors, could name them, and could point to colors named by the examiner, he failed to attribute colors to objects in verbal, nonverbal, and cross-modal tasks. He had a deficit in visual imagery. To our knowledge, only Engerth¹⁸ published a case with a somewhat related dissociation of color and form of objects despite preserved color naming and recognition. This patient suffered from an amnesic aphasia and alexia due to a stroke. Even though he could name all colors, he did not spontaneously use the blue color when coloring line drawings or copying colored drawings after a delay. However, he would use the blue color when immediately copying drawings. This behavior might have been due to a color perception deficit, a partial central achromatopsia, as this tends to involve the blue and yellow axes while red is relatively spared.² In our patient, however, a primary defect of color perception was excluded on the basis of a normal performance in color matching and in the 16 hue Farnsworth Color Perception Test.¹⁷

Lewandowsky¹¹ attributed the dissociation of color and form to color anomia. In his opinion colors are meaningful only if associated with an object ("What should be the meaning of 'red' if I cannot recognize it as the color of a cherry or blood?"). In this sense a color-naming disorder readily explains a disturbance of attributing a color to an object. Lewandowsky's opinion is shared by Damasio et al¹⁹ who observed patients with color anomia making errors when coloring line drawings. They might first choose the correct color pencil, then aloud give it a wrong verbal label and on the basis of this error choose another color. Damasio et al consider color agnosia a consequence of color anomia. However, patients with color anomia can usually match colors to objects if the task is not cross-modal, ie, if it is verbal (answers to questions about the color of objects) or visual (coloring line drawings).^{4,5} It seems that an additional factor is involved in color agnosia. It has been considered a disorder of the concept of color-object association,^{9,10,20} or a memory problem in which the patient has "forgotten" the color of objects,^{9,10} or a true agnosia in which a patient can perceive colors but cannot appreciate the meaning of colors.¹⁴ Recent studies have indicated that color agnosia is not a precise disorder; patients with color agnosia may differ in performance depending on the imagery demands of the task, and it has been suggested that color agnosia can result from a disturbed access to the color lexicon or from an imagery disturbance.^{21,22}

It is difficult to attribute our patient's inability to associate colors with objects to color "agnosia" as he named colors. His amnesia offers another explanation. In addition to the complete anterograde amnesia, the patient had a severe disturbance of the "semantic memory"²³ or "memory for facts,"²⁴ evident in the anomia, deficient visual imagery, and partial recognition defect. Even though not aphasic he had a severe anomia for materials presented in all modalities, and he often failed to recognize the material. In addition, a visual imagery problem was evident in his line

drawings that were grossly simplified and lacked details. These defects suggest a disorder concerning the classification of objects. On the other hand, the naming and recognition of colors were exceptionally well preserved. We conjecture that our patient's inability to attribute colors to objects was a disorder of the identification and semantic classification of objects, not a disorder of color processing. This assumption is supported by the observation that the dissociation of colors and objects faded as the visual recognition of objects normalized and visual imagery improved.

What lesion might be responsible for this disorder? Color agnosia has not been reported as a feature of amnesia due to pure medial temporal lobe lesions, eg, bilateral hippocampectomy.^{25,26} Thus, the bilateral medial temporal infarct of our patient, which accounts for the complete anterograde amnesia, does not appear to explain the disorder. Our patient also had a left-sided inferotemporo-occipital lesion. Cirillo et al,²⁷ on the basis of inferotemporal cooling experiments in animals, do not believe that the inferotemporal cortex acts as a storage site for visual information. But animals with inferotemporal lesions do have difficulty discriminating between visual stimuli, a problem that seems to be due to an inability to simplify the perception of a stimulus, ie, to categorize it, to such a degree that it can be precisely identified.²⁸ Such a disturbance could also account for our patient's problem in associating colors to objects.^{8,29} We surmise that the left-sided inferotemporo-occipital extension of our patient's infarct was responsible for his disorder in color-form association.

Finally, why did this patient not have color anomia or alexia? Patients with "Pötzl syndrome," ie, alexia and color anomia, have lesions that prevent information transfer from the visual areas of both hemispheres to the language areas in the left hemisphere, specifically the angular gyrus.^{4,5,30} The lesion in our patient did not extend dorsally to prevent information transfer to the angular gyrus nor involve the splenium. Mohr et al³¹ presented a patient with color anomia without alexia whose lesion involved not only the parahippocampal and fusiform gyrus but also the left lingual gyrus in the mesial temporo-occipital junction. The area of the mesial temporo-occipital junction was spared in our patient. Preservation of mesial temporo-occipital cortex is consistent with our patient's preservation of color naming, a conclusion agreeing with Damasio and Damasio's³⁰ suggestion that lesions causing color anomia involve the mesial occipitotemporal junction.

In summary, a patient with a global amnesia due to bilateral medial temporal lobe and left-sided inferotemporo-occipital infarction could not associate colors with objects but could name colors. The disorder is interpreted as a deficit in the semantic classification of objects rather than colors. The responsible lesion seems to lie in the inferotemporal cortex.

This study was supported by a grant from the Swiss National Science Foundation to Dr Schneider.

References

1. Livingstone M, Hubel D. Psychophysical evidence for separate channels for the perception of form, color, movement, and depth. *J Neurosci*. 1987;7:3416-3468.
2. Zeki S. A century of achromatopsia. *Brain*. 1990;113:1721-1777.
3. Damasio AR, Yamada T, Damasio H, Corbett J, McKee J. Central achromatopsia: behavioral, anatomic, and physiologic aspects. *Neurology*. 1989;30:1964-1971.
4. Pötzl O. *Die optisch-agnostischen Störungen (Die verschiedenen For-*

- men der Seelenblindheit). Leipzig, Germany: Deuticke; 1928.
5. Geschwind N, Fusillo M. Color naming defects in association with alexia. *Arch Neurol*. 1966;15:137-146.
 6. Hécaen H, Albert ML. *Human Neuropsychology*. New York, NY: John Wiley & Sons Inc; 1978.
 7. Kinsbourne M, Warrington EK. Observations on colour agnosia. *J Neurol Neurosurg Psychiatry*. 1964;27:296-299.
 8. Grüsser OJ, Landis T. Visual agnosias and other disturbances of visual perception and cognition. In: Cronly-Dillon J, ed. *Vision and Visual Dysfunction*. New York, NY: Macmillan Publishing Co Inc; 1991; vol 12.
 9. De Renzi E, Spinnler H. Impaired performance on color tasks in patients with hemispheric damage. *Cortex*. 1967;3:194-217.
 10. De Renzi E, Faglioni P, Scotti G, Spinnler H. Impairment in associating colour to form, concomitant with aphasia. *Brain*. 1972;95:293-304.
 11. Lewandowsky M. Ueber Abspaltung des Farbensinnes. *Monatsschr Psychiatr Neurol*. 1908;23:488-510.
 12. Sittig O. Störungen im Verhalten gegenüber Farben bei Aphasischen. *Monatsschr Psychiatr Neurol*. 1921;49:63-88, 159-187.
 13. Varney NR. Colour association and 'colour amnesia' in aphasia. *J Neurol Neurosurg Psychiatry*. 1982;45:248-252.
 14. Lhermitte F, Chain F, Aron D, Leblanc M, Souty O. Les troubles de la vision des couleurs dans les lésions postérieures du cerveau. *Rev Neurol*. 1969;121:5-29.
 15. Rey A. *L'Examen Clinique en Psychologie*. Paris, France: Presses Universitaires de France; 1964.
 16. Rey A. L'examen psychologique dans les cas d'encephalopathie traumatique. *Arch Psychol*. 1941;112:286-340.
 17. Farnsworth D. Farnsworth-Munsell 100-hue and dichotomous test for color vision. *J Optic Soc Am*. 1943;33:568-578.
 18. Engerth G. Über isolierte Störungen in der Verwendung der blauen Farbe bei parietalen Herderkrankungen. *Z Neurol Psychiatr*. 1934;149:723-736.
 19. Damasio AR, McKee J, Damasio H. Determinants of performance in color anomia. *Brain Lang*. 1979;7:74-85.
 20. Cohen R, Kelter S. Cognitive impairment of aphasics in a colour-to-picture matching task. *Cortex*. 1979;15:235-245.
 21. Beauvois MF, Saillant B. Optic aphasia for colours and colour agnosia: a distinction between visual and visuo-verbal impairments in the processing of colours. *Cogn Neuropsychol*. 1985;2:1-48.
 22. De Vreese LP. Two systems for colour-naming defects: verbal disconnection vs colour imagery disorder. *Neuropsychologia*. 1991;29:1-18.
 23. Tulving E. Episodic and semantic memory. In: Tulving E, Donaldson W, eds. *Organization of Memory*. Orlando, Fla: Academic Press Inc; 1972:381-403.
 24. Warrington EK, McCarthy RA. Disorders of memory. In: Asbury AK, McKhann GM, McDonald WI, eds. *Diseases of the Nervous System*. London, England: Heinemann Medical Books Ltd; 1986;2:828-838.
 25. Scoville WB, Milner B. Loss of recent memory after bilateral hippocampal lesions. *J Neurol Neurosurg Psychiatry*. 1957;20:11-21.
 26. Milner B, Corkin S, Teuber HL. Further analysis of the hippocampal amnesic syndrome: 14-year follow-up study of HM. *Neuropsychologia*. 1968;6:215-234.
 27. Cirillo RA, George PJ, Horel JA, Martin-Elkins C. An experimental test of the theory that visual information is stored in the inferotemporal cortex. *Behav Brain Res*. 1989;34:43-53.
 28. Dean P. Visual behavior in monkeys with inferotemporal lesions. In: Ingle DJ, Goodale MA, Mansfield RJW, eds. *Analysis of Visual Behavior*. Cambridge, Mass: MIT Press; 1982:587-628.
 29. Damasio AR. Synchronous activation in multiple cortical regions: a mechanism for recall. *Semin Neurosci*. 1990;2:287-296.
 30. Damasio AR, Damasio H. Anatomical basis of pure alexia. *Neurology*. 1983;33:1573-1583.
 31. Mohr JP, Leicester J, Stoddard LT, Sidman M. Right hemianopia with memory and color deficits in circumscribed left posterior cerebral artery territory infarction. *Neurology*. 1971;21:1104-1113.