

Successful Treatment with Succinate in a Patient with MELAS

Hiroaki OGURO, Kenichi IJIMA, Kazuo TAKAHASHI, Atsushi NAGAI, Hirokazu BOKURA,
Shuhei YAMAGUCHI and Shotai KOBAYASHI

Abstract

We present a case report of a 27-year-old man with MELAS, who presented with general convulsions and left flaccid hemiparesis. Anticonvulsant drugs failed to achieve complete control of his convulsions. A good response to oral administration of succinate has been maintained for more than 30 months, with no recurrence of any stroke-like episode. Succinate therapy may have potential for treatment of uncontrolled convulsive MELAS patients.

(Internal Medicine 43: 427–431, 2004)

Key words: MELAS, succinate, therapy

Introduction

MELAS (mitochondrial myopathy, encephalopathy, lactic acidosis and stroke-like episodes) is characterized by mitochondrial dysfunctions in multiple organs, resulting in generalized convulsions and recurrent stroke-like manifestations (1). These symptoms are often intractable. Several effective drug therapies have been reported for the treatment of mitochondrial encephalopathy. They include coenzyme Q, cytochrome c, nicotinamide, dichloroacetate (2) and succinate (3, 4). These therapeutic drugs, which are mitochondrial respiratory chain enzymes or their substrates, are thought to compensate for defects in the corresponding pathways (5). Recently, trials of several new therapeutic drugs have been reported. Among them, idebenone is a synthetic analogue of coenzyme Q (6). L-arginine is a potent donor of nitric oxide, reducing ischemic damage in brain ischemia (7). Creatine enhances adenosine triphosphatase synthesis and serves as an activator of glycolysis (8). Taurine, which is absent in mutant mt tRNA of MELAS, can

be imported into mitochondria through a taurine transporter (9). However, the long-term prognosis with these treatments remains unknown. Here, we report a patient with MELAS, in whom two-year administration of succinate at 6 g/day effectively prevented relapse of the cardinal neurological symptoms.

Case Report

A 27-year-old man was diagnosed with secondary generalized seizure and diabetes mellitus at the age of 18. Insulin therapy was started two years later. At the age of 24, an A3243G mutation in mitochondrial (mt) tRNA-Leu (UUR) 3243 allele 1 and wild-type in mt tRNA-Leu (UUR) 3243 allele 2 or 3271 allele 1 were identified from peripheral whole blood cells (by Athena Diagnostics Co. Mass.), which indicated the diagnosis of MELAS. At the age of 26, he was hospitalized with diabetic ketoacidosis and stroke-like episodes (convulsion of the right side of the body, loss of consciousness and aphasia). He recovered after administration of ATP, cytochrome c and coenzyme Q, and was continuously treated with sodium valproate. Sensorineural hearing loss was also found by audiometry in May 2000. Because of the detrimental effects of valproate on oxidative phosphorylation, sodium valproate was changed to phenytoin in August 2000 (10).

At the age of 27, he was admitted to our hospital because of stroke-like episodes with myoclonus and drop attack of the left upper limb in November 2000. These episodes progressed to general convulsions followed by left flaccid hemiparesis in December 2000. Electro-encephalography (EEG) showed a 2 Hz multiple spike and wave complex during general convulsions (Fig. 1A). Furthermore, his consciousness state was lethargic due to diabetic ketoacidosis. The concentration of lactate in CSF was elevated to 46.2 mg/dl, and pyruvate concentration was also increased to 1.66 mg/dl with a high lactate/pyruvate ratio (range 19 to 25) (11). Diffusion-weighted head MRI demonstrated a high sig-

From the Shimane University School of Medicine, Izumo

Received for publication August 27, 2003; Accepted for publication December 16, 2003

Reprint requests should be addressed to Dr. Hiroaki Oguro, the Third Department of Internal Medicine, Shimane University School of Medicine, 89-1 Enya-cho, Izumo, Shimane 693-8501

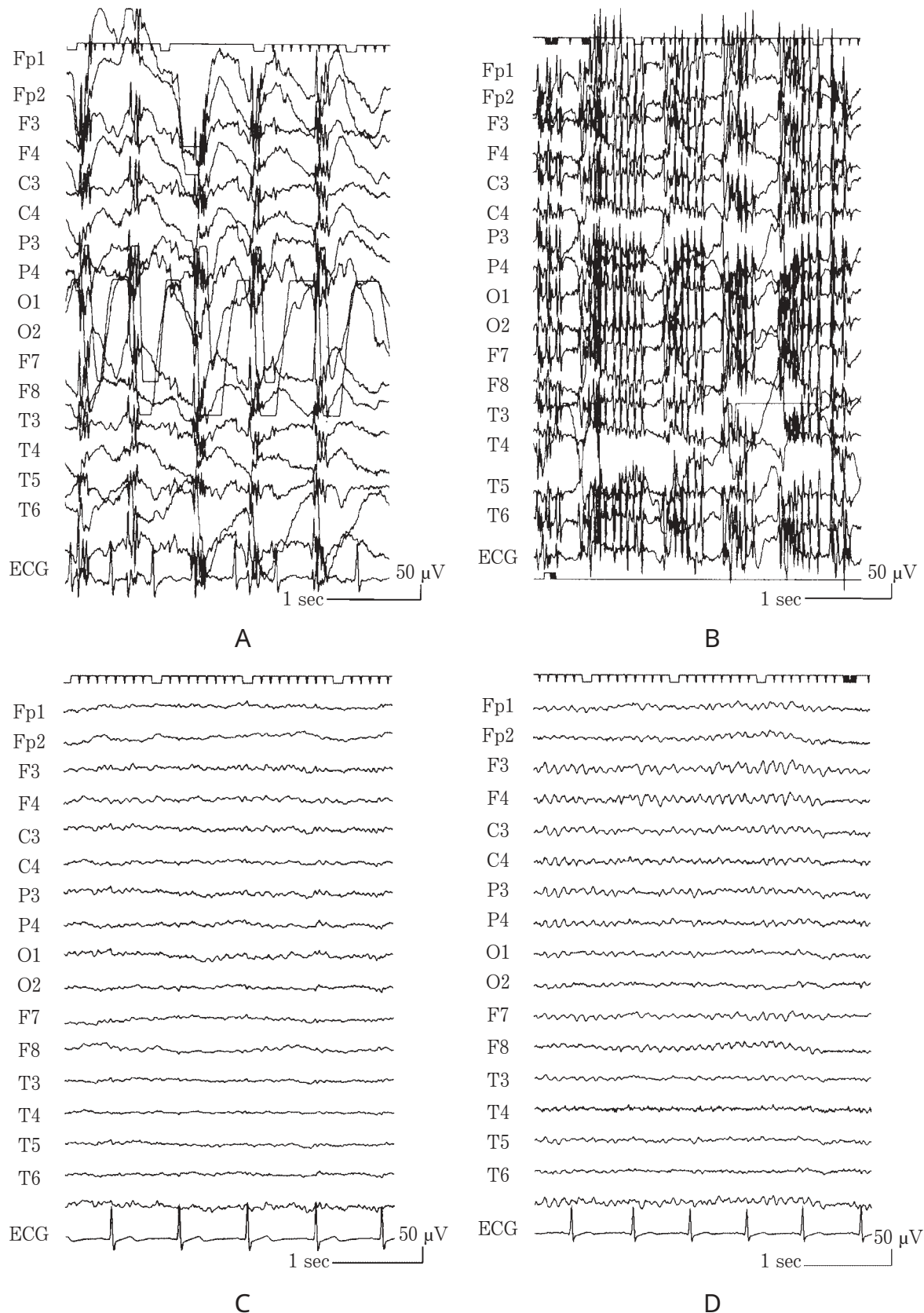


Figure 1. A) 2 Hz multiple spike and wave complex seen on EEG during general convulsions in December 2000. B) Poly-spikes seen on EEG during intermittent myoclonic seizures in February 2001. C) A normal pattern without any spike or sharp wave seen on EEG in February 2002. D) A normal pattern seen on EEG in June 2003.

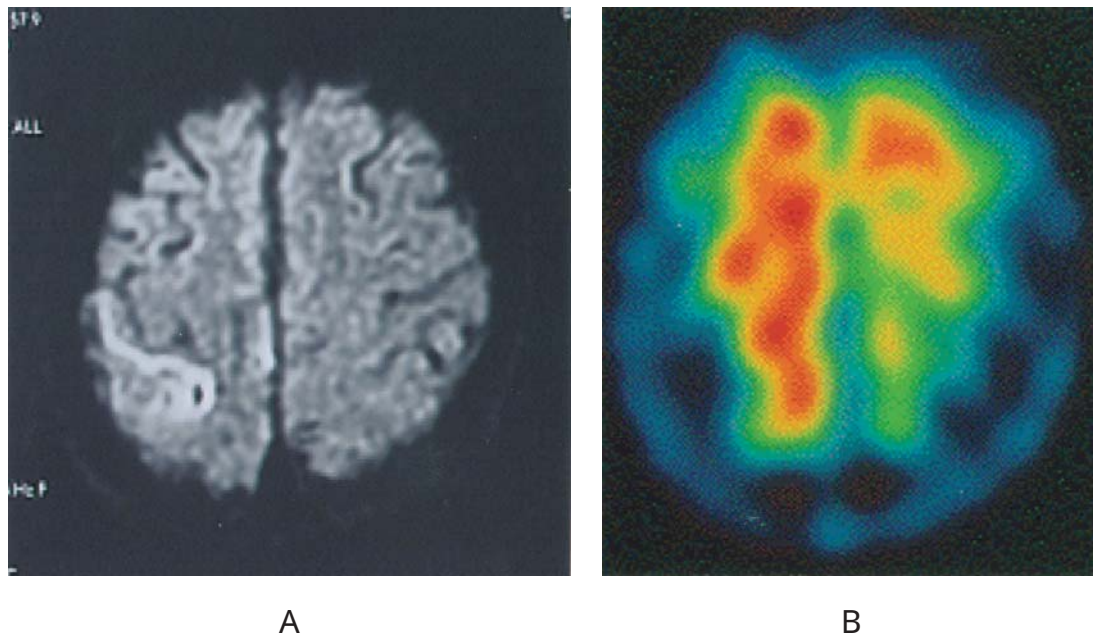


Figure 2. A) MR diffusion-weighted image showing an epileptogenic focus at the post central gyrus on admission in November 2000. B) Tc-99m HMPAO brain SPECT in January 2001.

nal intensity region at the post central gyrus (Fig. 2A) and fluid attenuated inversion recovery (FLAIR) images showed multifocal cortical hyperintensities located bilaterally in the temporo-occipital lobes (Fig. 3A). Tc-99m HMPAO brain SPECT showed increased blood flow in the right frontoparietal lesion (Fig. 2B). Muscle biopsy of the quadriceps femoris revealed a deficiency of cytochrome c oxidase in muscle fibers (Fig. 4A) and strongly SDH-reactive blood vessels (SSV) (Fig. 4B), but ragged-red fibers (RRF) were not detected (Fig. 4C). Aggregates of enlarged mitochondria or paracrystalline inclusion bodies characteristically detected in RRF were not found by electron microscopy. The point mutation of A3243G in mt DNA was also recognized in the muscle sample.

Anticonvulsant drugs (clonazepam and zonisamide) were partially effective, but failed to give complete control of convulsions. Poly-spikes were seen on EEG during intermittent myoclonic seizures in February 2001 (Fig. 1B). Then, we started oral administration of succinate at 6 g per day. After one week his consciousness level improved and abnormal neurological signs, including myoclonus and hemiparesis, disappeared. The same amount of succinate and the anticonvulsants were continued for 30 months, during which he showed no neurological abnormalities.

Although the concentrations of lactate and pyruvate in CSF were still high (61.4 mg/dl and 2.12 mg/dl, respectively), EEG showed a normal pattern without any spike or sharp wave in February 2002 (Fig. 1C) and June 2003 (Fig. 1D). Follow-up MRI demonstrated a mixture of remissive and recurrent foci, and similar findings were seen in February 2002 (Fig. 3B) and June 2003 (Fig. 3C). Diabetes

mellitus was also well controlled. After succinate therapy the Hasegawa Dementia Rating Scale was improved from 21 points to 26 points. The mean hearing thresholds measured by audiometry slightly worsened from 65.0 dB (rt) and 63.8 dB (lt) in May 2000, to 72.5 dB (rt) and 80.0 dB (lt) in May 2002. He showed a progression to deafness and needed an audiphone in spite of succinate treatment. We advised him to avoid the stresses of strong sunlight, sea bathing and alcohol intake for two years (12). We used pure succinate free of sodium, because sodium succinate can cause hypernatremia, and his serum sodium levels remained in the normal range with no adverse effect for two years.

Discussion

To obtain good efficacy in the treatment of mitochondrial encephalopathy, drugs need to be delivered to the mitochondrial matrix through cell membranes. Succinate has a low molecular weight of 162.06 and is small enough to be transported into the mitochondrial matrix. There are distinct electron transport systems in the mitochondria, i.e., complexes I and II. Complex I receives electrons from NADH originating from α -ketoglutarate, pyruvate and fatty acids, whereas complex II receives electrons directly from succinate in the TCA cycle. These two systems cooperatively create an electrochemical gradient that is used for the production of ATP. MELAS is a mitochondrial disorder due to a deficiency of the subunits of complex I (3). Thus, despite the defect in complex I, the respiratory capacity in a MELAS patient can be restored by succinate administration, through activation of the complex II system. It has been reported that

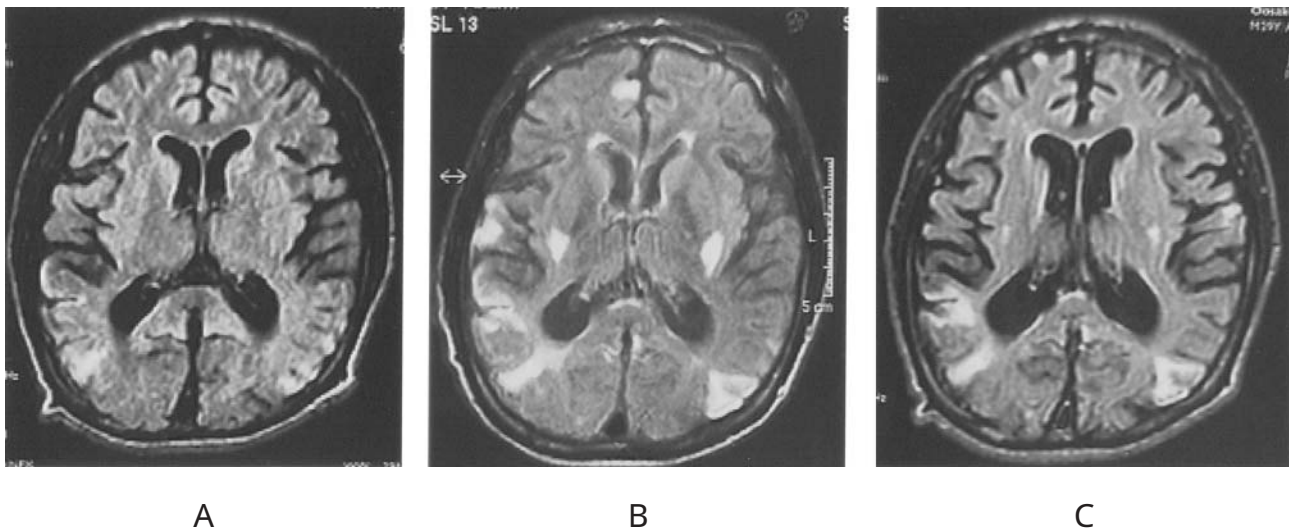


Figure 3. MR FLAIR image shows a mixture of remissive and recurrent foci. A) January 2001, B) February 2002, C) June 2003.

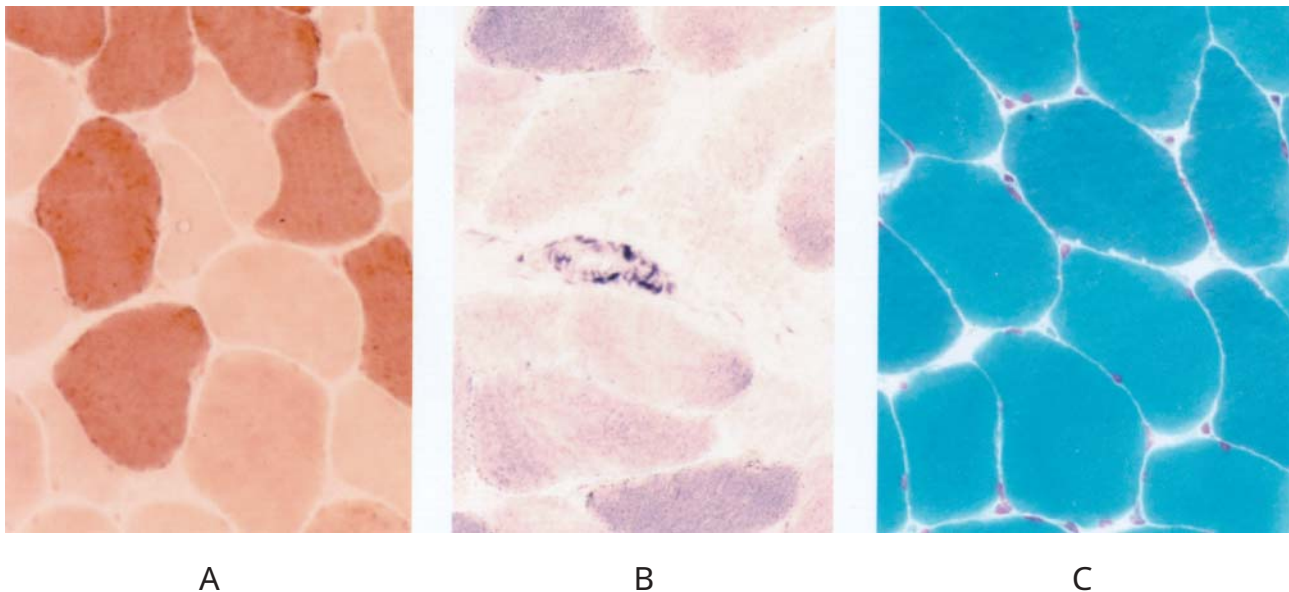


Figure 4. Muscle biopsy specimens (M. quadriceps femoris) $\times 400$. A) Cytochrome c oxidase (CCO) stain: Several fibers show loss of activity. B) SDH stain: Strongly SDH-reactive blood vessel (SSV) can be seen. C) Gomori trichrome stain: No ragged-red fibers are seen.

succinate increases electron flow from complex II to complex III (CoQ-cytochrome c reductase) and complex IV (cytochrome c oxidase), enabling these two energy coupling sites to operate normally (3).

A MELAS patient treated with L-arginine showed significant improvements in lactate and pyruvate levels, and symptoms of headache, nausea and clinical disability were dramatically improved (7). In contrast, lactate and pyruvate concentrations in CSF remained high even following the succinate therapy in the present case. One out of two reported cases successfully treated with succinate also showed

sustained elevation of pyruvate and lactate concentrations in CSF (3, 4). The concentrations of these compounds were not correlated with neurological symptoms, and may not be useful indexes of the effectiveness of succinate therapy.

The present patient showed positive SSV but no RRF in a muscle biopsy specimen. The intensity of histochemical staining with SDH more specifically reflects the number and activity of mitochondria, as compared with other stains (13). Two MELAS cases with positive SSV and without RRF were described in previous reports (13, 14), and they showed no apparent muscle symptoms. The present case also showed

no muscle symptom. Absence of RRF in muscle biopsy does not exclude mitochondrial disease (13–15). The diagnosis of MELAS in this case was confirmed by the SDH staining of muscle.

In the present patient also, the neuroimaging findings were not characteristic. FLAIR images showed increased signal intensities bilaterally in the temporo-occipital lobes (Fig. 2B, C). The major pattern of neuroimaging changes in MELAS is reported to be migrating infarct lesions and progressive focal and generalized atrophy in follow-up MRI study, and during the course of the illness, new lesions progressively appear in other cerebral regions regardless of improving clinical signs (16). Our patient showed migrating lesions, but no atrophic changes. Consequently the correlation between symptoms and imaging findings is unclear.

More than 60 percent of MELAS patients have bilateral progressive sensorineural hearing loss (17), as seen in our patient. Longitudinal audiometry tests did not show any improvement due to succinate therapy, and this is consistent with a previous report showing no correlation between degrees of hearing loss and severity of neurological symptoms in MELAS patients (18). Succinate therapy might not completely prevent the progressive symptoms of MELAS.

This is the first report of successful long-term treatment of intractable neurological symptoms in a MELAS patient by administration of succinate. A large-scale clinical trial of succinate treatment for long-term control of MELAS syndrome would seem to be warranted.

Acknowledgements: The authors thank Dr. Ikuya Nonaka and his group at the National Center of Neurology and Psychiatry for muscle biopsy diagnosis.

References

- 1) Pavlakis SG, Phillips PC, DiMauro S, De Vivo DC, Rowland LP. Mitochondrial myopathy, encephalopathy, lactic acidosis and stroke-like episodes: a distinctive clinical syndrome. *Ann Neurol* **16**: 481–488, 1984.
- 2) Saitoh S, Momoi MY, Yamagata T, Mori Y, Imai M. Effects of dichloroacetate in three patients with MELAS. *Neurology* **50**: 531–534, 1998.
- 3) Ichiki T, Tanaka M, Nishikimi M, et al. Deficiency of subunits of complex I and mitochondrial encephalomyopathy. *Ann Neurol* **23**: 287–294, 1988.
- 4) Suzuki Y, Kato I, Mizutani F, et al. A case of mitochondrial encephalomyopathy (MELAS) successfully treated by sodium succinate. A case with a decrease in subunits of complex I. *Jpn J Pediatr Soc* **93**: 2798–2803, 1989 (in Japanese, Abstract in English).
- 5) Morgan-Hughes JA, Darveniza P, Landon DN, Land JM, Clark JB. A mitochondrial myopathy with a deficiency of respiratory chain NADH-CoQ reductase activity. *J Neurol Sci* **43**: 27–46, 1979.
- 6) Napolitano A, Salvetti S, Vista M, Lombardi V, Siciliano G, Giraldi C. Long-term treatment with idebenone and riboflavin in a patient with MELAS. *Neurol Sci* **21**: S981–S982, 2000.
- 7) Koga Y, Ishibashi M, Ueki I, et al. Effects of L-arginine on the acute phase of strokes in three patients with MELAS. *Neurology* **58**: 827–828, 2002.
- 8) Barisic N, Bernert G, Ipsiroglu O, et al. Effects of oral creatine supplementation in a patient with MELAS phenotype and associated nephropathy. *Neuropediatrics* **33**: 157–161, 2002.
- 9) Suzuki T, Suzuki T, Wada T, Saigo K, Watanabe K. Taurine as a constituent of mitochondrial tRNAs: new insights into the functions of taurine and human mitochondrial diseases. *EMBO J* **21**: 6581–6589, 2002.
- 10) Lam CW, Lau CH, Williams JC, Chan YW, Wong LJ. Mitochondrial myopathy, encephalopathy, lactic acidosis and stroke-like episodes (MELAS) triggered by valproate therapy. *Eur J Pediatr* **156**: 562–564, 1997.
- 11) Kobayashi M, Morishita H, Sugiyama N, et al. Mitochondrial myopathy, encephalopathy, lactic acidosis and stroke-like episodes syndrome and NADH-CoQ reductase deficiency. *J Inher Metab Dis* **9**: 301–304, 1986.
- 12) Shinde A, Nakano S, Taguchi Y, Kagawa D, Akiguchi I. A patient of MELAS with 3271 mutation with fatal outcome after alcohol intake. *Rinsho Shinkeigaku (Clin Neurol)* **40**: 561–565, 2000 (in Japanese, Abstract in English).
- 13) Hasegawa H, Matsuoka T, Goto Y, Nonaka I. Strongly succinate dehydrogenase-reactive blood vessels in muscles from patients with mitochondrial myopathy, encephalopathy, lactic acidosis, and stroke-like episodes. *Ann Neurol* **29**: 601–605, 1991.
- 14) Mimaki N, Hasegawa H, Nonaka I. MELAS without ragged-red fibers: a case report. *No To Hattatsu* **23**: 606–611, 1991 (in Japanese, Abstract in English).
- 15) Huang CC, Wai YY, Chu NS, et al. Mitochondrial encephalomyopathies: CT and MRI findings and correlations with clinical features. *Eur Neurol* **35**: 199–205, 1995.
- 16) Kim IO, Kim JH, Kim WS, Hwang YS, Yeon KM, Han MC. Mitochondrial myopathy-encephalopathy-lactic acidosis-and stroke-like episodes (MELAS) syndrome: CT and MR findings in seven children. *AJ R* **166**: 641–645, 1996.
- 17) Warrick PD, Wardrop P, Sim DW. Sensorineural hearing loss in MELAS syndrome. *J Laryngol Otol* **111**: 279–281, 1997.
- 18) Zwirner P, Wilichowski E. Progressive sensorineural hearing loss in children with mitochondrial encephalomyopathies. *Laryngoscope* **111**: 515–521, 2001.