

## New Syndrome

# Leukoencephalopathy, Arthritis, Colitis, and Hypogammaglobulinemia (LACH) in Two Brothers: A Novel Syndrome?

Joshua L. Bonkowsky,<sup>1</sup> John F. Bohnsack,<sup>1\*</sup> Mary J. Pennington,<sup>2</sup> David Viskochil,<sup>1</sup> and Joel A. Thompson<sup>1</sup>

<sup>1</sup>Department of Pediatrics, University of Utah School of Medicine, Salt Lake City, Utah

<sup>2</sup>Granger Pediatric Clinic, West Valley City, Utah

**We report a pair of brothers who have leukoencephalopathy, arthritis, colitis, and hypogammaglobulinemia. Both presented initially with seizures in the early postnatal period. They have significant developmental delay, and brain MRIs demonstrate leukoencephalopathy, characterized by profound hypomyelination. They have developed arthritis, which in one brother has required chronic treatment; and persistent intermittent diarrhea, necessitating treatment for inflammatory bowel disease. Finally, they have had multiple hospitalizations, including several for sepsis; an immunological analysis revealed that they have IgG1-subclass hypogammaglobulinemia and low B cell levels. There is no family history of similar problems, and these brothers have an unaffected brother. We believe this constellation of symptoms represents a novel syndrome: LACH syndrome (leukoencephalopathy, arthritis, colitis, and hypogammaglobulinemia). The etiology of this syndrome remains unknown despite extensive investigations.** © 2004 Wiley-Liss, Inc.

**KEY WORDS:** leukoencephalopathy; inflammatory bowel disease; colitis; arthritis; hypogammaglobulinemia; LACH syndrome

## INTRODUCTION

Leukoencephalopathies are a heterogeneous group of disorders with lesions in the white matter (myelinated axons) of the central nervous system (CNS) [reviewed in Kaye, 2001]. Leukoencephalopathies vary in their age of onset, rapidity of progression, and severity of symptoms. Some leukoencephalopathies have pathology confined to the CNS, while others affect multiple organ systems. The underlying molecular basis has been discovered in a few types of leukoencephalopathy, but the

pathogenesis of most leukoencephalopathies are not known. Insight into the causes of leukoencephalopathy has led to improved diagnosis, treatments, and a better understanding of normal myelin and nervous system development.

We describe two male siblings (brothers) who have leukoencephalopathy and share a unique constellation of symptoms. Specifically, both brothers have leukoencephalopathy, arthritis, inflammatory bowel disease (colitis), and hypogammaglobulinemia. The time-course of their disease has been similar, although one brother has been more severely affected. Their parents are not affected and are not consanguineous. A brother (the middle sibling) is also unaffected. Their grouping of symptoms is unique and is not shared with other described leukoencephalopathies. We believe this represents a novel syndrome which we have termed LACH syndrome: leukoencephalopathy, arthritis, colitis, and hypogammaglobulinemia.

## CLINICAL REPORTS

### Patient 1

**Clinical course.** Patient 1 was born at 41 weeks after an uncomplicated pregnancy to a G1P1 mother and unrelated father via normal spontaneous vaginal delivery. Birth measurements were normal (weight 3,230 g, length 49.5 cm, OFC 34 cm). He was readmitted on day of life three with generalized tonic-clonic seizures and apnea.

Family history is remarkable for a maternal grandmother with ulcerative colitis; there is no known consanguinity. The patient has two brothers: his younger brother (Patient 2) is similarly (although more severely) affected, while the middle brother does not exhibit any of the clinical or laboratory abnormalities of the two affected brothers.

His growth has been marked by a persistent failure to thrive which developed postnatally, with height, weight, and head circumference less than the 3rd (Fig. 1a). At age 6 years his weight was 15 kg, which is the 50th for weight of a 3-year old. A swallow study at age 3 years showed oral dysphagia, and for several months he received nasogastric feeds. He has had intermittent severe diarrhea, treated with sulfasalazine and oral prednisone. Morphological (height, weight, OFC, palm length, hand length, intercanthal distance) measurements performed at age 3 years were remarkable only for the aforementioned growth failure.

Developmental milestones have been delayed. At age 5 years, he is able to feed himself, but uses a spoon or cup poorly. He can pull himself to stand and can crawl, but has difficulty maintaining a sitting position. He has a vocabulary of approximately 50 words and a pleasant demeanor. The development delay has not improved despite resolution of his diarrhea.

The child's neurologic course has been marked by a seizure disorder, which is worsened by intercurrent illnesses. His initial presentation and on-going seizures have required carbamazepine and phenobarbital for control. He has had four

Grant sponsor: University of Utah Clinical Genetics Research Program; Grant sponsor: Primary Children's Medical Center Foundation; Grant sponsor: National Center for Research Resources (GCRC grant); Grant number: M01-RR00064.

\*Correspondence to: John F. Bohnsack, Division of Pediatric Rheumatology and Immunology, Department of Pediatrics, University of Utah Health Sciences Center, 50 North Medical Drive, Salt Lake City, UT 84132. E-mail: john.bohnsack@hsc.utah.edu

Received 10 April 2003; Accepted 22 October 2003

DOI 10.1002/ajmg.a.30006

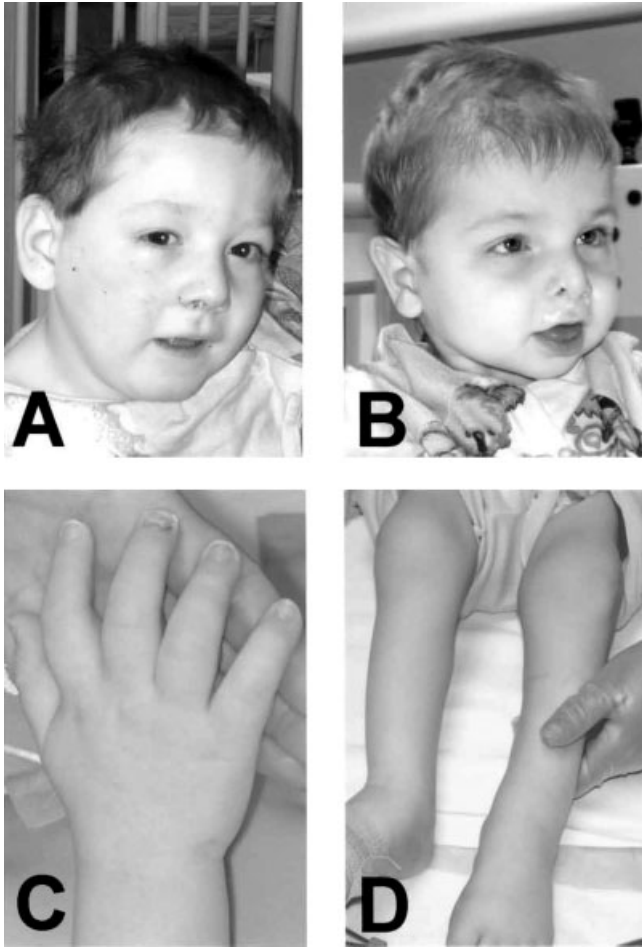


Fig. 1. Photographs. A: Photograph of Patient 1 (age 6 years). B: Photograph of Patient 2 (age 3 years). C: Swelling of Patient 2's wrist, metacarpophalangeal joints, and proximal interphalangeal joints. D: Swelling of Patient 2's knees (more pronounced in his left knee).

episodes of seizures associated with illnesses, including one episode of status epilepticus at age 4 years. His neurologic exam is remarkable for spastic quadriplegia. His vision is 20/100 bilaterally with horizontal nystagmus, and he has normal fundi.

Arthritis of Patient 1 has been limited to a single episode involving his left wrist. He has had four episodes of a diffuse erythematous maculopapular rash on his extremities and trunk. The patient has been hospitalized on multiple occasions: on day of life three, for seizures and apnea; for status epilepticus on two occasions; for diarrhea and dehydration on four separate occasions; for respiratory distress and pneumonia following an aspiration event; and for *Streptococcus pneumoniae* pneumonia and bacteremia requiring ventilator support. He has had more than 15 episodes of otitis media (despite having bilateral myringotomy tubes placed); two episodes of sinusitis; community-acquired pneumonia once; and cellulitis of his right lower leg. He has had several episodes of facial herpes simplex virus, requiring treatment with acyclovir. The patient has been treated for *Clostridium difficile* once. Central intravenous access (PortACath) was placed at the age of 5 years.

At age 5 years, Patient 1 was started on intravenous immunoglobulin (IVIG) every third week (after his hospitalization for *Strep. pneumoniae* bacteremia and pneumonia) for

his hypogammaglobulinemia. Since then, the patient has not had any episodes of pneumonia or sepsis.

### Patient 2

**Clinical course.** Patient 2 was born by normal spontaneous vaginal delivery at 38 weeks to his G3P3 mother after an uneventful pregnancy with no reported drug or toxin exposures. Apgars were 8 at 1 min and 9 at 5 min; birth weight was 3,470 g, length 47 cm, and OFC 33 cm. On day of life two, he developed generalized tonic-clonic seizures and apnea.

Patient 2 has had persistent postnatal failure to thrive, with weight, height, and OFC more than 2 standard deviations (SD) less than the mean (Fig. 1b). At age 3 years, his weight is 10 kg, which is the 50th for a 1-year old. Morphologic (height, weight, OFC, palm length, hand length, intercanthal distance, ear length) measurements performed at age 8 months were remarkable for the aforementioned growth failure, as well as bilateral increased palpebral fissure length (2.7 cm). A cardiac ultrasound was normal. Because of uncoordinated swallowing and concern for potential aspiration, he was started on nasojejunals feeds, and a Nissen fundoplication was performed at 1 year of age. The patient had a gastrostomy tube placed at 16 months of age, which provides his major source of enteral nutrition.

Neurologic exam is significant for diffuse hypotonia which is slowly evolving into spasticity. His ophthalmologic exam is significant for fine amplitude horizontal and rotary nystagmus; he has normal fundi, can fix and follow objects, and is mildly hyperopic. He is now able (at age 3 years) to crawl, roll, as well as sit briefly on his own. The patient was started on phenobarbital and carbamazepine at birth, and still requires phenobarbital for seizure prophylaxis.

Endoscopy performed at age 7 months to evaluate the cause of his poor growth and chronic diarrhea revealed partial stenosis of the proximal and descending colon and areas of patchy inflammation. He had a rectal biopsy performed which revealed normal innervation with ganglion cells. During several of his hospitalizations, the patient required TPN to insure adequate nutrition, because of copious stool output (>30 g/kg/day) while receiving enteral feeds. He had a PortaCath placed at age 21 months. Infliximab, sulfasalazine, and azathioprine have been used in an effort to control his diarrhea.

Since he was 16 months old, the patient has had arthritis of his hips, knees, elbows, wrists, and finger joints (Fig. 1c–d). The arthritis has been treated with prednisone, weekly methotrexate, and monthly infusions of infliximab (started originally to treat his colitis—10 mg/kg/dose). At age 18 months, the patient developed a rash involving his trunk, scalp, axillae, and the glans of the penis. Evaluation and punch biopsy by a pediatric dermatologist led to the diagnosis of psoriaform dermatitis, which has been treated with topical triamcinolone.

The patient has had multiple infections requiring hospitalization. He has been hospitalized three times for pneumonia, and required intubation for mechanical ventilation twice; hospitalized with bacteremia and fevers three times—twice caused by *Streptococcus pneumoniae* and the other time by *Streptococcus viridans*; and had four admissions for vomiting, diarrhea, and dehydration. Since starting IVIG and trimethoprim-sulfamethoxazole (at age 22 months), the frequency and severity of the patient's hospitalizations has decreased. He has had more than eight episodes of otitis media. He has been treated for *C. difficile* colitis three times.

### Diagnostic Testing (Patient 1 and 2)

Both brothers have had extensive evaluation of their leukoencephalopathy and associated clinical features. Complete results are summarized in Table I.

TABLE I. Results of Diagnostic Testing Performed in the Brothers

Mitochondrial disorders	Endocrine
Carnitine deficiency (1)	TSH (2)
CSF lactate (1,2)	Infectious
Serum lactate (2)	CSF culture
Immunologic	CSF HSV PCR
IgA levels(1,2)	CSF CMV PCR
CH50 (1,2)	Metabolic
HLA B-27 genotype (2)	Serum biotinidase (2)
ANCA titers (2)	Serum Ammonia (1,2)
T-cell subset profile (1)	Urine organic acids (2)
ANA titer (1)	Serum amino acids (2)
Lysosomal storage diseases	Urine amino acids (2)
GM1 gangliosidosis (1,2)	Serum copper (1)
b-Mannosidase deficiency (1,2)	Systemic
Tay-Sachs disease (1,2)	Sweat chloride (2)
Metachromatic leukodystrophy (1,2)	CF gene mutation analysis (2)
Krabbe disease (1,2)	Alpha-1-antitrypsin (2)
Sandhoff disease (1)	Karyotype with high-resolution banding (1,2)
Niemann-Pick disease, types A and B (2)	Myelin protein defects
Gaucher disease (2)	Pelizaeus-Merzbacher gene: FISH; quantitative PCR; sequencing (2)
GI disorders	Peroxisomal disorders
Duodenal enzyme levels (disaccharidase, lactase, maltase, palatinase, sucrase) (2)	Very long-chain fatty acids (1)
Stool reducing substances (1,2)	CSF neurotransmitters
Quantitative fecal fat (1,2)	Glycine (1)
Stool WBC (1,2)	Glutamate (1)
Stool pH (1,2)	Glutamine (1)
Fecal elastase (1,2)	Tetrahydrobiopterin (2)
Glycosylation disorders	Neopterin (2)
Transferrin isoelectric focusing (2)	5-Methyltetrahydrofolate (2)
	3- <i>o</i> -Methyldopa (2)
	Homovanillic acid (2)
	5-Hydroxyindoleacetic acid (2)

Parentheses with numbers 1 and/or 2 indicate which brother was tested (e.g., Tay-Sachs (1, 2) indicates that both brothers were screened for Tay-Sachs disease). Results were normal or in the normal range for all tests.

Brain MRI was undertaken to search for causes of the patients' seizures and developmental delay. At age 10 months, Patient 1 was found to have a "thin" or atrophic corpus callosum (Fig. 2a), and hypomyelination of the brain stem. A subsequent MRI (at age 3 years) showed patchy hyperintensity in the brain stem on T2-weighted images, as well as in the subcortical white matter, basal ganglia, and cerebellum, consistent with hypomyelination (Fig. 2b). Ventricles and extra-axial fluid spaces were enlarged with prominent sulci and apparent volume loss of the cerebral hemispheres. Diffusion-weighted imaging was unremarkable. In Patient 2, an initial MRI obtained on day of life five was normal (with the exception of questionable decreased myelination of the internal capsule). However, imaging obtained at age seven months demonstrated a thin corpus callosum (Fig. 2c), with increased extra-axial fluid volumes and prominent sulci, and generalized hypomyelination, especially noticeable in the cerebrum and basal ganglia structures (Fig. 2d).

Electroencephalography was normal in both patients, and an electromyograph performed in Patient 1 was normal.

Analysis for known causes of leukoencephalopathy was performed, including leukocyte lysosomal enzyme analysis, for GM1 gangliosidosis,  $\beta$ -mannosidosis, Tay-Sachs disease, metachromatic leukodystrophy, Krabbe disease, Gaucher disease, Niemann-Pick disease types A and B, and Sandhoff disease were normal. Pelizaeus-Merzbacher disease was excluded after studies of the proteolipid protein gene including FISH, quantitative PCR to detect duplications, and sequencing of the coding region (including exon-intron boundaries) were all normal. Transferrin isoelectric focusing to examine for congenital disorders of glycosylation was also normal.

CSF was examined for evidence of disorders of neurotransmitter metabolism. CSF levels of lactate, glycine, glutamine, glutamate, tetrahydrobiopterin, neopterin, 5-methyltetrahydrofolate, 3-*o*-methyldopa, homovanillic acid, and 5-hydroxyindoleacetic acid were all normal.

Studies to detect inborn errors of metabolism included plasma ammonia, lactate, copper, carnitine (free, total, and esterified), very-long chain fatty acids, serum biotinidase activity, TSH, and urine organic acids, all of which were normal.

Chromosomal karyotype with high-resolution banding, 550 bands, was normal (46,XY) in both patients.

Both patients have had arthritis but it has been much more severe in Patient 2. ESR of Patient 1 has risen to 38 mm/hr, and his CRP up to 1.7 mg/dl; no anti-nuclear antibody (ANA) IgG was detected. ESR of Patient 2 has risen to 150 mm/hr, and his CRP to 31.5 mg/dl. His HLA-B27 genotype was negative.

Multiple tests were done to evaluate the cause of their diarrhea. Stool analysis for pH, WBC, qualitative fecal fat levels, fecal elastase levels, reducing substances, and alpha-1-antitrypsin levels were normal. Sweat chloride testing and gene mutation analysis for cystic fibrosis were normal. Duodenal enzyme levels (disaccharidase, lactase, maltase, palatinase, sucrase) were all normal. Levels of cholesterol, bilirubin, AST, and ALT were normal.

The diarrhea has been associated with malabsorption, with low levels of serum albumin, zinc, and iron. Patient 1 had required two red blood cell transfusions for severe anemia due to his iron deficiency. Endoscopy in Patient 1 was grossly normal but biopsy results revealed chronic gastritis, a friable duodenum, and frequent apoptotic cells in the crypts of the

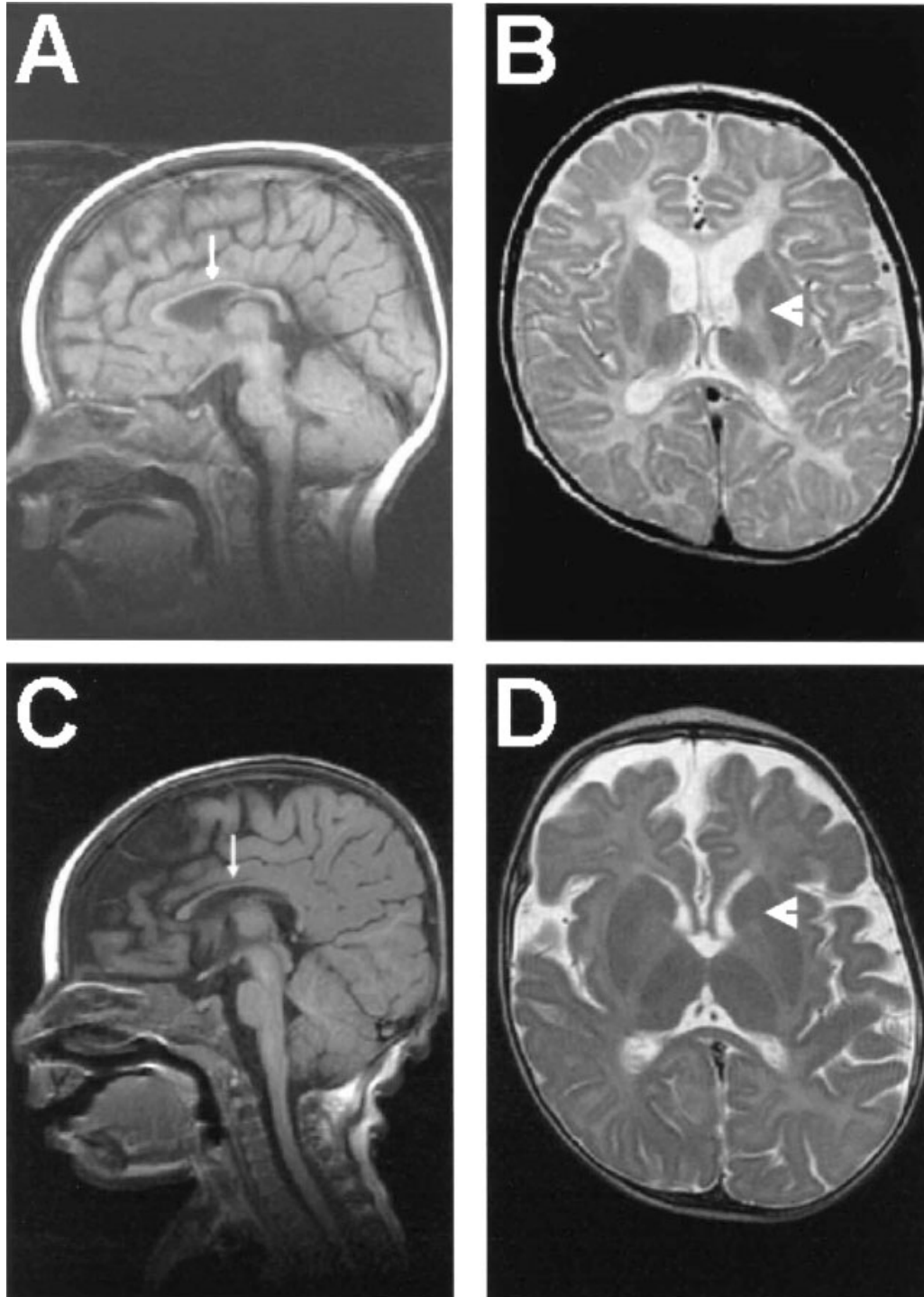


Fig. 2. Brain MRI images. **A, B:** Patient 1. **C, D:** Patient 2. **A:** Sagittal T1-weighted image (age 10 months) shows thin corpus callosum (arrow). **B:** Axial T2-weighted image at the level of the basal ganglia (age 3 years) shows hypomyelinated internal capsule (arrowhead). **C:** Sagittal T1-weighted image (age 7 months) demonstrates thin corpus callosum (arrow). **D:** Axial T2-weighted image at the level of the basal ganglia (age 7 months) shows undermyelinated internal capsule (arrowhead).

ileum and colon. Biopsy showed chronic inflammation of the colon, with extensive crypt dropout, loss of surface epithelium, focal acute cryptitis, and crypt necrosis in Patient 2.

Testing for immunodeficiency or immune dysregulation was performed in the patients because of their arthritis, colitis, hospitalizations, and recurrent neutropenia. Comple-

ment levels (CH50), T cell subset profile analysis, anti-neutrophil cytoplasmic antibody (ANCA) titers, and IgA levels were normal.

B cell counts were low in both Patients 1 and 2 (absolute CD19+/CD3- cell count was 35/ $\mu$ l and 15/ $\mu$ l, respectively, normal 62–540).

Both patients had hypogammaglobulinemia. Patient 1 had low IgG (263 mg/dl, normal 608–1229) and IgM (24 mg/dl, normal 48–226) levels, with low IgG1 level (171 mg/dl, normal 330–1065), and other IgG subclass levels normal (drawn at the age of 5 years; his albumin level at this time was low at 2.8 g/dl). Patient 2 has low IgG (205 mg/dl, normal 331–1164) and IgM (18 mg/dl, normal 43–163) levels, with low IgG1 level (155 mg/dl, normal 288–880); other IgG subclass levels were normal (drawn at age 18 months; at that time his albumin level was 3 g/dl). Also, his IgE levels have been elevated (from 16–273 IU/ml, normal 0–12).

Patient 2 failed to mount adequate immune responses to the *Haemophilus influenzae* B vaccine and 23-valent pneumococcal vaccine (pre:post vaccination ratio 0), but did respond to the diphtheria and tetanus vaccinations (pre:post vaccination ratios >2 and >6, respectively). Bone marrow aspirations performed in Patient 2 at age 3 and 7 months were normal.

Both patients have had neutropenia (Patient 1 to a nadir of 0 cells/ $\mu$ l, Patient 2 to 300 cells/ $\mu$ l), which has responded to treatment with GCSF (granulocyte-colony stimulating factor).

## DISCUSSION

These brothers have a unique syndrome of leukoencephalopathy with associated findings of arthritis, colitis, and hypogammaglobulinemia. Extensive investigations have failed to uncover an underlying metabolic or genetic abnormality. Family history is otherwise unremarkable, and the mother does not have any male siblings that would help clarify whether inheritance is X-linked or recessive.

The leukoencephalopathy is characterized by a profound hypomyelination visualized by MRI. Both presented initially with seizures in the first days of life; although they have required continued seizure prophylaxis, their seizure disorder has not been progressive. In contrast, their developmental delay has been profound and persistent (but without regression). Their head circumferences were normal at birth, but since about the age of 6 months have been consistently less than the 3rd centile.

Arthritis is another shared feature of their syndrome. Patient 1 has had minimal symptoms, but his brother has needed corticosteroids and methotrexate therapy for arthritis affecting multiple large and small joints.

Both have had intermittent profuse diarrhea, and a clinical analysis is consistent with inflammatory bowel disease; steroids, sulfasalazine, and infliximab have been used for treatment with partial improvement in Patient 2. Although their diarrhea has been severe enough to intermittently cause a protein-losing enteropathy, they have exhibited only mild hypoalbuminemia, have not had ascites, and have exhibited minimal lymphopenia. Further, their hypogammaglobulinemia has been specific to the IgG class, whereas clinically significant protein-losing enteropathy results in a non-specific immunodeficiency [Stiehm, 1996]. Therefore, it is unlikely that the diarrhea alone could lead to their hypogammaglobulinemia.

Both brothers have been hospitalized multiple times, several times with sepsis. Evaluation for immunodeficiencies revealed that they have hypogammaglobulinemia, particularly of the IgG1 subclass. Treatment using IVIG has correlated with a reduction in the frequency of serious hospitalizations.

Multiple diagnostic possibilities were considered as etiologies of their syndrome (see Table I). We especially examined Pelizaeus-Merzbacher disease (PMD), an X-linked leukoencephalopathy characterized by hypomyelination, nystagmus, developmental delay, and muscle tone abnormalities [Kaye, 2001]. Further, the proteolipid protein (PLP) gene mutated in PMD is within 4,000 kb of the X-linked agammaglobulinemia

(XLA) tyrosine kinase gene (Bruton's tyrosine kinase—*BTK*). Mutations in *BTK* cause a deficiency of B cells and decreased production of immunoglobulins. Thus, an interstitial chromosome deletion or rearrangement could affect both the *PMD* and *XLA* genes and cause features of leukoencephalopathy and B-cell deficiency.

We believe it unlikely that LACH syndrome is caused by a contiguous deletion affecting the *PLP* and *BTK* genes: high-resolution karyotype analysis was normal; FISH analysis, PCR, and direct sequencing of the *PLP* gene was normal; and antibody staining for the *BTK* protein in platelets was normal. Further, patients with XLA tend to have low or absent IgA expression, and recurrent soft-tissue infections, features not found in the brothers we are reporting. Finally, arthritis and colitis are not features of PMD or XLA.

Other diagnoses we considered were mitochondrial neurogastrointestinal encephalopathy (MNGIE), an autosomal recessive disorder with gastric dysmotility, ophthalmoparesis, thin body habitus, peripheral neuropathy, and leukoencephalopathy [Nishino et al., 1999]. However, onset is usually between the second and fifth decade, with lactic acidosis and without seizures or developmental delay. HEADD syndrome is a mitochondrial disorder characterized by hypotonia, epilepsy, autism, and developmental delay [Kang et al., 2002; Filiano et al., 2002]. In contrast, the brothers do not have autism, and have more profound findings on their brain MRI. Finally, we also investigated the possibility of a carbohydrate-deficient glycoprotein syndrome (CDGS). The clinical presentation of CDGS depends on the specific molecular defect and varies widely, but can include hypotonia, seizures, developmental delay, and frequent infections [Westphal et al., 2000]. However, the normal result of the transferrin isoelectric focusing makes this diagnosis highly unlikely in our patients. Other syndromes involving immunodeficiency and CNS manifestations have been described [e.g., see Adderson et al., 2000], but the clinical characteristics and time-course are quite different from what we have observed.

In summary, we have described a novel leukoencephalopathy syndrome in a pair of brothers, LACH syndrome: leukoencephalopathy, arthritis, colitis, and hypogammaglobulinemia.

## ACKNOWLEDGMENTS

We thank the patients and their family for their extensive participation. Dr. Gary Hedlund provided critical insights and interpretation of the MRI images.

## REFERENCES

- Adderson EE, Viskochil DH, Carey JC, Shigeoka AO, Christenson JC, Bohnsack JF, Hill HR. 2000. Growth failure, intracranial calcifications, acquired pancytopenia, and unusual humoral immunodeficiency: A genetic syndrome? *Am J Med Genet* 95:17–20.
- Filiano JJ, Goldenthal MJ, Rhodes CH, Marin-Garcia J. 2002. Mitochondrial dysfunction in patients with hypotonia, epilepsy, autism, and developmental delay: HEADD syndrome. *J Child Neuro* 17:435–439.
- Kang PB, Hunter JV, Melvin JJ, Selak MA, Faerber EN, Kaye EM. 2002. Infantile leukoencephalopathy owing to mitochondrial enzyme dysfunction. *J Child Neuro* 17:421–428.
- Kaye EM. 2001. Update on genetic disorders affecting white matter. *Pediatr Neurol* 24:11–24.
- Nishino I, Spinazzola A, Hirano M. 1999. Thymidine phosphorylase gene mutations in MNGIE, a human mitochondrial disorder. *Science* 283:689–692.
- Stiehm ER. 1996. Immunodeficiency disorders. In: *immunologic disorders in infants and children*, 4th Edn. Philadelphia: W.B. Saunders.
- Westphal V, Srikrishna G, Freeze HH. 2000. Congenital disorders of glycosylation: have you encountered them? *Genet Med* 2:329–337.