

# ISOLATED CEREBRAL VARIX DEVELOPING SUDDEN DETERIORATION OF NEUROLOGICAL STATUS BECAUSE OF THROMBOSIS: A CASE REPORT

Toshiki Kondo, M.D., Yoshimasa Mori, M.D., Yoshihisa Kida, M.D.,  
Tatsuya Kobayashi, M.D., Ph.D., and Takayasu Iwakoshi, M.D.  
*Department of Neurosurgery, Komaki City Hospital, Komaki, Japan*

Kondo T, Mori Y, Kida Y, Kobayashi T, Iwakoshi T. Isolated cerebral varix developing sudden deterioration of neurological status because of thrombosis: a case report. *Surg Neurol* 2004; 62:76–79.

## KEY WORDS

*Cerebral varix, thrombosis, epilepsy, magnetic resonance imaging, angiography, computed tomography.*

Isolated cerebral varix is a rare type of vascular anomaly or acquired lesion [1–4]. Giant intracranial varices are associated mostly with vein of Galen aneurysms. In other cases they are observed with high-flow arteriovenous shunting related to arteriovenous malformation (AVM) or fistula. We present a case of an isolated varix of central vein. The patient developed status epilepticus during outpatient observation, which was because of venous congestion caused by thrombosis of varix.

## CASE REPORT

A 39-year-old woman had complained of dropping things occasionally from the left hand for about 20 years. Electroencephalogram (EEG) contained diffuse spike and wave complex bursts and isolated spikes in the central region. Computed tomography (CT) and magnetic resonance imaging (MRI) revealed a well-enhanced mass on the right cerebral cortex beside the superior sagittal sinus mimicking a convexity meningioma (Figure 1A). MR vascular image showed that the right central vein continued to the mass (Figure 1B). Right carotid arteriography demonstrated a spindle-shaped focal dilatation of

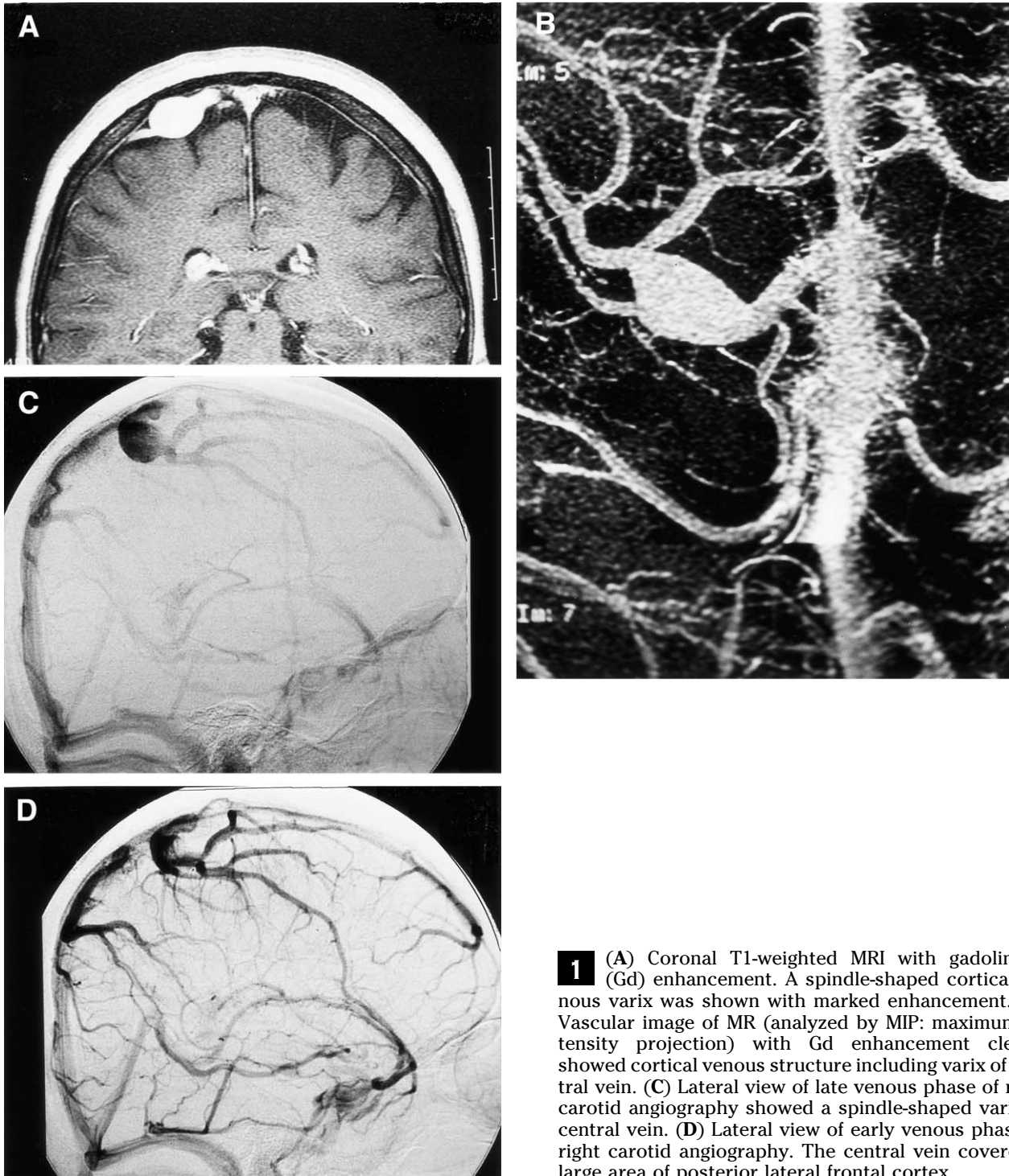
the vein (Figure 1C). No associated vascular malformation was identified. The involved central vein drained from a rather wide area of the posterior lateral frontal lobe (Figure 1D). We continued outpatient observation on this patient with prescription of anticonvulsant. She had done well for 2 months before she developed series of seizures originating from the left arm. Plain CT showed the varix as a high-density mass implying acute phase of thrombosis (Figure 2). Angiography demonstrated disappearance of varix and obstruction of the right Rolandic vein. The draining flow of the branches proximal to the obstructed Rolandic vein was delayed. It was thought that status epilepticus was because of venous congestion around the right motor cortex following thrombosis of the varix and obstruction of the stem of Rolandic vein. With conservative therapy of intramuscular administration of phenobarbital followed by oral administration of increased dose of valproate, she recovered well within a week. Follow-up MRI 6 months after the event showed shrinkage of the thrombosed varix. No enhancement was seen in the varix with contrast. On EEG taken several months after the event, isolated spikes were still detected in the left central region.

## DISCUSSION

Isolated cerebral varices may be clinically silent, such that they may be discovered incidentally at autopsy [3]. If they develop clinical symptoms, in many cases they usually cause hemorrhage [3]. On the other hand, varices may cause thrombosis, which is less common [3]. Some reports showed that varix caused epilepsy without hemorrhage or thrombosis [2,4]. Nishioka et al [2] reported a case

Address reprint requests to: Yoshimasa Mori, M.D., Department of Neurosurgery, Nagoya Kyoritsu Hospital, 1-172 Hokke, Nakagawa, Nagoya, Aichi, 4540933 Japan.

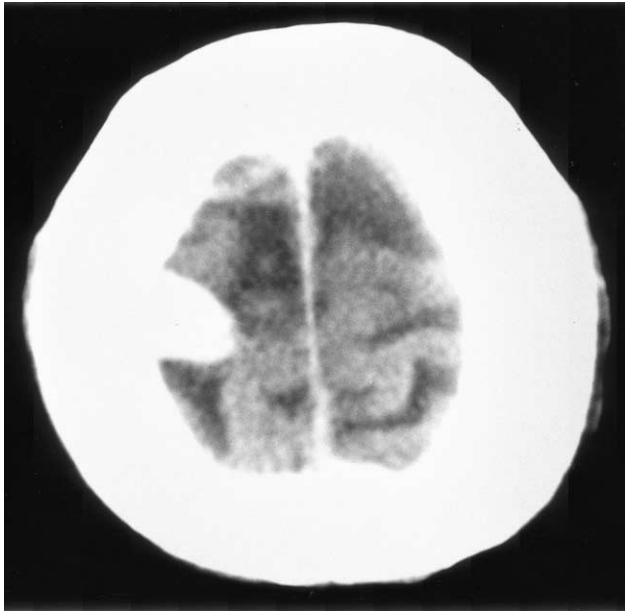
Received July 10, 2002; accepted July 28, 2003.



**1** (A) Coronal T1-weighted MRI with gadolinium (Gd) enhancement. A spindle-shaped cortical venous varix was shown with marked enhancement. (B) Vascular image of MR (analyzed by MIP: maximum intensity projection) with Gd enhancement clearly showed cortical venous structure including varix of central vein. (C) Lateral view of late venous phase of right carotid angiography showed a spindle-shaped varix of central vein. (D) Lateral view of early venous phase of right carotid angiography. The central vein covered a large area of posterior lateral frontal cortex.

of isolated varix of the posterior insular vein. They suspected that epilepsy was caused by disturbance of local circulation. In addition, a large varix may produce symptoms from compression of adjacent structure [1]. Our patient initially suffered from focal seizure, probably because of compression on

the motor cortex by a large varix. Later, she developed status epilepticus following thrombosis of the varix. It was thought to be a result of venous congestion around motor cortex. It is complicated to manage patients with venous varices because they could be potential cause of both thrombosis and



**2** Plain CT just after deterioration of the patient's symptoms. Thrombosis of varix was identified as a high-density mass.

hemorrhage. Close observation is necessary for patients with cerebral varix, and timely assessment and appropriate treatment is needed in case of deterioration of their symptoms.

## CONCLUSION

A varix may be a potential cause of both hemorrhage and thrombosis. Close observation is necessary on patients with cerebral varix. Thrombosis of a varix might be one cause of thrombosis of a large vein or a venous sinus.

## REFERENCES

1. McCormick WF. Pathology of vascular malformations of the brain. In: Wilson CB, Stein BM, eds. *Intracranial Arteriovenous Malformations*. Baltimore: Williams & Wilkins, 1984:44-63.
2. Nishioka T, Kondo A, Nin K, Tashiro H, Ikai Y, Takahashi J. Solitary cerebral varix. Case report. *Neurol Med Chir (Tokyo)* 1990;30:904-7.
3. Noran HH. Intracranial vascular tumors and malformations. *Arch Path Lab Med* 1945;39:393-416.
4. Shibata Y, Hyodo A, Tsuboi K, Yoshii Y, Nose T. Isolated cerebral varix with magnetic resonance imaging findings: case report. *Neurol Med Chir (Tokyo)* 1991;31:156-8.

## COMMENTARY

Dr. Kondo et al present a case report of thrombosis of an isolated parasagittal varix of the Rolandic vein purportedly resulting in venous congestion and

subsequent seizure exacerbation. While the temporal relationship between varix thrombosis and seizure exacerbation is discussed, it would have been interesting to see if a post-thrombosis MR showed increased T2 signal to confirm the diagnosis of venous congestion. Venous varix not associated with an AV fistula is rare in the literature, and the risk of symptomatic thrombosis is not known. Thus it remains unclear whether patients such as this may benefit from oral antiplatelet agents or other anticoagulation to prevent such an untoward event.

**Duke S. Samson, M.D.**

*Department of Neurosurgery  
UT Southwestern Medical Center  
Dallas, Texas*

Isolated cerebral varices are rare vascular malformations that are defined by a focal dilatation of a single vein, involving no neural tissue in their structures [1,2]. Although they usually have a leptomeningeal origin, a rare intra-axial location has also been described [3,4]. Most often isolated cerebral varices are asymptomatic or incidental findings. When they manifest clinically, patients frequently present with a subacute or chronic history of transient, intermittent symptoms, which herald an ictal episode as a correlate of either hemorrhage or thrombosis [1,2]. The etiology of these malformations is only speculative, and their propensity to rupture is unknown [2,3].

This authors' case report depicts, in a remarkable fashion (both clinically and radiographically), the natural history of this particular isolated venous varix associated with the Rolandic vein. The case poses the dilemma of how to manage a vascular malformation of uncertain significance associated with a critical vascular structure.

**Norberto Andaluz, M.D.**

*Vascular Fellow,*

**John M. Tew, Jr., M.D.**

*Professor of Neurosurgery and Medical Director  
The Neuroscience Institute  
Cincinnati, Ohio*

## REFERENCES

1. Noran HH. Intracranial vascular tumors and malformations. *Arch Path Lab Med* 1945;39:393-416.
2. Jellinger K. Vascular malformations of the central nervous system: a morphological overview. *Neurosurg Rev* 1986;9:177-216.
3. Meyer JD, Baghai P, Latchaw RE. Cerebral varix and probable venous angioma: an unusual isolated anomaly. *AJNR* 1983;4:85-7.