

Case Studies

Adverse central nervous system sequelae after selective transforaminal block: the role of corticosteroids

Robert L. Tiso, MD^{a,*}, Thomas Cutler^b, Joseph A. Catania, MD^a,
Karen Whalen, BS Pharm, BCPS^c

^aNew York Pain Center, 7209 Buckley Road, Suite 2R, Liverpool, NY 13088, USA

^bDepartment of Biochemistry and Molecular Biology, State University of New York Upstate Medical University,
766 Irving Ave., Syracuse, NY 13210, USA

^cDepartment of Pharmacy, St. Joseph's Hospital Health Center, 301 Prospect Ave., Syracuse, NY 13203, USA

Received 21 March 2003; accepted 2 October 2003

Abstract

BACKGROUND CONTEXT: Selective transforaminal epidural injections are frequently employed in the treatment of pain emanating from the spine. Complication rates are typically low and include paresthesia, hematoma, epidural abscess, meningitis, arachnoiditis and inadvertent subdural or subarachnoid injection. Persistent paraplegia after lumbar transforaminal block has been recently reported. Undetected intra-arterial injection has been implicated as a possible cause.

PURPOSE: We present a case of massive cerebellar infarction after uneventful selective cervical transforaminal block. Intra-arterial injection of corticosteroid is implicated with focus on particulate size of compound versus blood vessel dimension. Light microscopic data are presented to confirm the potential for embolic vascular occlusion.

STUDY DESIGN/SETTING: Case report; light microscopic data.

PATIENT SAMPLE: A patient underwent selective transforaminal block on the right at the C5–C6 level. There was C5–C6 disc herniation documented by magnetic resonance imaging and C6 radiculopathy by electromyographic studies.

OUTCOME MEASURES: Patient follow-up from medical office records.

METHODS: Needle placement at the C5–C6 foramen on the right was confirmed by biplanar fluoroscopy and injection of contrast medium. Frequent heme-negative aspirations were documented.

RESULTS: In this patient, quadriplegia ensued shortly after injection of corticosteroid solution. The patient was admitted to the neurosurgical intensive care unit and ultimately underwent brainstem decompressive surgery when focal neurologic deficits became evident. Working diagnosis was massive cerebellar infarct. Light microscopic data are presented to illustrate particulate size in corticosteroid solutions and potential for embolic microvascular occlusion. Corticosteroid suspensions (and to a lesser extent solutions) contain large particles capable of occluding metarterioles and arterioles.

CONCLUSIONS: We present a case of quadriplegia and brainstem herniation after selective cervical transforaminal block. We propose a potential role for corticosteroid particulate embolus during unintended intra-arterial injection as a potential mechanism. © 2004 Elsevier Inc. All rights reserved.

Keywords:

Transforaminal block; Cerebellar infarct; Spinal injection; Corticosteroids; Microvascular anatomy; Compounding pharmacies; Fluoroscopy

FDA device/drug status: not applicable.

Nothing of value received from a commercial entity related to this research.

* Corresponding author. New York Pain Center, 7209 Buckley Road, Suite 2R, Liverpool, NY 13088, USA. Tel.: (315) 452-2052; fax: (315) 452-2054.

E-mail address: northpain@cnyemail.com (R.L. Tiso)

Introduction

A 48-year-old woman was admitted to the procedural unit for a right selective C5–C6 transforaminal epidural injection under fluoroscopic guidance. Her history is notable for magnetic resonance imaging (MRI) scan evidence of a C5–C6 herniated nucleus pulposus after a motor vehicle accident

5 months prior. Additionally, nerve conduction studies revealed a C6 radiculopathy. Pertinent physical findings included a height of 5 feet 2 inches and a weight of 300 pounds.

The patient was positioned supine on a C-arm table with the head in a neutral position. Standard physiologic monitoring was applied and intravenous conscious sedation was administered, including midazolam 2 mg and fentanyl 100 mcg. Standard preparation and draping was performed.

Screening fluoroscopy was performed in the lateral plane with the elimination of parallax. With a right anterior oblique orientation and caudad rotation, the C5–C6 cervical neural foramen was identified. The skin overlying this area was anesthetized. A 25-gauge 2-inch Quincke tip spinal needle (Becton Dickinson & Co., Franklin Lakes, NJ, USA) was advanced under direct fluoroscopic visualization to the posterior and inferior aspect of the neural foramen. The image intensifier was then rotated to the anteroposterior projection to demonstrate adequate needle tip position in the lateral mass. Isovue M 200 nonionic contrast medium (Bracco Diagnostics, Princeton, NJ, USA) 2 ml was injected through a microbore tubing, confirming placement by way of a satisfactory lateral epidurogram and extension along the C6 nerve root. The therapeutic medicine of bupivacaine 0.25% 2 ml mixed with triamcinolone 80 mg was injected through microbore tubing with frequent negative aspirations without incident. Total fluoroscopy time was 7 seconds.

The patient remained conscious throughout the procedure. Postprocedure vital signs remained stable. Upon self-transfer from the C-arm table to the stretcher, the patient became unresponsive. Hand ventilation by mask was instituted while reversal agents and supportive medications were administered. Persistent unresponsiveness and an inability to maintain adequate oxygenation resulted in the patient being intubated and stabilized before being transferred to the postanesthesia care unit. Approximately 1 hour after the procedure she regained consciousness and was able to follow commands. However, she had complete loss of movement in the right arm and weakness in the left grip strength. She had minimal strength in the legs bilaterally rating a 1-2/5. The patient was admitted to the neurosurgical intensive care unit for additional workup. She ultimately underwent brain stem decompression surgery when focal neurological deficits became evident. Working diagnosis included a massive cerebellar infarct. She expired the following day.

The problem

In the above case, immediate onset quadriplegia after selective cervical transforaminal block progresses ultimately to brainstem herniation and death. Several cases of paraplegia after lumbar selective transforaminal blocks have been previously reported [1]. Proposed mechanisms include vascular injury or embolus by means of a radicular or larger arterial source. In this case, findings at operation were significant for an anomalous tortuous vertebral artery possibly

related to injury at the time of the prior motor vehicle accident. Pathology revealed bilateral cerebellar infarction as well as left occipital cortex infarction. There was thromboembolism noted at pathology in a leptomeningeal artery adjacent to the left occipital cortex. Radicular arterial injury would explain spinal cord injury but not massive infarction as described in this case. This would be more consistent with vertebral artery injection or terminal branch injury or occlusion. Neither vascular injury nor hematoma was evident at the time of surgery. Thrombus may have been present from prior injury. Triamcinolone suspension was injected, although other corticosteroid suspensions have been implicated [1]. The role of corticosteroid formulation is examined in this study.

Microscopic data

To test the hypothesis that particulate size in corticosteroid formulations may contribute to embolic vascular occlusion, five commonly used preparations were subjected to microscopic analysis.

Taking an unopened vial and shaking vigorously 10 to 20 times prepared all samples. A 1-ml aliquot was drawn from the vial using a 3-ml syringe with an 18-g by 1.5-inch needle. Using a 2-inch 25-g needle, a drop of the sample was placed on a microscope slide after which a cover slip was immediately placed. Needles were chosen to mimic clinical conditions. Images were taken for methylprednisolone acetate (MPA), triamcinolone acetonide (TA) and betamethasone sodium phosphate and betamethasone acetate (BSP-BA) in less than 1 minute. The images for dexamethasone sodium phosphate (DSP) and betamethasone sodium phosphate (BSP) were collected in under 5 minutes.

The samples were examined using a Zeiss Axioskop 2 MOT microscope using the Zeiss (Jena, Germany) Plan-Neofluar 100X objective. Images were taken by a Hamamatsu (Hamamatsu City, Japan) ORCA-ER C47242-95 camera and were analyzed using Improvisation's Openlab 3.1.1 software. Measurements were made by using the measurements module of Openlab 3.1.1. The objective was previously calibrated for measurements. Measurements were recorded and exported to a spreadsheet program. Measurements were arranged according to particulate size. Percentages of those particles were then calculated by dividing the number of particles within a size range and dividing by N, with N being the total number of particles measured: BSP-BA, N=108, TA, N=81, MPA, N=35, DSP, N=27, BSP, N=88.

Table 1 represents analysis of particulate size versus total number of particles. Fig. 1 demonstrates typical photographic images of the five commonly used preparations. Particles in dexamethasone and betamethasone tended to be rodlike and lucent, whereas particles of methylprednisolone and triamcinolone tended to be opaque and amorphous. Additionally, over time, particles of triamcinolone and methylprednisolone tended to coalesce into large aggregates far in

Table 1
Particle Sizes of Various Corticosteroid Compounds

Betamethasone sodium phosphate and betamethasone acetate (Celestone Soluspan [Schering-Plough, Kenilworth, NJ])	Methylprednisolone acetate (Depo-medrol [Pharmacia & Upjohn, Kalamazoo, MI])	Triamcinolone acetonide (Kenalog-40 [Bristol-Myers Squibb, Princeton, NJ])	Dexamethasone sodium phosphate (Decadron [American Regent Laboratories, Shirley, NJ])	Betamethasone sodium phosphate
1–10 μm : 47.73%	1–10 μm : 48.57%	1–10 μm : 37.04%	1–10 μm : 14.81%	1–10 μm : 92.59%
10–20 μm : 28.41%	10–20 μm : 11.43%	10–20 μm : 28.40%	10–20 μm : 14.81%	10–20 μm : 6.48%
20–50 μm : 22.73%	20–50 μm : 31.43%	20–50 μm : 30.86%	20–50 μm : 66.67%	20–50 μm : 0.93%
>50 μm : 1.14%	>50 μm : 8.57%	>50 μm : 3.70%	>50 μm : 3.70%	>50 μm :

excess of 100 μm . Clearly, TA and MPA contain significant amounts of larger particles. This may represent a factor contributing to microvascular “sludging” and subsequent occlusion/infarction.

Corticosteroid review

Common synthetic corticosteroids used in spinal injection procedures are derivatives of prednisolone, which is an analog of cortisol. All have anti-inflammatory potencies somewhat greater than cortisol per dosage unit [2,3]. Methylprednisolone is the methyl derivative of prednisolone, whereas betamethasone, dexamethasone and triamcinolone are all fluorinated derivatives of prednisolone. Additionally, betamethasone is an isomer of dexamethasone. The sodium phosphate moiety renders the steroidal compound water soluble in the case of betamethasone and dexamethasone, rendering both appropriate for parenteral use [2] and possibly safer in the event of inadvertent intravascular injection.

All synthetic corticosteroids have long (36- to 72-hour) biological half lives with resultant long durations of action. Particulate suspensions (MPA, TA, BSP-BA) would theoretically offer the advantage of additional duration of action based on a tissue depot of large, slowly absorbing particles. However, based on the present study, it appears that the risk implied from embolic potential would far outweigh any concern for longevity of response. Table 2 illustrates properties of compounds commonly used for spinal injection therapy.

Microvascular review

The complex blood supply to the spinal cord is partially derived from the spinal branch of a local artery that then divides into anterior and posterior radicular arteries [11,12]. Local arteries supplying corresponding radicular arteries consist of the vertebral, deep cervical, ascending cervical, posterior intercostal, lumbar or lateral sacral arteries [12]. The arteria radicularis magna (artery of Adamkiewicz) is an enlargement of a lumbar anterior radicular artery supplying much of the blood supply to the lower two-thirds of the spinal cord [12]. It has been implicated in paraplegia after

lumbar transforaminal blocks, as mentioned earlier [1]. The vertebral artery travels up the spinal column through the foramina transversaria in each cervical transverse process. It lies within the cervical neural foramen over its anterior aspect. Accordingly, unintended penetration is possible during selective cervical transforaminal blockade. Injury to or embolus within the vertebral artery could cause spinal cord injury by means of radicular arterial occlusion or cerebellar damage by means of migration to the anterior or posterior inferior cerebellar arteries. This would constitute a proposed mechanism for cerebellar infarction in the reported patient.

Fig. 2 illustrates microvascular anatomy with mention of vessel dimension [13]. Clearly, particulate size may play a role in vascular occlusion with intravascular injection. In fact, the particles measured in this study could easily occlude capillaries, metarterioles and, in some cases, arterioles and even arteries. As was shown earlier, aggregate particle size approached 100 μm in some cases, potentially placing large blocks of neural tissue at risk for injury or infarction.

Compounded corticosteroid preparations

All pharmacists receive some education on pharmaceutical compounding as part of their training, and any licensed pharmacist may compound prescribed products.

Compounded prescriptions are mostly limited to topical products, creating liquid preparations for children or adult patients unable to swallow tablets or capsules and compounding for veterinary clients. More recently, however, compounding pharmacists have stepped in to fill the void created by nationwide medication shortages, including sterile products (ie, parenterals).

Compounding pharmacists and compounding pharmacies fall under state regulation, by the individual state board of pharmacy and the state's pharmacy practice act. In many states the legislation regulating pharmacy practice is antiquated, and many pharmacy specialization issues are not addressed. The Food and Drug Administration (FDA) regulates pharmaceutical manufacturers and manufacturing facilities but has no intervening authority over compounding pharmacies unless the pharmacy engages in manufacturing activities. The FDA recently published a Compliance

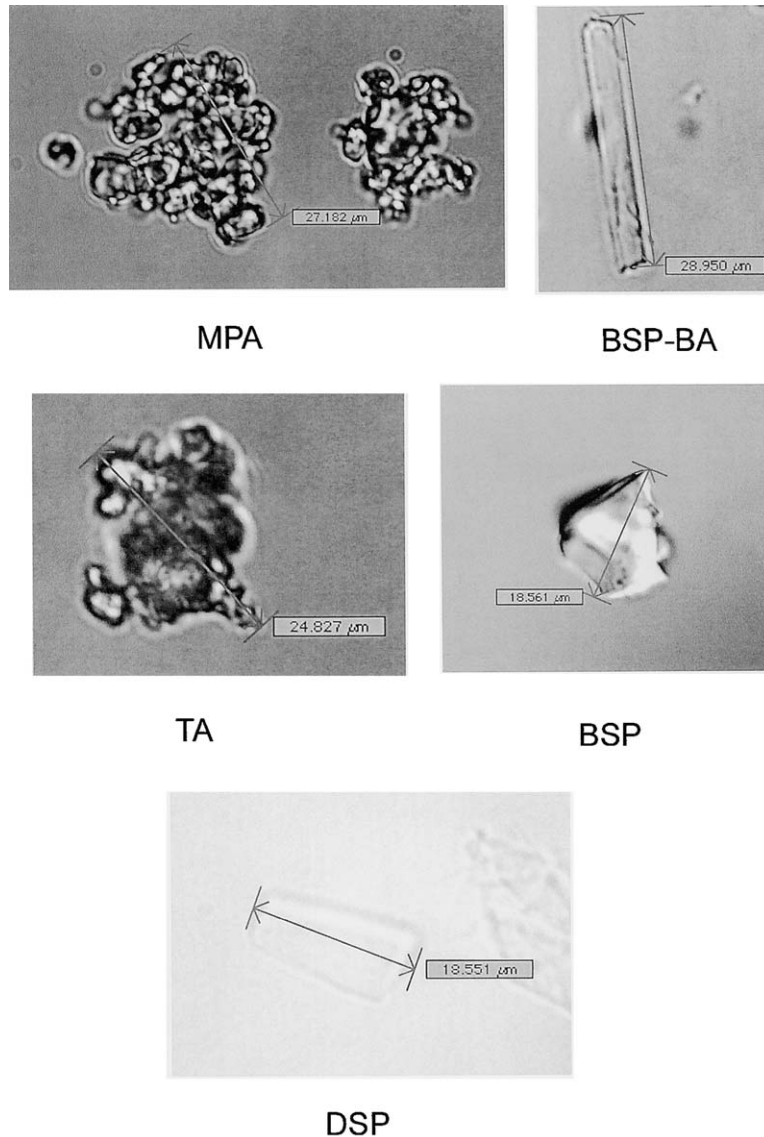


Fig. 1. Typical microscopic appearance of corticosteroids. (Top left) Methylprednisolone acetate. (Top right) Betamethasone sodium phosphate–betamethasone acetate. (Middle left) Triamcinolone acetonide. (Middle right) Betamethasone sodium phosphate. (Bottom) Dexamethasone sodium phosphate.

Policy Guide on pharmacy compounding that identifies activities considered to be beyond compounding and infringing on manufacturing [14]. For example, lowering the dosage strength of a commercially available drug product for a specific patient is considered compounding. Compounding batches of drug products that are copies of FDA-approved products is manufacturing [14].

Quality guidelines for compounding pharmacy include The United States Pharmacopeia (USP 24) [15] and the American Society of Health-System Pharmacists Guidelines on Quality Assurance for Pharmacy-Prepared Sterile Products [16]. In addition, professional organizations provide training and support to pharmacists seeking specialization as a compounding pharmacist, for example, the International Academy of Compounding Pharmacists, Professional Compounding Centers of America and the American Pharmaceutical Association. Membership in and compliance with

guidelines and training provided by the International Academy of Compounding Pharmacists, Professional Compounding Centers of America, the American Pharmaceutical Association or the American Society of Health-System Pharmacists is voluntary.

Quality assurance, sterility and potency are very high priorities for any medication, but the stakes are certainly higher for a sterile, preservative-free parenteral product administered epidurally compared with a product applied topically. In 2001, three meningitis deaths were linked to compounded betamethasone injection contaminated with *Serratia* [17]. In 2002, five cases (two deaths) of *Exophiala dermatitidis* meningitis were traced back to compounded methylprednisolone [18]. In October 2002, the FDA issued a Class I recall of methylprednisolone and Baclofen (Portage Pharmacy, Portage, MI) for injection (preservative free)

Table 2
Corticosteroid properties

Generic name	Betamethasone sodium phosphate and betamethasone acetate	Methylprednisolone acetate	Triamcinolone acetonide	Dexamethasone* sodium phosphate	Betamethasone* sodium phosphate
Brand name	Celestone Soluspan (Schering-Plough, Kenilworth, NJ)	Depo-Medrol (Pharmacia & Upjohn, Kalamazoo, MI)	Kenalog-40 (Bristol-Myers Squibb, Princeton, NJ)	Decadron (American Regent Laboratories, Shirley, NY)	
Dosage form	Suspension	Suspension	Suspension	Solution	Solution
Benzyl alcohol	No	Yes	Yes	Yes	No
pH	6.8–7.2	3.5–7	5–7.5	7.5–10.5	~8.5
Intravenous administration	No	No	No	Yes	Yes
Equivalent dose	Not available	4 mg (sodium succinate)	4 mg	0.75 mg	0.6 mg
Anti-inflammatory potency [†]	25	5 (sodium succinate)	5	30	25
Sodium-retaining potency [‡]	0	0	0	0	0
Pharmacokinetic t-1/2 [§]	Not available	3 hours (sodium succinate)	5 hours	100 min–5 hours	100 min–5 hours
Biologic t-1/2 [§]	Not available	12–36 hours (sodium succinate)	12–36 hours	36–72 hours	36–72 hours

Data from [4–10].

* Betamethasone is identical to dexamethasone but has a 16-betamethyl group instead of a 16-alpha methyl group. They are considered “stereoisomers.”

[†] As a point of reference, the anti-inflammatory potency of hydrocortisone is one and prednisone or prednisolone is four.

[‡] As a point of reference, the sodium-retaining potency of hydrocortisone is two and prednisone or prednisolone is one.

[§] t-1/2 = half-life; half-life (biologic vs pharmacokinetic) is variable because of patient specific physiologic parameters, site and method of administration, water/lipid solubility of the agent and dosage form (suspension vs solution).

prepared by a pharmacy in Michigan because of contamination with *Penicillium* mold, *Methylobacterium* and/or *Mycobacterium chelonae* [19]. A Class II recall was issued for 19 additional parenteral products, including triamcinolone, betamethasone and hyaluronidase, compounded by the same pharmacy because of a lack of assurance of sterility [20]. A study posted to the FDA website by Subramaniam et al. [21] showed when compounded products were compared with their manufacturer-supplied counterparts, 34% failed testing [21]. Of those products that failed, more than half had potency of 70% or less.

Not all compounding pharmacies produce inferior products, but there is no simple way to identify pharmacies that comply with industry standards and guidelines.

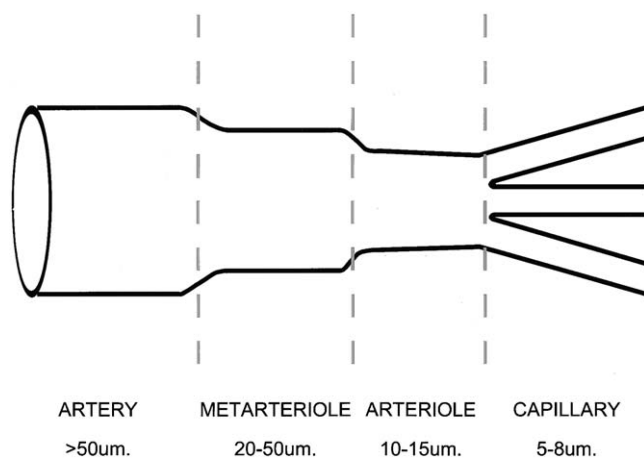


Fig. 2. Illustration of arterial dimension.

Discussion

Epidural corticosteroid injections have been employed for many years for refractory back pain and sciatica. Because of the lack of good clinical outcome studies, their use continues to be debated. Recently, the transforaminal approach to the epidural space has gained increased acceptance because of greater specificity and for its utility as a diagnostic as well as therapeutic intervention. Theoretically, placement under fluoroscopy allows for precise localization in the anterior epidural space where most pain generators are located. Success rates vary from 23% to 75% depending on diagnosis [22,23]. The typical fluoroscopic pattern of a right C5–C6 selective cervical transforaminal block is shown in Fig. 3. Note C6 neural spread with lateral epidural extension.

The use of contrast medium would theoretically add a margin of safety by ensuring neural spread and lack of vascular uptake. However, movement of the needle can occur with further manipulation after placement, or attaching a syringe with therapeutic medication. Therefore, it has become the practice in our institution to use microbore extension tubing to minimize needle manipulation after confirmed placement. Medications are injected through the catheter instead of the needle. Multiple level injections would require the use of multiple microbore extensions.

Vertebral artery injection in an awake patient would inevitably cause signs of central nervous system toxicity, which may manifest as tinnitus, perioral numbness or seizures. Accordingly, it has become our practice to test dose with local anesthetics and allow time to pass before injecting corticosteroid. Of course, assuming that patient awareness is necessary to observe signs and symptoms of central

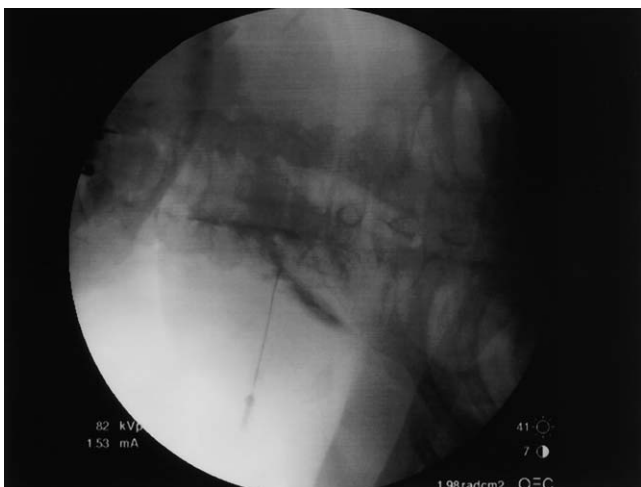

Fig. 3. Typical contrast pattern for right selective C5–C6 transforaminal block.

nervous system toxicity, it follows that sedation should be kept to a minimum.

Traditionally, 25-gauge needles have been used in the cervical region to minimize trauma to the great vessels of the neck and to diminish pain from potential paresthesias in the area. Interestingly, such smaller-gauge needles may be less likely to detect arterial penetration secondary to flow restriction. The use of these needles is currently undergoing reevaluation in this institution.

Finally, mention should be made of benzyl alcohol, which is added as a preservative in many commercially available corticosteroid preparations. Debate exists as to the neurotoxicity of this agent. Paraplegia, neural degeneration and demyelination have been reported to occur with this [24–26]. Currently, methylprednisolone, dexamethasone and triamcinolone contain benzyl alcohol, whereas the betamethasone derivatives do not. These substances are used in all pain practices to some extent with a long track record of safety. It should be mentioned that the immediate onset of symptoms in this patient is more consistent with an embolic event than with demyelinating sequelae.

In conclusion, there are no studies advocating one corticosteroid formulation over another for safety. Similarly, there are no good clinical outcome studies comparing one method of epidural administration over another. Safety and efficacy are probably more dependent on clinician expertise in performing such procedures. Despite decades of experience and a good track record of safety, the practice of epidural corticosteroid administration requires further study.

Conclusion

We present a case of serious neurologic consequence after selective cervical transforaminal block. Paraplegia after lumbar selective transforaminal block has also been reported [1]. Particulate size in corticosteroid suspensions may play

a role and their use should be reevaluated. All tested compounds have the potential for microvascular occlusion. In order to avoid future problems, the following suggestions are offered:

1. The use of corticosteroid solutions only (ie, dexamethasone sodium phosphate and betamethasone sodium phosphate). Avoid suspensions within the neural foramina because of concerns with precipitation and aggregate clumping. If a suspension is to be used, BSP-BA would be preferable because of overall smaller size of particulate matter. It may be prudent to consider the exclusive use of dexamethasone sodium phosphate because of concerns spurred by reports of contamination through compounding pharmacies.
2. Confirmation of definitive extravascular location of the needle tip by biplanar fluoroscopy using noniodinated contrast medium. The needle tip should be in the posterior aspect of the neural foramen on an oblique plane and midway through the lateral mass on an anteroposterior plane. Injected contrast medium should demonstrate an adequate epidurogram with neural extension and lack of vascular uptake.
3. Test dosing with local anesthetic to determine intravascular injection (ie, confirmation of absence of central nervous system hyperirritability) with time allowed to elapse before injection of corticosteroid preparation.
4. Slow injection of corticosteroid with frequent heme-negative aspiration.
5. The use of microbore (ie, “pig tail”) attachments to each needle so that the syringe with therapeutic or diagnostic medication is attached to the catheter instead of the needle, thus minimizing needle manipulation after placement.
6. Minimizing sedation to allow earlier detection of central nervous system dysfunction.
7. There may be a role for larger-gauge needles to prevent false-negative aspirations or short bevel or blunt needles to minimize vessel trauma.

References

- [1] Houten JK, Errico TJ. Paraplegia after lumbosacral nerve root block. *Spine J* 2002;2:70–5.
- [2] Stoelting R. Pharmacology and physiology in anesthetic practice. Philadelphia: JB Lippincott, 1987:402–4.
- [3] Gilman G, Goodman L, Rall T, et al. The pharmacologic basis of therapeutics. New York: Macmillan Publishing Company, 1985: 1473–7.
- [4] Gums JG, Terpening CM. Adrenal gland disorders. In: Dipiro JT, Talbert RL, Yee GC, Matzke GR, Wells BG, Posey LM, editors. Pharmacotherapy: a pathophysiology approach. New York: McGraw-Hill, 2002:1390–1.
- [5] McLeod DC, Finklestein E, Drugdex Editorial Staff. Comparative dosage table—corticosteroid properties and potencies. Micromedex Healthcare Series, March 2001.

- [6] Dexamethasone sodium phosphate injection, United States Pharmacopeia Prescribing Information; Elkins-Sinn, Cherry Hill, NJ; September 1994.
- [7] Depo-Medrol (methylprednisolone acetate) injection, United States Pharmacopeia Prescribing Information; Pharmacia and Upjohn, Kalamazoo, MI; April 1999.
- [8] Celestone Soluspan (betamethasone sodium phosphate and betamethasone acetate) injectable suspension, United States Pharmacopeia Prescribing Information; Schering Corporation, Kenilworth, NJ; October 1999.
- [9] Kenalog-40 (triamcinolone acetonide) injectable suspension, United States Pharmacopeia Prescribing Information; Apoticon, Princeton, NJ; September 1998.
- [10] Orth DN, Kovacs WJ. Structure-function relationships of synthetic glucocorticoids. UpToDate Online 10.3, April 2001. www.uptodate.com. Accessed 1/7/03.
- [11] Warwick R, Williams P. Gray's anatomy. Philadelphia: WB Saunders Company, 1973:41–644,839–40.
- [12] Moore K. Clinically oriented anatomy. Baltimore: Williams and Wilkins, 1980:651–5.
- [13] Ruch TC, Patton HD. Physiology and biophysics, vol. 2. Philadelphia: WB Saunders Company, 1974:130–1.
- [14] US Food and Drug Administration. Compliance policy guidance for Food and Drug Administration staff and industry. Section 460-200, pharmacy compounding. Available at: http://www.fda.gov/ora/compliance_ref/cpg/cpgdrg/cpg460-200.html. Accessed January 7, 2003.
- [15] The United States Pharmacopeia, 24th rev., and The national formulary, 19th ed. Rockville, MD: The United States Pharmacopeial Convention, 1999.
- [16] American Society of Health-System Pharmacists. ASHP guidelines on quality assurance for pharmacy-prepared sterile products. *Am J Health Sys Pharm* 2000;57:1150–69.
- [17] Traynor K. Meningitis deaths linked to drug shortage. *ASHP News*, July 17, 2001. Available at: <http://www.ashp.org/news/showArticle.cfm?cfid=13024576&CFToken=66736045&id=2425>. Accessed January 7, 2003.
- [18] Centers for Disease Control. *Exophiala* infection from contaminated injectable steroids prepared by a compounding pharmacy—United States, July–November (2002). *MMWR* 51;1109–12.
- [19] US Food and Drug Administration. Enforcement report, October 16, 2002. Available at: <http://www.fda.gov/bbs/topics/enforce/2002/ENF00765.html>. Accessed January 7, 2003.
- [20] US Food and Drug Administration. Enforcement report, October 23, 2002. Available at: <http://www.fda.gov/bbs/topics/enforce/2002/ENF00766.html>. Accessed January 7, 2003.
- [21] Subramaniam V, Sokol G, Zenger V, et al. Study of drug products compounded by a group of community pharmacies: findings from a Food and Drug Administration study. Available at: <http://www.fda.gov/cder/pharmcomp/communityPharmacy/default.htm>. Accessed January 7, 2003.
- [22] Rosenberg SK, Grabinsky A, Kooser C, et al. Effectiveness of transforaminal epidural steroid injections in low back pain: a one-year experience. *Pain Physician* 2002;5:266–70.
- [23] Manchikanti L. Transforaminal lumbar epidural steroid injections. *Pain Physician* 2000;3:374–98.
- [24] Manchikanti L. Role of neuraxial steroids in interventional pain management. *Pain Physician* 2002;5:182–99.
- [25] Craig DB, Habib GG. Flaccid paraparesis following obstetrical epidural anesthesia. Possible role of benzyl alcohol. *Anaesth Analg* 1977;56:219–22.
- [26] Bagshawe KD, Magrath IT, Golding PR. Intrathecal methotrexate. *Lancet* 1969;2:1258.