

# Remote Cerebellar Hemorrhage Following Supratentorial Craniotomy

## —Case Report—

Takashi MARUYAMA, Keisuke ISHII, Mitsuo ISONO, Tatsuya ABE,  
Minoru FUJIKI, and Hidenori KOBAYASHI

*Department of Neurosurgery, Oita University School of Medicine, Oita*

### Abstract

A 63-year-old man presented with sudden severe headache. Computed tomography (CT) demonstrated subarachnoid hemorrhage. Cerebral angiography demonstrated an aneurysm of the anterior communicating artery. Left frontotemporal craniotomy and neck clipping of the aneurysm via the pterional approach were performed. CT obtained 18 hours after surgery revealed cerebellar hemorrhage, and magnetic resonance (MR) imaging 17 days postoperatively demonstrated that the hemorrhage was located within the folia. Neurological examination after surgery revealed slight dysarthria after drainage of cerebrospinal fluid (CSF) but no other neurological deficits. Follow-up CT and MR imaging showed characteristic findings of postoperative cerebellar hemorrhage clearly different from those of hypertension. The cerebellar hemorrhage was probably secondary to overdrainage of CSF. He was discharged without deficits.

Key words: cerebellar hemorrhage, complication, craniotomy, subarachnoid hemorrhage, ruptured cerebral aneurysm, suction drainage

### Introduction

Intracranial hemorrhage following surgery is well known, but cerebellar hemorrhage is rare as a complication of supratentorial craniotomy with an incidence of 0.08%<sup>12)</sup> to 0.6%.<sup>9)</sup> The incidence of cerebellar hemorrhage is especially high at 12.9% in patients who underwent temporal lobe resection.<sup>6)</sup> Furthermore, the frequency of posterior fossa hemorrhage after clipping of an anterior circulation aneurysm was 3.5%, much higher than in other reports.<sup>3)</sup> This complication may occur not only after craniotomy but also after spinal surgery.<sup>2,4,8,10)</sup>

We describe a case of cerebellar hemorrhage which occurred after left frontotemporal craniotomy and neck clipping of a ruptured cerebral aneurysm.

### Case Report

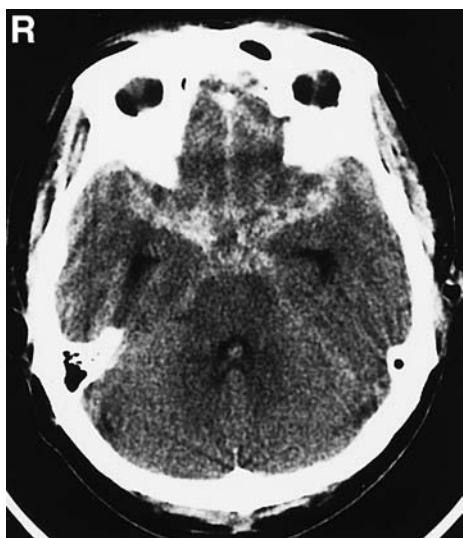
A 63-year-old man presented with sudden onset of

severe headache. Twenty minutes later, he was brought to our hospital by ambulance. On admission, his consciousness was alert and there were no focal symptoms. Computed tomography (CT) showed subarachnoid hemorrhage (Fig. 1). Cerebral angiography demonstrated an aneurysm of the anterior communicating artery, but no other aneurysms or vascular anomalies including the posterior fossa (Fig. 2). In addition, there was no venous return lag or obstruction of the sinuses or bridging veins. He had no history of arterial hypertension or coagulation disorder.

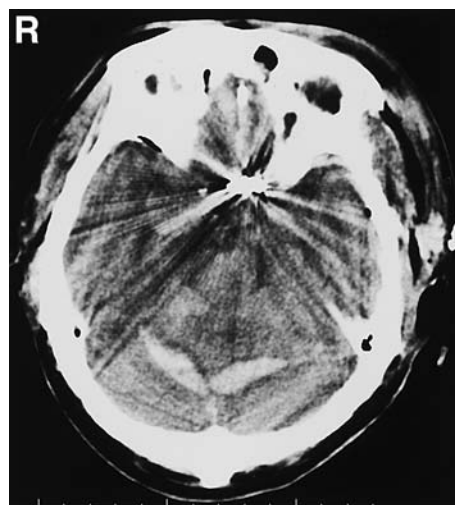
The following day, surgery was performed in the supine position with the head rotated 45° to the right. Left frontotemporal craniotomy and neck clipping of the aneurysm via the pterional approach were performed. Before the dura mater was opened, 300 ml of 20% mannitol was administered. His blood pressure remained within normal limits throughout the surgical procedure, but transient hypertension (maximal systolic blood pressure 200 mmHg) was

Received March 13, 2003; Accepted January 16, 2004

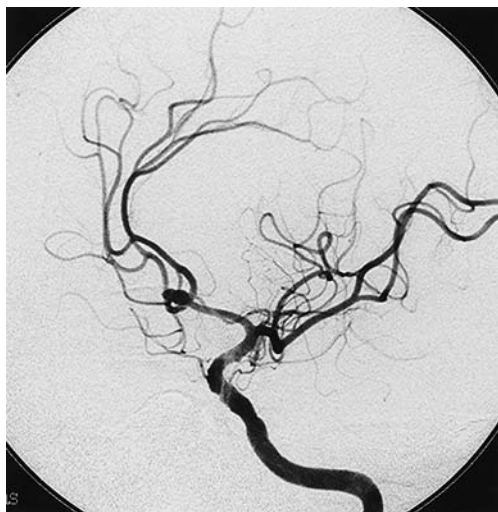Author's present address: K. Ishii, M.D., Department of Neurosurgery, Helsinki University Central Hospital, Helsinki, Finland.



**Fig. 1** Computed tomography scan on admission demonstrating subarachnoid hemorrhage without cerebellar hemorrhage.



**Fig. 3** Computed tomography scan 18 hours postoperatively demonstrating bilateral and symmetrical cerebellar hemorrhage spreading along the cerebellar fissure or folia.



**Fig. 2** Preoperative left internal carotid angiogram (left oblique projection) demonstrating an aneurysm of the anterior communicating artery, but no other aneurysms or vascular anomalies including the posterior fossa.

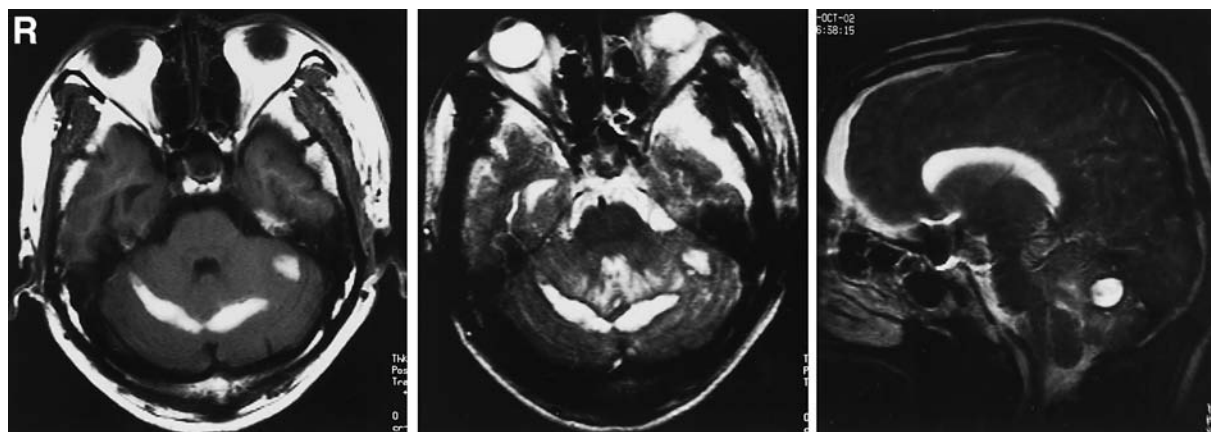
observed at the end of surgery. During wound closure, a subgaleal suction drain tube was inserted and attached to a suction drainage system while the patient was still in the operating room. He awoke from anesthesia with no problems, and there were no remarkable neurological deficits. Ninety minutes after wound closure, 250 ml of cerebrospinal fluid (CSF), mixed with blood, was drained. Thereafter,

the CSF drainage was gradually decreased to total 280 ml 6 hours later, and 310 ml when stopped 13 hours later. There were no remarkable neurological symptoms or vital changes suggesting an intracranial incident during this time. However, in retrospect, he manifested slight dysarthria when the 250 ml of fluid was drained.

Preoperative and postoperative laboratory studies showed the prothrombin times, partial thromboplastin times, and platelet counts were within the normal ranges. Routine CT obtained 18 hours postoperatively demonstrated bilateral cerebellar hemorrhage (Fig. 3). The suction drainage tube was removed on the second operative day. Magnetic resonance (MR) imaging 17 days postoperatively demonstrated hemorrhage within the cerebellar folia underneath the tentorium (Fig. 4). His symptoms gradually improved and follow-up CT revealed that the hemorrhage had gradually been absorbed and had disappeared. Cerebral angiography 14 days postoperatively demonstrated successful clipping of the aneurysm and no other abnormal findings as noted preoperatively. He was free of symptoms at discharge.

## Discussion

Cerebellar hemorrhage following supratentorial craniotomy may occur as an intraoperative or postoperative event. However, the timing of the hemorrhage occurred is difficult to determine, because postoperative CT is generally not performed



**Fig. 4** Axial T<sub>1</sub>-weighted (*left*), axial T<sub>2</sub>-weighted (*center*), and sagittal T<sub>1</sub>-weighted (*right*) magnetic resonance images 17 days postoperatively demonstrating cerebellar hemorrhage within the cerebellar folia underneath the tentorium.

immediately after surgery and most hemorrhages are detected on routine follow-up CT. A retrospective study analyzing early postoperative and follow-up CT indicated that cerebellar hemorrhage occurred as a postoperative rather than an intraoperative event.<sup>6)</sup> In our case, routine CT obtained 18 hours after craniotomy demonstrated cerebellar hemorrhage, and follow-up CT and MR imaging showed no progression of the hemorrhage, but these findings cannot indicate the time of occurrence. However, the patient did not manifest dysarthria on awaking from the anesthesia, indicating postoperative occurrence.

The pathophysiological mechanism of cerebellar hemorrhage following craniotomy remains unclear, although remote cerebellar hemorrhage may be venous in origin.<sup>3,5-7,11,12,16)</sup> Two mechanisms were mainly considered in previously reported cases. First, intracranial hypotension due to removal of a supratentorial space-occupying mass or CSF loss induces a critical increase in the transmural pressure of veins or venules resulting in tearing of these vessels.<sup>6,7,12,15)</sup> Second, intracranial hypotension causes displacement or sagging of the cerebellum, and stretching of the cerebellar veins which may then tear.<sup>13,15,16)</sup> The characteristic CT and MR imaging findings clearly differ from those of hypertension, so strongly support the idea that postoperative cerebellar hemorrhage is venous in origin. Cerebellar hemorrhage as a complication of supratentorial surgery is located parallel to the cerebellar folia and fissures.<sup>3,9,12,14,16)</sup> In addition, the hemorrhage is often bilateral and symmetrical. In contrast, typical spontaneous cerebellar hemorrhage occurs in the center of the cerebellar parenchyma and usually does not involve the subarachnoid

space.

In our case, the image findings were especially characteristic. The significant causative factor of postoperative cerebellar hemorrhage appeared to be overdrainage of CSF, because a large amount of CSF (250 ml) mixed with blood was rapidly drained only 90 minutes postoperatively. The intracranial pressure must have changed quickly due to this rapid loss of CSF. There are no previous details of the amount of CSF drained in the early postoperative period. Our case strongly supports the hypothesis that the causative mechanism of this hemorrhage is displacement or sagging of the cerebellum due to overdrainage of CSF, leading to stretching and tearing of the superior vermician veins and their tributaries. However, the pathophysiological mechanism of remote cerebellar hemorrhage following supratentorial craniotomy may be multifactorial, and specific causes are difficult to identify. Various other major causative factors of postoperative remote cerebellar hemorrhage have previously been suggested, such as intraoperative rotation or extension of the head,<sup>11,12)</sup> arterial hypertension, and disturbance of coagulation due to the use of heparin<sup>7)</sup> or valproic acid.<sup>12,15)</sup> Unfortunately, we could not pinpoint the predictive factor of this complication in our case.

The prognosis for patients with postoperative cerebellar hemorrhage is usually good, with mild and transient neurological dysfunction. However, several reported patients have had a poor outcome.<sup>1,7,11)</sup> Careful intraoperative and postoperative care to manage the various risk factors, especially rapid overdrainage of CSF if suction drainage is used, is required to avoid this complication.

## References

- 1) Brisman MH, Bederson JB, Sen CN, Germano IM, Moore F, Post KD: Intracerebral hemorrhage occurring remote from the craniotomy site. *Neurosurgery* 39: 1114-1122, 1996
- 2) Chaddock WM: Cerebellar hemorrhage complicating cervical laminectomy. *Neurosurgery* 9: 185-189, 1981
- 3) Cloft HJ, Matsumoto JA, Lanzino G, Cail WS: Posterior fossa hemorrhage after supratentorial surgery. *AJNR Am J Neuroradiol* 18: 1573-1580, 1997
- 4) Friedman JA, Ecker RD, Piepgras DG, Duke DA: Cerebellar hemorrhage after spinal surgery. Report of two cases and literature review. *Neurosurgery* 50: 1361-1364, 2002
- 5) Friedman JA, Piepgras DG, Duke DA, McClelland RL, Bechtle PS, Maher CO, Morita A, Perkins WJ, Parisi JE, Brown RD Jr: Remote cerebellar hemorrhage after supratentorial surgery. *Neurosurgery* 49: 1327-1340, 2001
- 6) Honegger J, Zentner J, Spreer J, Carmona H, Schulze-Bonhage A: Cerebellar hemorrhage arising postoperatively as a complication of supratentorial surgery: a retrospective study. *J Neurosurg* 96: 248-254, 2002
- 7) König A, Laas R, Herrmann HD: Cerebellar haemorrhage as a complication after supratentorial craniotomy. *Acta Neurochir (Wien)* 88: 104-108, 1987
- 8) Mikawa Y, Watanabe R, Hino Y, Ishii R, Hirano K: Cerebellar hemorrhage complicating cervical durotomy and revision C1-C2 fusion. *Spine* 19: 1169-1171, 1994
- 9) Miyamoto Y, Nakasu S, Nakasu Y, Handa J: [Postoperative intracerebral hematoma remote from the site of craniotomy]. *Neurol Med Chir (Tokyo)* 25: 219-222, 1985 [Jpn, with Eng abstract]
- 10) Morandi X, Riffaud L, Carsin-Nicol B, Guegan Y: Intracerebral hemorrhage complicating cervical "hourglass" schwannoma removal. Case report. *J Neurosurg* 94 (1 Suppl): 150-153, 2001
- 11) Papanastassiou V, Kerr R, Adams C: Contralateral cerebellar hemorrhagic infarction after pterional craniotomy: report of five cases and review of the literature. *Neurosurgery* 39: 841-852, 1996
- 12) Toczek MT, Morrell MJ, Silverberg GA, Lowe GM: Cerebellar hemorrhage complicating temporal lobectomy. Report of four cases. *J Neurosurg* 85: 718-722, 1996
- 13) Tomii M, Nakajima M, Ikeuchi S, Ogawa T, Abe T: [Infratentorial hemorrhage following supratentorial surgery]. *No Shinkei Geka* 27: 921-925, 1999 [Jpn, with Eng abstract]
- 14) Waga S, Shimosako S, Sakakura M: Intracerebral hemorrhage remote from the site of the initial neurosurgical procedure. *Neurosurgery* 13: 662-665, 1983
- 15) Yacubian EM, de Andrade MM, Jorge CL, Valério RM: Cerebellar hemorrhage after supratentorial surgery for treatment of epilepsy: report of three cases. *Neurosurgery* 45: 159-162, 1999
- 16) Yoshida S, Yonekawa Y, Yamashita K, Ihara I, Morooka Y: Cerebellar hemorrhage after supratentorial craniotomy—report of three cases. *Neurol Med Chir (Tokyo)* 30: 738-743, 1990

---

Address reprint requests to: K. Ishii, M.D., Department of Neurosurgery, Oita University School of Medicine, 1-1 Idaigaoka, Hasama-machi, Oita-gun, Oita 879-5593, Japan.  
e-mail: keisuke@med.oita-u.ac.jp