

Clinical/Scientific Notes

Risus Sardonius After Thalamic Haemorrhage

Igor Sibon, MD* and Pierre Burbaud, PhD

*Fédération de Neurosciences Cliniques, Centre Hospitalier
Universitaire Bordeaux, Bordeaux, France*

Abstract: We describe an uncommon movement disorder after stroke. A 70-year-old man was admitted for a right thalamic haemorrhage and 1 week later developed bilateral contractions of the face. Electromyographic study revealed a bilateral facial dystonia. The association of this bilateral facial dystonia and vertical gaze palsy produced the aspect of a “risus sardonius.”
© 2004 Movement Disorder Society

Key words: dystonia; thalamic lesion

Secondary dystonia is observed in a large spectrum of diseases associated with basal ganglia lesions (for review, see Garcia de Yébenes et al.¹). In most cases, the lesions involve the posterior putamen,² and more rarely the caudate nucleus or pallidum.³ The role of the thalamus in the pathophysiology of secondary dystonia remains unclear since the lesions can induce dystonia⁴ but they have also been used in the past, with some success, as a surgical treatment for dystonia.⁵ Dystonia occurring after thalamic lesions includes myoclonic dystonia predominating in the hand with dystonic postures and slow pseudo-athetoid movements. The lesions frequently encompass both the ventral intermediate (Vim) and ventral caudal (Vc) nuclei of the thalamus.^{3,4,6,7} In addition, postural and action tremor has been observed after lesions of the Vim.³ To our knowledge, dystonia restricted to the lower face has not until now been observed after vascular thalamic lesions. We report on a case of bilateral tonic facial spasm leading to a “risus sardonius” secondary to a right thalamic haemorrhage.

Case Report

A 70-year-old man was admitted to the emergency unit for sudden left-sided hemiplegia. Past medical history included atrial fibrillation treated by anticoagulants and essential thrombocythemia treated by hydroxycarbamide (Hydrea). Initial clinical examination revealed flaccid hemiplegia, left-sided anaesthesia, a central facial palsy and left-sided lateral hemianopia, vertical gaze palsy, dysarthria, and dysphagia. Cerebral computed tomography (CT) scan showed a right thalamic haemorrhage (Fig. 1). Serum biological parameters were normal and

the diagnosis of thalamic haemorrhage secondary to anticoagulants was suggested. One week after stroke, clonic contractions of the left side of his face appeared in association with permanent contraction of the right side. These movements abated when the patient was asleep and increased with emotions. The association of this bilateral facial dystonia and vertical gaze palsy produced the aspect of a sardonic smile (Fig. 2A,B). Magnetic resonance imaging (MRI) confirmed the diagnosis of right thalamic haemorrhage but failed to find any associated brainstem lesions. Electroencephalographic (EEG) recording showed slow frontal waves without paroxysms, thus ruling out epileptic discharges. Electromyographic (EMG) study revealed a higher muscle tone in the facial muscles with superimposed synchronous EMG bursts and disappearance of muscle tone as arousal decreased (Fig. 3A–C). This bilateral facial dystonia resolved spontaneously in 3 months.

Discussion

Hyperkinetic movement disorders are uncommon after stroke (1%).⁸ They occur generally secondary to lesions of the posterior putamen and more rarely to the caudate nucleus, pallidum, or thalamus.^{2–4} Among these disorders, late-onset dystonia is the most frequent and appears after a delay ranging from some weeks to several years.¹ To explain this delay, a sprouting of dendrites within the lenticular formation has been hypothesised. In our case, the latency between stroke and dystonia (1 week) was particularly short and suggested direct involvement of the lesion in genesis of the movement disorder. Although rarer, short-onset dystonia appearing immediately or a few days after a thalamic lesion has been reported previously.⁴ An acute thalamic lesion could indeed disorganise the

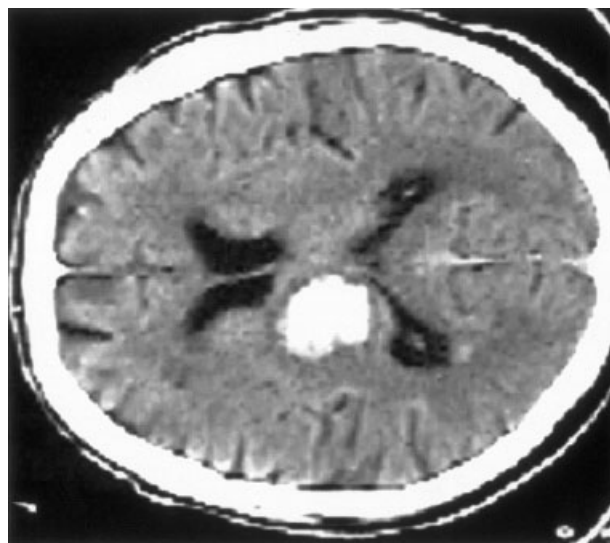


FIG. 1. Cerebral CT scan found a right thalamic haemorrhage.

*Correspondence to: Dr. I. Sibon, Service de Neurologie, Hôpital Pellegrin, Place Amélie Raba-Léon, 33076 Bordeaux cedex, France.
E-mail: igor.sibon@chu-bordeaux.fr

Received 12 June 2003; Revised 4 September 2003; Accepted 9 September 2003

Published online 19 March 2003 in Wiley InterScience (www.interscience.wiley.com). DOI: 10.1002/mds.10675

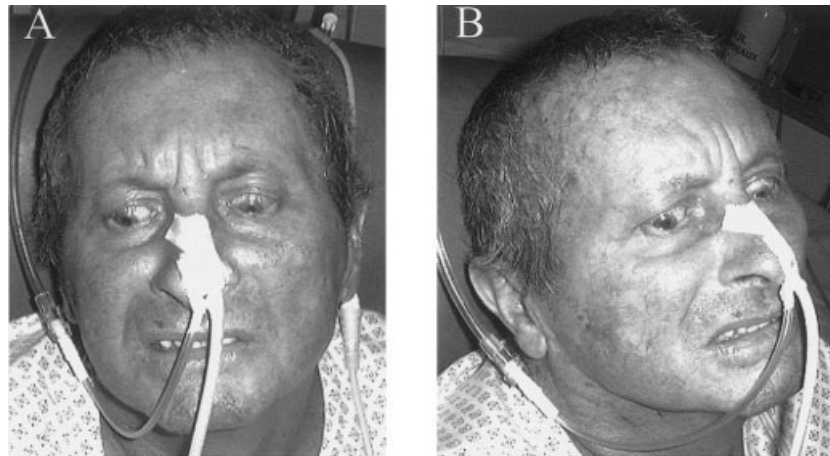


FIG. 2. A, B: "Risus sardonicus." The patient had bilateral facial dystonia with bilateral vertical gaze palsy.

subcortical inputs impinging on the premotor cortex. In an experimental study carried out in the monkey, we found that pharmacologic injections of bicuculline, a gamma aminobutyric acid (GABA) antagonist, into the motor thalamus induced

acute dystonia, the type of which depended on the site of injection within the pallidal or motor segments.^{9,10} Moreover, electrophysiological recordings carried out in primary dystonic patients during surgery for deep brain stimulation have re-

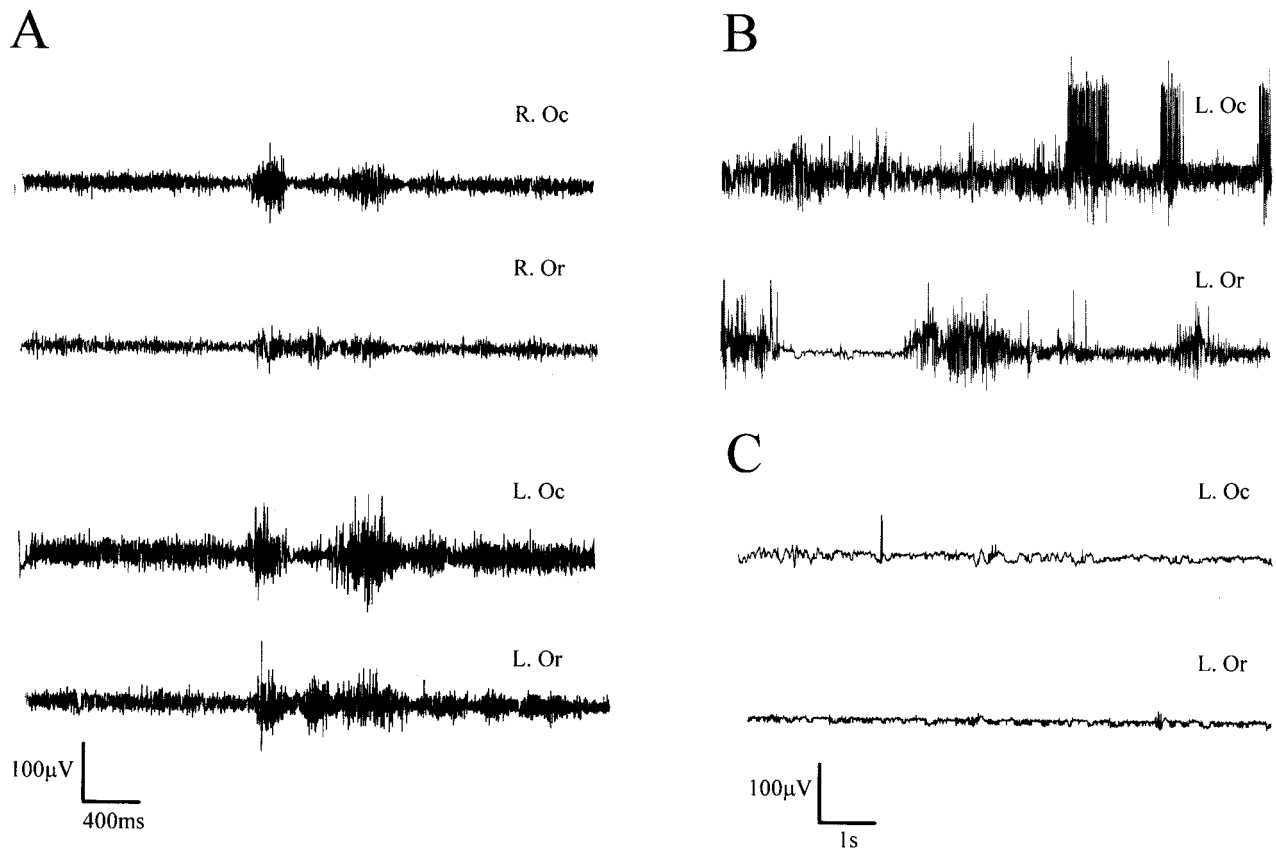


FIG. 3. Electromyographic (EMG) data. **A:** Surface recordings in the right orbicularis oculi (R. Oc), right orbicularis oris (R. Or), left orbicularis oculi (L. Oc), left orbicularis oris (L. Or). Increased tonus was observed at rest on both side but predominated on the left with superimposed myoclonic bursts in the four muscles. **B:** Needle detection recordings on the left side; the patient is awake; note the myoclonic jerks. **C:** Same recording when the patient is asleep; both the background of tonic activity and myoclonic jerks have disappeared.

vealed an alteration in the pattern of thalamic neurone activity, with a decrease in the discharge rate and a widespread response to somatosensory inputs.¹¹ This suggests that the focusing processing of information originating from subcortical regions is altered in dystonia. A common view is that this phenomenon could induce overspreading of cortical activity leading to dystonia.¹²

An unusual feature in our patient was that the dystonic symptoms were restricted to the face mimicking the procerus sign described in progressive supranuclear palsy (PSP).¹³ Facial dystonia is indeed a rare feature of secondary dystonia, at least when associated with vascular lesions. The commonest type involves the distal musculature as in hemichorea, hemiballism, or hemidystonia.⁸ A myoclonic component has been reported frequently after thalamic lesions, sometimes in association with slow pseudo-athetoid movements.^{3,4,6} This is particularly true when the lesions are located in the posterior motor thalamus, which is considered a relay for cerebellar inputs to the cortex. In our case, the myoclonic jerks were located mainly on the hemiface contralateral to the thalamic lesion but the tonic spasm was bilateral. To our knowledge, only 1 case of blepharospasm has been reported after vascular thalamic lesion⁴; the symptomatology was also bilateral whereas the lesion was located in the right thalamus. In our case, however, the dystonic spasm involved the lower part of the face. This suggests that a unilateral thalamic lesion might influence muscle tone on both sides of the face. Our patient also exhibited vertical gaze palsy. This has been reported previously after unilateral thalamic infarction.¹⁴ The mechanism remains a matter of debate but could involve a dysfunction of either the thalamocortical output or the brainstem through the reticular formation controlling vertical gaze movements and facial motoneuron excitability.^{14,15}

In conclusion, this observation suggests that "risus sardonius" could be an uncommon presentation of secondary dystonia due to a thalamic lesion.

References

- Garcia de Yebenes J., Sanchez Pernaute R, Taberno C. Symptomatic dystonias. In: Watts RL, Keller WC, editors. *Movement Disorders: neurologic principles and practice*. UK: McGraw-Hill; 1997. p 455–475.
- Bhatia KP, Marsden CD. The behavioural and motor consequences of focal lesions of the basal ganglia in man. *Brain* 1994;117:859–876.
- Lehericy S, Vidailhet M, Dormont D, et al. Striatopallidal and thalamic dystonia. A magnetic resonance imaging anatomoclinical study. *Arch Neurol* 1996;53:241–250.
- Lee MS, Marsden CD. Movement disorders following lesions of the thalamus or subthalamic region. *Mov Disord* 1994;9:493–507.
- Cardoso F, Jankovic J, Grossman RG, Hamilton WJ. Outcome after stereotactic thalamotomy for dystonia and hemiballismus. *Neurosurgery* 1995;36:501–507.
- Pettigrew LC, Jankovic J. Hemidystonia: a report of 22 patients and a review of the literature. *J Neurol Neurosurg Psychiatry* 1985;48:650–657.
- Lehericy S, Grand S, Pollak P, et al. Clinical characteristics and topography of lesions in movement disorders due to thalamic lesions. *Neurology* 2001;25:57:1055–1066.
- Ghika-Schmid F, Ghika J, Regli F, Bogousslavsky J. Hyperkinetic movement disorders during and after acute stroke: the Lausanne Stroke Registry. *J Neurol Sci* 1997;146:109–116.
- Guehl D, Burbaud P, Boraud T, Bioulac B. Bicuculline injections into the rostral and caudal motor thalamus of the monkey induce different types of dystonia. *Eur J Neurosci* 2000;12:1033–1037.
- Macia F, Escola L, Guehl D, Michelet T, Bioulac B, Burbaud P. Neuronal activity in the monkey motor thalamus during bicuculline-induced dystonia. *Eur J Neurosci* 2002;15:1353–1362.
- Vitek JL. Pathophysiology of dystonia: a neuronal model. *Mov Disord* 2002;17(Suppl.):49–62.
- Berardelli A, Rothwell JC, Hallett M, Thompson PD, Manfredi M, Marsden CD. The pathophysiology of primary dystonia. *Brain* 1998;121:1195–1212.
- Romano S, Colosimo C. Procerus sign in progressive supranuclear palsy. *Neurology* 2001;57:1928.
- Clark JM, Albers GW. Vertical gaze palsies from medial thalamic infarction without midbrain involvement. *Stroke* 1995;26:1467–1470.
- Larumbe R, Vaamonde J, Artieda J, Zubieta JL, Obeso JA. Reflex blepharospasm associated with bilateral basal ganglia lesion. *Mov Disord* 1993;8:198–200.

Long-Term Outcome of Clozapine Use for Psychosis in Parkinsonian Patients

Hubert H. Fernandez, MD,* Edward M. Donnelly, MD,
and Joseph H. Friedman, MD

*Department of Clinical Neurosciences, Brown University
School of Medicine, Providence, Rhode Island, USA*

Abstract: A retrospective analysis was carried out on 39 parkinsonian patients on clozapine treatment ≥ 24 months for psychosis. The cohort had a mean age of 76 years and an average clozapine dose of 47 mg/day over 60 months of clozapine use. Of 39 patients, 13 (33%) patients were eventually admitted to nursing homes, 6 (46%) of whom died over a period of 5 years. The overall 5-year mortality rate in this cohort was 44% (17/39). Of 39 patients, 33 (85%) had continued partial/good response and 5 (13%) had complete resolution of psychosis. None discontinued clozapine due to motor worsening. Among patients who responded early on, the long-term efficacy of clozapine for psychosis was sustained. The risk of nursing home placement and mortality among parkinsonian patients treated with clozapine for psychosis in this geriatric cohort was better than that reported previously. Our data are more consistent with recently published long-term outcome data suggesting an improvement in the prognosis of parkinsonian patients with psychosis with the use of atypical antipsychotic agents such as clozapine. © 2004 Movement Disorder Society

Key words: Parkinson's disease; clozapine; drug-induced psychosis; long-term efficacy

*Correspondence to: Dr. Hubert H. Fernandez, McKnight Brain Institute, Department of Neurology, University of Florida, 100 S. Newell Drive, PO Box 100236 Gainesville, FL 32610.

E-mail: fernandez@neurology.ufl.edu

Received 18 November 2002; Revised 17 June 2003, 20 November 2003; Accepted 1 December 2003

Published online 17 March 2004 in Wiley InterScience (www.interscience.wiley.com). DOI: 10.1002/mds.20051

Drug-induced psychosis is the single most important factor precipitating nursing home (NH) placement,^{1,2} an often irreversible medical and social decision³ that carries a grave prognosis.⁴ Because of the lesser potential of atypical antipsychotic drugs to worsen parkinsonism, they have taken on a central role in the management of psychosis in Parkinson's disease (PD).

To date, clozapine remains the "gold standard" atypical antipsychotic agent. Short-term studies have shown that clozapine, with a mean dose of about 25 mg/day, improved psychosis without motor worsening.^{5,6} In fact, overall motor function also improved slightly but tremor improved significantly.⁵

However, clozapine has been difficult to use because of its potential for inducing agranulocytosis. The problem is idiosyncratic, so that even the small doses used in PD do not exempt patients from this side effect.⁵

Recently, a task force that considered all peer-reviewed reports on clozapine use in PD concluded that "low-dose clozapine is efficacious in the short-term improvement of psychosis in PD with acceptable risk with specialized monitoring but there is insufficient evidence on its long-term efficacy."⁷

We present our long-term data on parkinsonian patients on chronic clozapine treatment for psychosis.

Patients and Methods

A retrospective analysis of all parkinsonian patients on long-term (≥ 24 months) clozapine treatment for psychosis at our Movement Disorders Center was carried out. Patients who were treated with clozapine for tremor or dyskinesia, and patients who discontinued clozapine before 24 months of use were not included in this study. In general, clozapine was started at 6.25 mg at bedtime and increased by 6.25 to 12.5 mg every 3 to 7 days as needed until improvement of psychosis was noted. Anti-PD medications were kept constant during the titration phase but medication adjustments were permitted at any time after the minimal effective clozapine dose was determined.

All significant side effects after 24 months of clozapine use, as noted by the patient, caregiver or clinician, were recorded. Only the baseline (before clozapine use) and latest Unified Parkinson Disease Rating Scale (UPDRS) motor and Hoehn and Yahr (H&Y) scale scores were used in the motor analysis. Nursing home (NH) placement and mortality rates were used as the endpoints.

Results

A total of 67 patients were placed on clozapine at our Movement Disorders Center over the 5-year span of this survey. Of 67 parkinsonian patients, 39 were included in this study. The remaining 28 patients were excluded because clozapine was used for nonpsychotic indications ($n = 8$) or was discontinued within 24 months due to either lack of efficacy or intolerable side effects ($n = 20$).

The cohort had a mean age of 76 years, average disease duration of 14.2 years, and mean clozapine dose of 47 mg/day for an average duration of 60 months of clozapine use.

Probable PD (defined as having at least two of three symptoms of: resting tremor, bradykinesia and rigidity; with a significant and sustained response to levodopa [L-dopa]) had been diagnosed for 79% percent, 13% had probable dementia with Lewy bodies (using the Consensus criteria⁸) and 7% had other parkinsonian syndromes. Of 39 patients, 22 (56%) were demented; 13 of 39 (33%) patients were eventually admitted to

TABLE 1. List of side effects noted with long-term clozapine use

Side effect	n (%)
Sedation	11/39 (28)
Drizzling	4/39 (10)
Dry mouth	1/39 (2)
Constipation	1/39 (2)
Urinary frequency/incontinence	1/39 (2)
Hypothermia	1/39 (2)
Confusion	1/39 (2)

The above side effects were classified as "possibly" or "probably" related to clozapine use as documented by the clinician in the patient's chart; some patients had more than one side effect.

NHs. Of the patients admitted to a NH, 6 (46%) died over a 5-year span. Overall, the 5-year mortality rate in this cohort was 44% (17/39).

Of 39 patients, 33 (85%) had continued partial/good response and 5 (13%) had complete resolution of psychosis on clozapine. There was no difference in efficacy between patients admitted to the NH and those who remained at home (NH: partial response = 11, complete = 2; community dwellers: partial response = 23, complete = 3; $\chi^2 = 0.09$; $P > 0.25$; $df = 1$). A significant worsening in the mean UPDRS-motor (39.4 vs. 45.7; $P < 0.001$) and H&Y scale (3.5 vs. 3.9; $P = 0.006$) scores was noted over 60 months but none discontinued clozapine due to motor worsening. The most common side effects reported were excessive sedation (30%) and sialorrhea (10%) (Table 1).

In the 5-year span of this survey, we are unaware of any case of death due to myocarditis. Among all 67 patients placed on clozapine over 5 years, in 2 cases clozapine treatment was suspended temporarily due to transient leukopenia. These 2 patients were not part of this cohort. There were no cases of agranulocytosis in our center.

Discussion

Although this long-term study is open and retrospective, it represents a "real world" experience and supports the continued safety and efficacy of clozapine for the treatment of psychosis over a 5-year period, for patients who respond to clozapine early on. Sedation and sialorrhea were the most common long-term side effects in this cohort.

The mild increase in UPDRS-motor scores over 5 years is probably due to disease progression rather than clozapine because none of our patients complained of significant motor worsening or discontinued clozapine due to increased parkinsonism.

One study showed that psychotic PD patients were over 13 times more at risk for NH placement compared with equally debilitated nonpsychotic patients.¹ Of those eventually admitted to the NH, 82% had hallucinations compared with only 5% among patients who remained in the community. Moreover, in a follow-up study, the 2-year mortality rate of PD residents with psychosis admitted to the NH approached 100%.⁴

In our cohort, only 33% were eventually admitted to nursing homes, of whom 44% died over a span of 5 years, a significantly improved NH placement and NH mortality rate compared with the that of the original 1995 report of Goetz and Stebbins.⁴ The NH mortality rate in this cohort is closer to that

of the more recently published longitudinal outcome of 59 PD patients enrolled in a clozapine trial for drug-induced psychosis,⁹ showing a 2-year NH mortality rate of 28%. In the latter study, the authors concluded that "it appears the prognosis (of PD patients with drug-induced psychosis) has improved with atypical antipsychotic therapy." Our data support this statement.

References

1. Goetz CG, Stebbins GT. Risk factors for nursing home placement in advanced Parkinson's disease. *Neurology* 1993;43:2227–2229.
2. Aarsland D, Larsen JP, Tandberg E, Laake K. Predictors of nursing home placement in Parkinson's disease: a population based prospective study. *J Am Geriatr Soc* 2000;48:938–942.
3. Liu K, Manton KG. The characteristics and utilization pattern of an admission cohort of nursing home patients. *Gerontologist* 1983;23:92–98.
4. Goetz CG, Stebbins G. Mortality and hallucinations in nursing home patients with advanced Parkinson's disease. *Neurology* 1995;45:669–671.
5. Parkinson Study Group. Low dose clozapine for the treatment of drug-induced psychosis in Parkinson's Disease. *N Engl J Med* 1999;340:757–763.
6. The French Clozapine Study Group. Clozapine in drug-induced psychosis in Parkinson's disease. *Lancet* 1999;353:2041–2042.
7. Goetz CG, Koller WC, Poewe W, et al. Management of Parkinson's disease: an evidence-based review. *Mov Disord* 2002;17(Suppl.):120–127.
8. McKeith IG, Fairbairn AF, Bothwell RA, Moore PB, Ferrier LN, Thompson P, Perry RH. An evaluation of the predictive validity and inter-rater reliability of clinical diagnostic criteria for senile dementia of Lewy body type. *Neurology* 1994;44:872–877.
9. Factor SA, Feustel PJ, Friedman JH, Comella CL, Goetz CG, Kurlan R, Parsa M, Pfeiffer R. Longitudinal outcome of Parkinson's disease patients with psychosis. *Neurology* 2003;60:1756–1761.

Chorea-Acanthocytosis Associated With Tourettism

Shinji Saiki, MD,^{1*} Genjiro Hirose, MD,¹
Koichiro Sakai, MD,¹ Ichiro Matsunari, MD,²
Kotaro Higashi, MD,³ Misuzu Saiki, MD,¹
Satoshi Kataoka, MD,¹ Ariyuki Hori, MD,¹
and Kohei Shimazaki, MD⁴

¹Department of Neurology, Kanazawa Medical University, Ishikawa, Japan

²The Medical and Pharmacological Research Center Foundation, Ishikawa, Japan

³Department of Radiology, Kanazawa Medical University, Ishikawa, Japan

⁴Department of Internal Medicine, Hamano-nishi Hospital, Ishikawa, Japan



Abstract: We report on a case of Chorea-acanthocytosis (ChAc) in association with Tourettism that consisted of motor and vocal tics, attention deficit–hyperactivity disorder, and obsessive–compulsive disorder in addition to the typical symptoms of ChAc. The subject was compared with his elder sister who had the same disease but milder clinical profile and neuro-radiological findings. The [¹⁸F]-2-fluoro-2-deoxyglucose positron emission tomography (FDG-PET) findings did not explain the differences in symptomatology between the patient and his sister, although they may have correlated with severity. © 2004 Movement Disorder Society

Key words: chorea-acanthocytosis; tourettism; striatal hypometabolism

Although autosomal dominant and recessive, X-linked (termed "McLeod syndrome"), and sporadic forms of chorea-acanthocytosis (ChAc) or neuroacanthocytosis have all been reported, the clinical phenotypes are very similar in all of them.¹ Recently, a novel gene (named CHAC) responsible for autosomal recessive ChAc (AR-ChAc) has been identified.^{2–4}

Typical movement disorders associated with ChAc are choreiform movements, defined as random, irregular, involuntary movements of the trunk and limbs.¹ Although patients with ChAc presenting with tourettism have been reported,^{5,6} the symptoms have not been well detailed. We present a patient with ChAc showing typical tourettism including phonic and

This article includes Supplementary Video, available online at <http://www.interscience.wiley.com/jpages/0885-3185/suppmat>

*Correspondence to: Dr. Shinji Saiki, Department of Neurology, Kanazawa Medical University, 1-1 Daigaku, Uchinada, Kahoku, Ishikawa, 920-0293, Japan.

E-mail: saibon@kanazawa-med.ac.jp

Received 7 July 2003; Revised 18 October 2003; Accepted 1 December 2003

Published online 4 March 2004 in Wiley InterScience (www.interscience.wiley.com). DOI: 10.1002/mds.20050

motor tics, along with attention deficit–hyperactivity disorder (ADHD) and obsessive–compulsive disorder (OCD).

Case Reports

Case 1

A 34-year-old man suffering involuntary movements and seizures was admitted to our service. The second child of non-consanguineous parents, his gestation, delivery, and early developmental milestones had been unremarkable. Family history was remarkable; his mother was clinically normal with no acanthocytes, but his father had choreoathetosis and was diagnosed as ChAc and died of gallbladder cancer at age 50. His paternal grandfather who died at age 62 had chorea and ballism with onset in his early 30s. Two paternal aunts (with chorea and tics) and a cousin (with choreoathetosis and ballism) were also diagnosed as ChAc, and have been reported previously.⁷ His sister (Case 2) had symptoms similar to his but milder (see below). The patient was well until age 25 years when he had his first seizure. No prior history of chorea, tics, ADHD, or OCD was noted. Thereafter, he experienced orolingual movements with self-mutilation of the lips and tongue, and soon suffered rapid involuntary movements of his upper limbs. These movements gradually affected his lower limbs, neck, and trunk. At age 31 he began to show motor tics such as clapping his hands, rotating his shoulders and body, and occasionally producing snoring sound and squeals. Although he had worked as a plumber since age 19, he lost his job because he often had difficulty sustaining attention. At age 33 he started to have difficulty in holding onto things and fell frequently. Furthermore, he began to repetitively check his wallet, make lists, and pick his nose until it bled.

Physical examination was unremarkable, except for a partial defect of the lower lip and many scratches on his extremities. Neurological examination revealed mild dementia and disturbance of recent memory. On the Mini-Mental State Examination (MMSE), he scored 24 out of 30. Speech was normal except for occasional explosive or involuntary sounds such as “Yes, yes” and “Ah, ah” together with rapid head turning and hand clapping. Word reiteration, such as “Thank you, thank you” and “What is the name of a disease? What is the name of a disease?” was frequent. He exhibited compulsive scratching the skin of the extremities. He showed frequent orolingual hyperkinesia, and had characteristics of hyperactivity manifested by fidgeting, talking excessively, and a tendency to repeat questions before answers had been completed (see Video, Segment 1). Abnormal involuntary movement scale (AIMS) score⁸ was 40 out of 42. He was diagnosed with ADHD and OCD based on the Diagnostic and Statistical Manual of Mental Disorders, except for the age of onset.^{9,10} He used a wheelchair due to back-and-forth rocking movements. Cranial nerve functions were intact. Motor power was 5 of 5, but muscle tone was markedly hypotonic in all limbs. Mild muscular atrophy of the legs was noted. His sensory examination was normal and deep tendon reflexes were hypoactive with flexor plantar responses. Neither ataxia nor dysmetria was found in finger-to-nose and heel-to-shin tests.

Hematological examination detected no abnormalities, except for a hematocrit of 37.8%. Numerous acanthocytes (10–20%) were present on a peripheral smear. Blood chemical test results were aspartate aminotransferase 48 U/l (normal values,

TABLE 1. Striatal metabolic ratio of FDG-PET

Structure	Case 1	Case 2
Caudate/cerebellum		
Right	0.477	0.585
Left	0.571	0.574
Putamen/cerebellum		
Right	0.628	0.811
Left	0.731	0.803

FDG-PET, [¹⁸F]-2-fluoro-2-deoxyglucose positron emission tomography.

11–34), alanine aminotransferase 35 U/l (normal, 4–37), lactate dehydrogenase 485 U/l (normal, 132–248), creatine kinase 1,179 U/l (normal, 47–212), and aldolase 11.0 U/l (normal, 1.8–6.1). Urinalysis, serum electrolytes, very low-density and low-density serum lipoprotein, and serum ceruloplasmin were all within normal ranges. Chest and skull radiographs and an electrocardiogram were unremarkable. Cell counts, protein, and sugar in the cerebrospinal fluid were all within normal limits. Nerve conduction velocity studies showed inexcitability of the left peroneal nerve, but the rest of the nerves had normal velocities. Left biceps brachii muscle biopsy showed variable fiber diameters. Electroencephalography was normal. Brain magnetic resonance imaging (MRI) detected marked atrophy of the bilateral striatum (Fig. 1A). [¹⁸F]-2-fluoro-2-deoxyglucose positron emission tomography (FDG-PET) scans showed marked hypometabolism of the striatum and mild hypometabolism of the frontal cortex (Fig. 1B). The ratios of caudate to cerebellum and of putamen to cerebellum indicate that the patient also had decreased metabolism in the basal ganglia, similar to that of his sister (Case 2), but the degree of his hypometabolism was much more severe (Table 1). Furthermore, we detected a novel single heterozygous mutation of the CHAC gene in both.⁷

He was treated with oral haloperidol (2.25 mg/day) and showed marked amelioration of his involuntary movements and tourettism over a 6-month period. His AIMS score decreased to 27 of 42.

Case 2

The elder sister of the proband developed involuntary movements (see Video, Segment 2) (orofacial dyskinesia, jerking of the head, and chorea in the extremities) at age 35. One year later, she also had phonic and motor tics, but not ADHD or OCD. She showed orofacial dyskinesia and choreic movements of the extremities. Her AIMS score was 15 of 42. No amyotrophy was noted. On both direct smears and wet preparations, 10 to 15% of erythrocytes were acanthocytes. Brain MRI revealed atrophy of the striatum; atrophy of the bilateral striatum was almost equal to Case 1. FDG-PET scans showed marked hypometabolism of the striatum (Table 1) and mild hypometabolism of the frontal cortex.

Discussion

We diagnosed both siblings as ChAc based on clinical symptoms, family history, and gene abnormalities. A diagnosis of Tourette syndrome (TS) should be based on a patient's history and whether there are motor or phonic tics, the presence of coexisting behavioral disorders, such as ADHD and OCD, and

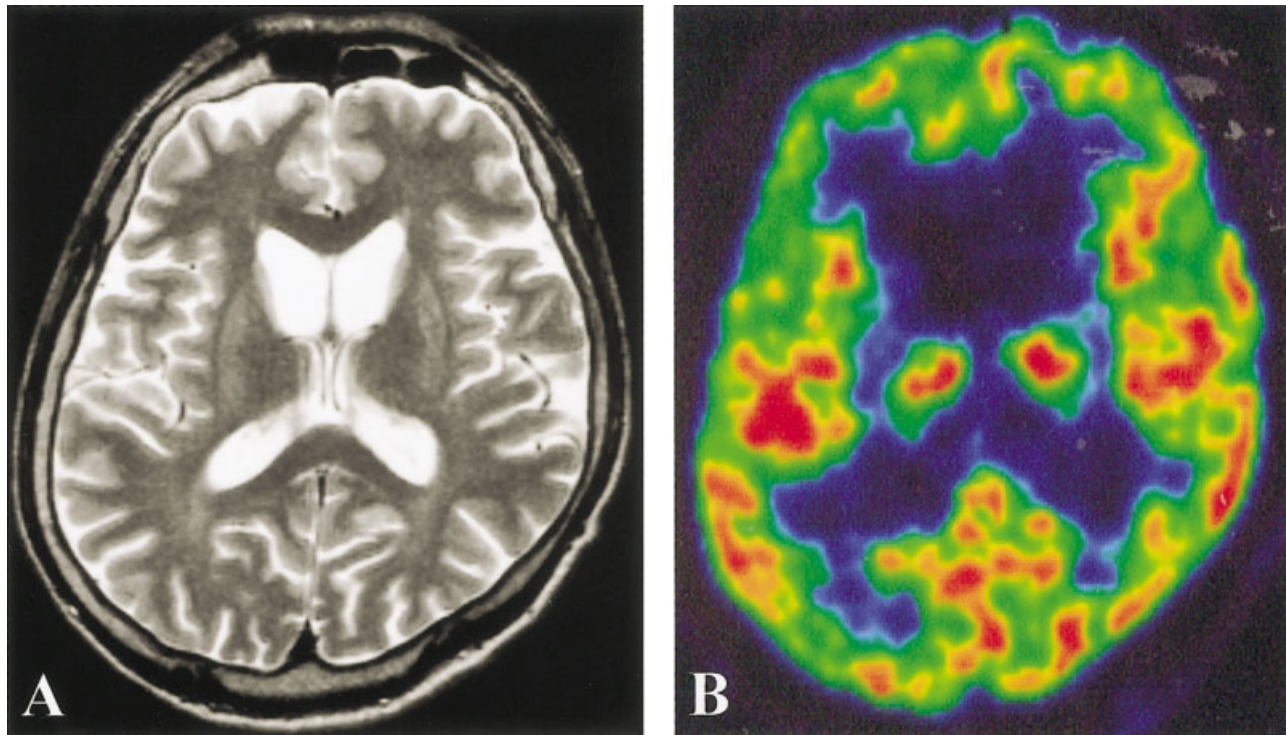


FIG. 1. Brain MRI showing striatal atrophy and FDG-PET showing hypometabolism. **A:** Brain T2-weighted MR (1.5 T, TR/TE = 4500/9.6) image showing marked atrophy of the bilateral caudate nucleus and heterogeneous intensity of the bilateral putamen. **B:** FDG-PET study showing marked hypometabolism of the bilateral caudate, putamen, and frontal cortices.

any family history of similar symptoms.¹¹ The term “touretism” has been used to describe TS-like symptoms secondary to some specific cause.¹² Our patient had motor and vocal tics associated with meaningless echolalia but without coprolalia, similar to reported findings.^{5,6} He also displayed typical ADHD and OCD symptoms. He is not likely to have been coincidentally suffering from ChAc and idiopathic TS, because of the unusual age of onset and the negative family history of TS and related symptoms. The patient did not present initially with touretism, but it was a later manifestation of his ChAc.

FDG-PET investigations in ChAc patients have shown reductions in glucose metabolism in caudate, putamen, and frontal cortex.^{13,14} Dubinsky and colleagues¹⁴ reported that clinical severity was correlated with the decrease in the basal ganglial metabolism in 2 siblings with ChAc; our FDG-PET results concur.

Based on findings of various biochemical, neuroimaging, neurophysiological, and genetic studies, TS is now considered an inherited, developmental disorder of synaptic neurotransmission that results in disinhibition of the cortico-striato-thalamo-cortical circuitry.¹⁵ Although many studies using FDG-PET have shown hypometabolism of the basal ganglia in TS, it remains unclear whether frontal hypometabolism is associated with the pathomechanism of TS or not.¹⁵ Chase and associates¹⁶ found an inverse correlation between severity of tics (both vocal and motor) and glucose utilization rates in the frontal, cingulate and insular cortices, and in the inferior corpus striatum in TS. The FDG-PET findings in our study do not explain the difference in symptomatology between the patient and his sister, although they may correlate with severity.

Although the proband’s clinical symptoms were typical of chorea and touretism, his sister, who suffered from the same disease and shared the same gene mutation, had milder motor tics; differing clinical features have already been observed in this family.⁷ Although it is unclear whether such variable clinical presentations are the result of genetic heterogeneity or clinical variability, we speculate that clinical variability is not the result of genetic heterogeneity at the major locus, but may reflect other epigenetic interactions, contributing environmental factors, or both.

Legend to the Video

Segment 1. The patient (Case 1) has rapid, jerky movements of the neck, trunk, and extremities. Occasional finger and hand movements and facial grimacing also occur. During conversation, he occasionally repeats the same phrases, such as “Thank you” and “What did you say?” He is not able to sit on the bed quietly because of his hyperactivity. He blurts out a repetitive question, “What is the name of a disease?”

Segment 2. The patient (Case 2) shows random jerky movements and extension of the lower extremities and orofacial dyskinesia.

References

1. Rampoldi L, Danek A, Monaco AP. Clinical features and molecular bases of neuroacanthocytosis. *J Mol Med* 2002;80:475–491.
2. Rampoldi L, Dobson-Stone C, Rubio LP, et al. A conserved sorting-associated protein is mutant in chorea-acanthocytosis. *Nat Genet* 2001;28:119–120.

3. Ueno S, Maruki Y, Nakamura M, et al. The gene encoding a newly discovered protein, chorein, is mutated in chorea-acanthocytosis. *Nature Genet* 2001;28:121–122.
4. Dobson-Stone C, Danek A, Rampoldi L, et al. Mutational spectrum of the CHAC gene in patients with chorea-acanthocytosis. *Eur J Hum Genet* 2002;10:773–781.
5. Spitz MC, Jankovic J, Killian JM. Familial tic disorder, parkinsonism, motor neuron disease, and acanthocytosis: a new syndrome. *Neurology* 1985;35:366–370.
6. Kito S, Itoga E, Hiroshige Y, Matsumoto N, Miwa S. A pedigree of amyotrophic chorea with acanthocytosis. *Arch Neurol* 1980;37:514–517.
7. Saiki S, Sakai K, Kitagawa Y, Saiki M, Kataoka S, Hirose G. Mutation in the CHAC gene in a family of autosomal dominant chorea-acanthocytosis. *Neurology* 2003;61:1614–1616.
8. Guy, W. ECDEU assessment manual for psychopharmacology. DHEW publication, No. 76–338. Washington, DC: U.S. Government Printing Office; 1976. p 534–537.
9. American Psychiatric Association. Diagnostic and statistical manual of mental disorders. DSM-IV, 4th ed. Washington, DC: American Psychiatric Association; 1994. p 85–93.
10. American Psychiatric Association. Diagnostic and statistical manual of mental disorders. DSM-IV, 4th ed. Washington, DC: American Psychiatric Association; 1994. p 456–463.
11. Jankovic J. Tourette's syndrome. *N Engl J Med* 2001;345:1184–1192.
12. Sacks OW. Acquired tourettism in adult life. *Adv Neurol* 1982;35:89–92.
13. Tanaka M, Hirai S, Kondo S, et al. Cerebral hypoperfusion and hypometabolism with altered striatal signal intensity in chorea-acanthocytosis: a combined PET and MRI study. *Mov Disord* 1998;13:100–107.
14. Dubinsky RM, Hallett M, Levey R, Chiro GD. Regional brain glucose metabolism in neuroacanthocytosis. *Neurology* 1989;39:1253–1255.
15. Peterson BS. Neuroimaging studies of Tourette syndrome: a decade of progress. *Adv Neurol* 2001;85:179–196.
16. Chase TN, Geoffrey V, Gillespie M, Burrows GH. Structural and functional studies of Gilles de la Tourette syndrome. *Rev Neurol* 1986;142:851–855.

Vascular Hemichorea/Hemiballism and Topiramate

Emilia Mabel Gatto, MD,* Claudia Uribe Roca, MD,
Gabriela Raina, MD, Marcelo Gorja, MD, Silvia Folgar, MD,
and Federico E. Micheli, MD

*Parkinson's Disease and Movement Disorders Program,
Department of Neurosciences, Hospital de Clínicas,
University of Buenos Aires, Buenos Aires, Argentina*



Abstract: Although vascular hemichorea/hemiballism (HC/HB) has been reported to be self-limited, in some cases, it can be irreversible and severely disabling. The standard treatment includes typical and atypical neuroleptics and GABA-mimetic drugs. Topiramate is a new antiepileptic drug possessing a complex mechanism of action, including the enhancement of GABA-mediated inhibition. We describe a 71-year-old patient with HC/HB who markedly improved after topiramate treatment. © 2004 Movement Disorder Society

Key words: hemichorea; hemiballism; topiramate

Hemichorea (HC) features random and fast jerking, involuntary movements of the limbs that mimic a dance confined to one side of the body. When movements are wider and more violent with prominent involvement of proximal muscles, it is termed hemiballism (HB).¹ These two clinical syndromes are currently considered a continuum rather than two different entities, leading Kase and colleagues to propose the name hemichorea/hemiballism (HC/HB) as a combination of both.² The most frequent etiology in adults is an acute cerebrovascular accident, usually located in the contralateral basal ganglia.³ Although spontaneous recovery usually occurs, in some cases HC/HB can be disabling and irreversible.³ Typical high-potency neuroleptics, such as haloperidol, perphenazine, as well as other antidopaminergic drugs, are the medication of first choice.⁴ As HC/HB is more frequent in the elderly, a population particularly prone to develop parkinsonism and tardive dyskinesia on neuroleptic therapy, it appears reasonable to test new therapeutic strategies. Over the past few years, various anticonvulsants that increase γ -aminobutyric acid (GABA)-ergic transmission (valproate,⁵ gabapentin⁶) have been reported to be useful in the management of isolated HC/HB cases. Topiramate (TPM) is a new antiepileptic drug with several pharmacological actions, including GABA activity enhancement.⁷ Here, we report on a

This article includes Supplementary Video, available online at <http://interscience.wiley.com/jpages/0885-3185/suppmat>

*Correspondence to: Emilia M. Gatto, Juramento 1155, 3°A, Capital Federal, Buenos Aires, 1428 Argentina.

E-mail: emiliagatto@fibertel.com.ar

Received 20 May 2003; Revised 13 September 2003; Accepted 5 December 2003

Published online 4 March 2004 in Wiley InterScience (www.interscience.wiley.com). DOI: 10.1002/mds.20086

71-year-old man who developed a vascular HC/HB effectively treated with low doses of TPM.

Case Report

A 71-year-old man consulted at our department in May 2001 complaining of paresthesias involving his left arm followed by the sudden appearance of abnormal and continuous movements involving his left hemibody. His medical history included chronic motor tics involving his left facial muscles since the age of 15 and a peripheral by-pass surgery. The patient had initially been evaluated at another center where he was started on haloperidol 5 mg/day for only 3 days, followed by olanzapine 15 mg/day for another 4 days. No optimal doses were achieved in either case because the patient reported subjective worsening of the symptoms after haloperidol intake and somnolence with olanzapine. However, no medical records were available to confirm this situation. These drugs, therefore, were discontinued. Low-dose clonazepam (1 mg/day) was initiated, with poor control of involuntary movements but with improvement of anxiety symptoms. Three months later, he was admitted to our center for a complete diagnostic evaluation. Neurological examination revealed an oriented patient with choreic and sporadic ballistic movements affecting the left arm and leg, without evidence of motor deficit. He presented mild hypoaesthesia localized in his left hand with ipsilateral dysidiadochokinesia. Saccadic ocular movements were normal. He had mild dysarthria, and normal muscle tone and deep tendon reflexes. Laboratory findings were normal, including glycemia and thyroid function tests. A brain magnetic resonance imaging (MRI) scan disclosed multiple hyperintense signals in T₂-weighted sequence located in the deep white matter and basal ganglia. Doppler ultrasonography of cervical arteries and a cerebral MR angiography demonstrated severe stenosis of the right internal carotid artery. He was still on clonazepam 1 mg/day (see Video, Segment 1). Because the patient refused to reinstitute haloperidol or any other neuroleptic drug, a GABAergic agonist drug, TPM, was started at 25 mg/day and titrated weekly to obtain the maximal benefit on HC/HB or the appearance of intolerance, to a maximum of 400 mg/day. TPM doses were increased by 25 mg per week, with improvement of HC/HB from the very first week. Forty-eight hours after TPM 50 mg/day, involuntary movements markedly diminished (see Video, Segment 2). The following week, upon reaching doses of 75 mg/day, choreic movements were sporadic and mild in intensity, enough so that he was able to perform fine motor tasks as threading a needle. He simultaneously noticed irritability and reappearance of anxiety, but these side effects disappeared when he returned to 50 mg/day. The patient remained with good control of HC/HB symptoms for 2 months. To evaluate whether improvement of HC/HB had been due to the spontaneous recovery of his disease, or if it had been associated to the pharmacological intervention, TPM was gradually withdrawn over 5 days. Twenty-four hours after the drug was withdrawn, mild but persistent left HC/HB was evident. A second clinical evaluation performed 13 days after TPM withdrawal showed significant worsening of his HC/HB syndrome. TPM was reinstituted and an objective clinical improvement was achieved again 24 to 48 hours once TPM was restarted on 50 mg/day. However, although he reached doses of 50 mg/day, this time he failed to improve to the level he had experienced during the first course of treatment with TPM (see Video, Segment 3). A second attempt to diminish TPM dose 1 month later led to a

recurrence and exacerbation of his symptoms. To date, he is still on TPM 50 mg/day, with partial control of the HC/HB. In the follow-up, a right carotid endarterectomy was performed but the involuntary movements remained unchanged.

Discussion

Our patient presented an HC/HB syndrome secondary to a probable vascular etiology. This theory was supported by the acute onset of symptoms and evidence of peripheral and cerebral vascular disease. Although brain MRI failed to disclose any acute infarction, this is not an infrequent situation found in vascular choreas.⁸ Indeed, recent reports show that, in over 20% of cases, such lesions are not detected by conventional neuroimaging techniques.⁹

Although the pathophysiology of HC/HB remains controversial, it has been postulated that the hyperkinetic disorder is caused by decreased GABAergic transmission in the indirect basal ganglion pathway.^{10,11} In agreement with this hypothesis, experimental models of HC have been produced by injection of a GABA antagonist drug into the external segment of the globus pallidus or subthalamic nucleus.¹² In the past few years, human single photon emission computed tomographic studies^{12,13} have revealed increased blood flow in the thalamus contralateral to the choreic movements after ischemic stroke compromising the basal ganglia, which might reflect enhanced thalamic neuronal activity, free from inhibitory pallidal control.¹²

Consistent with the lack of GABA transmission in HC/HB, it seems reasonable to use drugs that increase GABAergic neurotransmission. TPM has been proven to enhance GABA activity⁷ and to be effective in the control of other movement disorders such as essential tremor.^{14,15} We therefore decided in the present case to explore the potential benefits of this drug in the management of HC/HB in a patient who initially refused to reinstitute neuroleptic therapy. Low doses of TPM (50 mg/day) were initially well tolerated and markedly reduced HC/HB, although the best clinical response was transient. Although vascular HC/HB may spontaneously resolve,¹⁶ in our patient, the worsening of symptoms within 24 hours after TPM was withdrawn and the control of hyperkinetic movements after re-initiation provide strong evidence of TPM efficacy.

On the other hand, there is no clear explanation for the reduction in efficacy after re-introduction of TPM. Unfortunately, high doses could not be tested because of the development of irritability and increased anxiety with 75 mg/day. TPM side effects include weight loss, paresthesias, memory problems, and neurotoxic effects (ataxia, impaired concentration, confusion, dizziness, and somnolence). These side effects may be due to the rate of titration or dose-related, as seems to have occurred in our patient, who developed anxiety and irritability that disappeared after diminishing the daily dose of TPM.¹⁷

Although the report of a single case remains essentially anecdotal, we believe that it would be useful to explore the potential benefits of TPM in the management of HC/HB, given the theoretical bases that support its use in the treatment of this entity. Our findings need to be corroborated by well-designed trials to allow therapeutically valid recommendations.

Acknowledgment: The authors state that there is no financial relationship with pharmaceutical companies.

Legends to the Video

Segment 1. Baseline on clonazepam 1 mg/day.

Segment 2. Marked improvement can be observed when the patient received 1 mg/day of clonazepam and TPM 50 mg/day.

Segment 3. Choreic movements after 6 months. TPM 50 mg/day and clonazepam 1 mg/day.

References

- Lang AE. Movement disorder symptomatology. In: Bradley WG, Daroff RB, Fenichel GM, Marsden CD, editors. *Neurology in clinical practice*. Boston: Butterworth-Heinemann; 1996. p 299–320.
- Kase CS, Maulsby GO, De Juan E, Mohr JP. Hemichorea-hemiballism and lacunar infarction in the basal ganglia. *Neurology* 1981;31:452–455.
- Dewey RB, Jankovich J. Hemiballism-hemichorea: clinical and pharmacological findings in 21 patients. *Arch Neurol* 1989;46:862–867.
- Johnson WG, Fahn S. Treatment of vascular hemiballism and hemichorea. *Neurology* 1977;27:634–636.
- Sethi KD, Patel BP. Inconsistent response to divalproex sodium in hemichorea/ hemiballism. *Neurology* 1990;40:1630–1631.
- Kothare SV, Pollack P, Kulberg AG, Ravin PD. Gabapentin treatment in a child with delayed-onset hemichorea/ hemiballismus. *Pediatr Neurol* 2000;22:68–71.
- Shank RP, Gardocki JF, Streeter AJ, Maryanoff BE. An overview of the preclinical aspects of topiramate: pharmacology, pharmacokinetics, and mechanism of action. *Epilepsia* 2000;41(Suppl. 1):S3–S9.
- Piccolo I, Defanti CA, Soliveri P, Volonté MA, Cislighi G, Girotti F. Cause and course in a series of patients with sporadic chorea. *J Neurol* 2003;250:429–435.
- Galian R, Juni J, Castillo A, Parra J, Peiro C, Sancho J. Vascular hemichorea: clinical-radiological correlation. *Rev Neurol* 2000;30:409–411.
- Hashimoto T, Morita H, Tada T, Maruyama T, Yamada Y, Ikeda S. Neuronal activity in the globus pallidus in chorea caused by striatal lacunar infarction. *Ann Neurol* 2001;50:528–531.
- De Long MR. Primate models of movement disorders of basal ganglia origin. *Trends Neurosci* 1990;40:281–285.
- Kim JS, Lee KS, Kim YI, Kim BS, Chung YA, Chung SK. Evidence of thalamic disinhibition in patients with hemichorea: semiquantitative analysis using SPECT. *J Neurol Neurosurg Psychiatry* 2002;72:329–333.
- Pantano P, DiCesare S, Ricci M, Gualdi GF, Sabatini U, Di Piero V. Hemichorea after a striatal ischemic lesion: evidence of thalamic disinhibition using a single-photon emission computed tomography: a case report. *Mov Disord* 1996;11:444–447.
- Connor GS. A double-blind placebo-controlled trial of topiramate treatment for essential tremor. *Neurology* 2002;59:132–134.
- Connor GS. Topiramate as a novel treatment for essential tremor. *Mov Disord* 1999;14:908.
- Ghika-Schmid F, Ghika J, Regli F, Bogousslavsky J. Hyperkinetic movement disorders during and after acute stroke: the Lausanne Stroke Registry. *J Neurol Sci* 1997;146:109–116.
- Glaser TA. Topiramate. *Epilepsia* 1999;40:985–991.

Mistaken Diagnosis of Psychogenic Gait Disorder in a Man With Status Cataplecticus (“Limp Man Syndrome”)

David K. Simon, MD, PhD,^{1*} Seiji Nishino, MD, PhD,² and Thomas E. Scammell, MD¹

¹*Beth Israel Deaconess Medical Center and Harvard Medical School, Department of Neurology, Boston, Massachusetts, USA*

²*Center for Narcolepsy, Stanford University, Palo Alto, California, USA*



Abstract: We report on a 45-year-old man with a history of multiple psychiatric admissions for a gait disorder and episodic weakness thought to be psychogenic who was subsequently diagnosed with status cataplecticus due to narcolepsy. The gait difficulties resolved with venlafaxine. This case demonstrates that status cataplecticus can be misdiagnosed as a psychogenic gait disorder. © 2004 Movement Disorder Society

Key words: cataplexy; narcolepsy; hypocretin

Psychogenic gait disorders can be extremely challenging to diagnose. Clinical features often include exaggerated effort, extreme slowness, fluctuations, and bizarre gait with “unecologic postures.”^{1–3} The diagnosis also is supported by a lack of objective findings such as abnormal deep tendon reflexes or tone. Here, we report a patient with features suggestive of a psychogenic gait disorder that was actually caused by continuous cataplexy, or “limp man syndrome.”

Case Report

A 45-year-old man presented to the neurology clinic for variable weakness, sleepiness, and visual hallucinations. Four months earlier, he developed excessive sleepiness, especially when sedentary, although he fell asleep once during public speaking. Within a few weeks, he also began to have episodes of sudden left leg weakness lasting approximately 1 minute and occurring several times each day. In subsequent weeks, the weakness spread to involve all extremities as well as the face, neck, and voice. The duration of the episodes increased, ranging from a few minutes to several hours. A few weeks later, he complained of visual hallucinations such as birds flying at his face or thugs trying to attack him. Areflexia was noted on

This article includes Supplementary Video, available online at <http://www.interscience.wiley.com/jpages/0885-3185/suppmat>

*Correspondence to: Dr. David K. Simon, Beth Israel Deaconess Medical Center and Harvard Medical School, Department of Neurology, 77 Avenue Louis Pasteur, Room HIM-856; Boston, MA 02115. E-mail: dsimon1@bidmc.harvard.edu

Received 27 August 2003; Revised 16 November 2003; Accepted 16 December 2003

Published online 16 March 2004 in Wiley InterScience (www.interscience.wiley.com). DOI: 10.1002/mds.20078

records from that time period. There was no family history of neurological, psychiatric, or sleep disorders. Neuropsychiatric testing revealed variably poor attention. A routine electroencephalogram was read as normal. Magnetic resonance imaging of the brain with and without gadolinium and of the entire spine (without gadolinium) were reported to be normal. Nerve conduction studies with electromyography showed only equivocal findings on repetitive stimulation. A trial of pyridostigmine bromide produced no clinical benefits. Computed tomography of the chest was normal and acetylcholine receptor antibodies were absent. He was diagnosed with a conversion reaction, leading to two hospitalizations on a psychiatric service. He was not medicated for these symptoms.

Additional history obtained at presentation indicated that many of the episodes of weakness were triggered by strong emotions such as excitement, anger, or laughter. He experienced weakness most of the time, with occasional periods of normal power lasting up to 30 minutes. He had a history of chronic daytime sleepiness over the past 4 months with frequent brief naps during the daytime associated with vivid dreams and visual hallucinations. He reported frequent awakenings at night and his girlfriend noticed occasional apneic episodes.

On examination, he was noted to be mildly overweight. He was variably alert and attentive but for most of the examination was observed to have slow and rambling speech. At these times, he displayed ptosis, neck extensor weakness, and dysarthria. He remained awake and was able to talk but reported difficulty moving his arms. At these times, he had diffuse weakness with hypotonia and antigravity strength in all extremities. Deep tendon reflexes were absent, but vibration and temperature sensation were normal. His gait was variably ataxic with a stooped posture and a tendency to keep his mouth open with tongue protruded. Further description of the gait is provided in the legend to the videotape (see Video, Segment 1).

A polysomnogram revealed moderately reduced sleep efficiency with 50 awakenings, a slight increase in stage 1 sleep, a normal rapid eye movement (REM) latency, and rapid eye movements and atonia intruding into non-REM sleep. Mild to moderate obstructive sleep apnea and periodic limb movements of sleep were also present. The Multiple Sleep Latency Test (MSLT) revealed an average sleep latency of 0.3 minutes and sleep-onset REM periods in three of five naps. Genetic studies indicated that he was positive for HLA DQB1*0602. Cerebrospinal fluid analyses revealed a mildly elevated protein and undetectable levels of orexin/hypocretin. Based on these results, he was diagnosed with narcolepsy with cataplexy. He was started on venlafaxine with subsequent resolution of his episodes of weakness (see Video, Segment 2).

Discussion

Recognition of a movement disorder as a conversion reaction can help prevent unnecessary and potentially harmful testing and therapeutic trials. On the other hand, significant harm can result from the inaccurate diagnosis of a physical disorder as psychogenic. Avoiding such an error can be difficult due to overlapping features of psychogenic disorders and "organic" movement disorders.¹⁻³ Furthermore, psychogenic movements can occur in the setting of a preexisting organic disorder, further complicating the diagnosis.⁴ The patient presented here had an unusual gait disorder associated with episodes of weakness and visual hallucinations. Several features were suggestive

of a psychogenic disorder, including the variable and staggering nature of the gait along with episodes of sudden buckling of the knees without falls. The absence of objective abnormalities on neurological examination (except for areflexia) and multiple negative imaging and electrophysiological studies further raised suspicion of a psychogenic disorder, resulting in psychiatric hospitalizations. His excessive daytime sleepiness was not seriously evaluated during initial investigations. Once the diagnosis of narcolepsy with cataplexy was considered, appropriate diagnostic tests were performed and effective therapy was initiated.

Although the patient also suffered from obstructive sleep apnea, other findings indicated a diagnosis of narcolepsy with cataplexy. He had excessive daytime sleepiness, episodes of weakness with hypotonia, and an extremely short sleep latency on the MSLT with three sleep-onset REM periods. The undetectably low levels of orexin/hypocretin in the cerebrospinal fluid (CSF) also are supportive of this diagnosis.⁵⁻⁷ There is considerable evidence that orexin/hypocretin promotes wakefulness,⁸ and the vast majority of patients with narcolepsy plus cataplexy lack detectable orexin/hypocretin in the CSF.⁶

Although rare, cases of "status cataplecticus" have been reported previously. Guilleminault and colleagues described a patient with frequent attacks of complete cataplexy that they referred to as "status cataplecticus."⁹ Stahl and coworkers reported a patient with a brainstem glioblastoma presenting with hundreds of partial cataplectic attacks each day, at a rate of one every few seconds, associated with a peculiar variation of posture and tone. This patient's gait was described as resembling a puppet on strings with periods of a sagging face, limp arms, and buckling knees. The authors referred to this continuous fluctuating partial cataplexy as "limp man syndrome."¹⁰ As in the case presented here, the marked variations in muscle strength and abnormal movements of the patient described by Stahl and colleagues initially led to the incorrect diagnosis of a psychogenic disorder. Additional patients have been reported with status cataplecticus after initiating treatment with prazosin¹¹ or after abrupt withdrawal of clomipramine.¹² Thus, status cataplecticus (limp man syndrome) should be considered in the differential diagnosis of a psychogenic gait disorder, particularly in patients with excessive daytime sleepiness.

Legends to the Video

Segment 1. The patient before initiation of treatment. Ptosis, head drop, limp arms, and fluctuating dysarthria are apparent. Gait is variably wide-based with sudden staggering to either side. There are moments of buckling at the knees without falling.

Segment 2. The patient with normal speech and gait after initiation of venlafaxine.

Acknowledgment: We thank the patient for generously allowing presentation of the video accompanying this report.

References

1. Miyasaki JM, Sa DS, Galvez-Jimenez N, Lang AE. Psychogenic movement disorders. *Can J Neurol Sci* 2003;30(Suppl. 1):S94-S100.
2. Hayes MW, Graham S, Heldorf P, de Moore G, Morris JGL. A video review of the diagnosis of psychogenic gait: appendix and commentary. *Mov Disord* 1999;14:914-921.

3. Lempert T, Brandt T, Dieterich M, Huppert D. How to identify psychogenic disorders of stance and gait: a video study in 37 patients. *Acta Neurol Scand* 1991;82:335–340.
4. Ranaway R, Riley D, Lang A. Psychogenic dyskinesias in patients with organic movement disorders. *Mov Disord* 1990;5:127–133.
5. Nishino S, Ripley B, Overeem S, Lammers GJ, Mignot E. Hypocretin (orexin) deficiency in human narcolepsy. *Lancet* 2000;355:39–40.
6. Mignot E, Lammers GJ, Ripley B, et al. The role of cerebrospinal fluid hypocretin measurement in the diagnosis of narcolepsy and other hypersomnias. *Arch Neurol* 2002;59:1553–1562.
7. Kanbayashi T, Inoue Y, Chiba S, et al. CSF hypocretin-1 (orexin-A) concentrations in narcolepsy with and without cataplexy and idiopathic hypersomnia. *J Sleep Res* 2002;11:91–93.
8. Scammell TE. The neurobiology, diagnosis, and treatment of narcolepsy. *Ann Neurol* 2003;53:154–166.
9. Guilleminault C, Wilson RA, Dement WC. A study on cataplexy. *Arch Neurol* 1974;31:255–261.
10. Sahl SM, Layzer RB, Aminoff MJ, Townsend JJ, Feldon S. Continuous cataplexy in a patient with a midbrain tumor: the limp man syndrome. *Neurology* 1980;30:1115–1118.
11. Aldrich MS, Rogers AE. Exacerbation of human cataplexy by prazosin. *Sleep* 1989;12:254–256.
12. Martinez-Rodriguez J, Iranzo A, Santamaria J, et al. Status catalepticus induced by abrupt withdrawal of clomipramine. *Neurologia* 2002;17:113–116.

Amphetamine-Induced Chorea in Attention Deficit–Hyperactivity Disorder

John C. Morgan, MD, PhD,^{1*} W. Christopher Winter, MD,² and G. Frederick Wooten, MD²

¹*Medical College of Georgia, Department of Neurology, Augusta, Georgia, USA*

²*University of Virginia, Department of Neurology, Charlottesville, Virginia, USA*

Abstract: Attention deficit–hyperactivity disorder (ADHD) is treated frequently with stimulants in both children and adults. While tics are occasional complications of stimulant therapy, chorea is reported rarely. We describe an adult ADHD patient who developed chorea upon dose escalation of mixed amphetamine salts, which resolved on discontinuation of the drug. © 2004 Movement Disorder Society

Key words: ADHD; chorea; amphetamine

Attention deficit–hyperactivity disorder (ADHD) is commonly diagnosed in children and may persist into adolescence and adulthood in 40 to 60% of patients.^{1,2} Stimulants remain the primary pharmacotherapy for ADHD in both children and

adults.^{3,4} Methylphenidate, pemoline, and amphetamine derivatives (frequently in extended-release preparations) are the mainstays of therapy.⁴ Tics are the most common dyskinesia reported in ADHD treatment with these drugs, although it remains controversial as to how often stimulants “cause” a tic disorder.^{5–9} There is perhaps more evidence that stimulants may worsen a preexisting tic disorder, as reported with cocaine.^{10,11} Contrary to this line of thought, the Tourette’s Syndrome Study Group has demonstrated recently a *decrease* in tic severity in children with tics and ADHD who were treated with methylphenidate.⁹

While amphetamine-induced chorea has been reported in the setting of acute¹² or chronic abuse/addiction,^{5,13,14} it has been reported only rarely in the setting of therapeutic uses for the drug. In fact, a PubMed search of the English language literature yielded only one report of amphetamine-induced chorea in the treatment of an adult: a woman taking an amphetamine precursor for weight loss.¹⁵ We report on a man who developed chorea temporally related to an increased dose of his ADHD medication, mixed amphetamine salts (MAS).

Case Report

A 22-year-old man was diagnosed with ADHD at age 8. He was treated with methylphenidate with adequate response for 14 years until 1 month before admission when he noted difficulty focusing and concentrating on his college class work. At that time, he was switched from methylphenidate 20 mg t.i.d. to MAS 20 mg b.i.d. He continued to have difficulty focusing on tasks, and his dose was eventually escalated to 45 mg t.i.d. over several weeks with improvement in his ADHD symptoms. Five days after increasing his dose from 30 mg t.i.d. to 45 mg t.i.d., he awoke feeling nauseous. He was agitated, talking constantly, and had adventitious movements of his face, trunk, and extremities noted by his roommate of which the patient was unaware. There was no evidence of “punding” behavior, a behavior where amphetamine users get “hung-up” repeating various tasks for lengthy periods of time.¹⁶ He denied taking more MAS than were prescribed and denied illicit drug use. He had no prior history of tics, chorea, or other movement disorders. He had no prior diagnosis of bipolar disorder, conversion disorders, or malingering. There was no recent history of a streptococcal infection, and he had never taken neuroleptics. He had no history of connective tissue disease. He was also on escitalopram (10 mg, stable dose) to treat anxiety and depression for 2 months before any changes in his ADHD medications. There was no family history of chorea or other movement disorders.

On initial examination, he was afebrile with a pulse of 120 and normal blood pressure. He was alert and oriented and talked constantly with normal content. His cranial nerve examination was normal. He had normal power with continuous choreic movements of his upper and lower face, trunk, and all extremities that were involuntary and not suppressible. He did not manifest motor or vocal tics, and there was no evidence of “punding” behavior. His movements ceased while sleeping. Sensory examination, coordination, and reflexes were normal except for evidence of a fine postural tremor in outstretched arms.

Laboratory values demonstrated a normal complete blood count and blood chemistries except for a slightly elevated aspartate aminotransferase at 40 units/L (normal, 13–39 units/L), elevated total bilirubin at 2.1 mg/dl (normal, 0.3–1.0 mg/

*Correspondence to: Dr. John C. Morgan, Medical College of Georgia, Department of Neurology, 1429 Harper Street, HF-1121A, Augusta, GA 30912. E-mail: jmorgan@mail.mcg.edu

Received 17 April 2003; Revised 8 September 2003; Accepted 16 December 2003

Published online 4 March 2004 in Wiley InterScience (www.interscience.wiley.com). DOI: 10.1002/mds.20081

dl), and an elevated creatine kinase at 780 units/L (normal, 55–170 units/L). Antinuclear antibody was negative. A urine toxicology screen was positive for amphetamines (27,057 ng/mL confirmed by gas chromatography–mass spectrometry) and negative for cocaine and other drugs of abuse. A head computed tomography scan without contrast was normal.

Before our evaluation, he was treated initially with intravenous diphenhydramine (25 mg) for agitation and subsequently with both intravenous lorazepam (3 mg) and diazepam (10 mg) without improvement in his choreic movements. The MAS were discontinued at presentation, and his chorea gradually improved with only occasional truncal choreic movements noted 2 days after admission. Three days after admission, his movements had abated, although he remained agitated and excessively talkative. He returned to his normal baseline mental status within 4 days after stopping the drug and remained on escitalopram as his chorea resolved. His aspartate aminotransferase, total bilirubin, and creatine kinase levels normalized within 2 days after admission. The day after discharge, he was reinitiated on methylphenidate at 40 mg t.i.d. with moderate improvement in his ADHD symptoms and without recurrence of chorea or other movement disorders.

Discussion

Prinzmetal and Bloomberg introduced amphetamines to treat narcolepsy in 1935.¹⁷ Since that time, amphetamines have been used extensively in the treatment of several other conditions, including obesity¹⁸ and ADHD.^{3,4} Movement disorders induced by amphetamines are extremely rare in these therapeutic settings, despite considerable exposure to numerically significant patient populations. In fact, a National Library of Medicine (PubMed) search identified only one report of amphetamine-induced chorea when an amphetamine precursor (clobenzorex) was used as an anorectic.¹⁵

Our patient's history is compelling for an association of his chorea with the escalation of his MAS dose since he was on a stable daily dose of escitalopram for 2 months. Mattson and Calverley reported an 8-year-old boy with a learning disability who had worsening of preexisting choreoathetosis in the upper extremities when he was treated with 5 mg of dextroamphetamine for hyperactivity.¹⁹ This choreoathetosis recurred on rechallenge at the same dose and immediately resolved when the patient was treated with 25 mg of diphenhydramine.¹⁹ Mattson and Calverley also reported a 3-year-old girl with a history of focal-onset seizures who developed choreoathetosis of the arms and legs after ingesting 5 mg of methylphenidate for treatment of drowsiness related to antiepileptic therapy with phenobarbital, phenytoin, and mephobarbital.¹⁹ She then developed choreoathetosis in the same distribution when treated with 2.5 mg of dextroamphetamine 1 week later, resolving within 12 hours.¹⁹

Unlike the 3-year-old girl reported by Mattson and Calverley,¹⁹ our patient had never developed chorea on high doses of methylphenidate (up to 40 mg t.i.d.), but did develop chorea when taking high doses of MAS. His total daily dose of MAS (135 mg) when he developed chorea was 2.5 times the average effective daily dose (54 mg) of MAS in a randomized, placebo-controlled trial in adult ADHD patients.¹ Perhaps chronic therapy with methylphenidate made him physiologically less sensitive to amphetamines because methylphenidate acts similarly to amphetamines in the central nervous system, facilitating presynaptic dopamine release in the striatum²⁰ and blocking

re-uptake of dopamine by the dopamine transporter.²¹ While some authors have reported that tolerance to methylphenidate occurs in humans (especially at doses higher than 60 mg per day),^{22,23} others believe that neither tolerance nor sensitization to methylphenidate occurs to a significant degree in the treatment of ADHD.²⁴

While hyperdopaminergic states are classically associated with chorea,^{20,25,26} another possibility is that serotonergic modulation of dopaminergic systems may have influenced the development of chorea in our patient. Certainly, chorea has been reported in patients taking other selective serotonin-reuptake inhibitors (SSRIs): paroxetine²⁷ and fluoxetine.^{28,29} Additionally, amphetamines not only promote presynaptic release of dopamine, they also promote presynaptic release of serotonin³⁰ unlike methylphenidate.³¹ In rats, serotonin also appears necessary to promote the markedly increased firing rate of neostriatal neurons induced by high doses of dextroamphetamine (7.5 mg/kg).³² Our patient would be at risk for a hyperserotonergic state due to high-dose amphetamine treatment in association with his concomitant use of escitalopram (the biologically active (S) enantiomer of the SSRI citalopram).

While citalopram reduces extracellular striatal dopamine concentrations and increases [¹¹C]raclopride binding to D2 receptors in some animal models,³³ there are multiple lines of evidence that citalopram and elevated brain serotonin levels are associated with enhanced striatal dopaminergic responses. In humans, citalopram appears to decrease [¹¹C]raclopride binding in the striatum, possibly indicating increased dopamine release in the setting of elevated serotonin levels.³⁴ Chronic administration of citalopram results in increased amphetamine-induced locomotor activity in rats.³⁵ Other studies have shown that citalopram increases D2 receptor expression in rat striatum at the receptor and mRNA levels.³⁶ These studies suggest that escitalopram, either directly or indirectly (through its SSRI action or by altering expression of dopamine receptors), could have influenced the manifestation of our patient's chorea in the setting of high-dose MAS treatment. While the exact mechanism of amphetamine-induced chorea is unknown, we recommend caution when prescribing high-dose amphetamine treatment for ADHD patients taking concomitant SSRI therapy.

References

1. Spencer T, Biederman J, Wilens T, et al. Efficacy of a mixed amphetamine salts compound in adults with attention-deficit/hyperactivity disorder. *Arch Gen Psychiatry* 2001;58:775–782.
2. Barkley RA. Major life activity and health outcomes associated with attention-deficit/hyperactivity disorder. *J Clin Psychiatry* 2002;63(Suppl. 12):10–15.
3. Adler LA, Chua HC. Management of ADHD in adults. *J Clin Psychiatry* 2002;63(Suppl. 12):29–35.
4. Wilens TE, Spencer TJ, Biederman J. A review of the pharmacotherapy of adults with attention deficit/hyperactivity disorder. *J Atten Disord* 2002;5:189–202.
5. Weiner WJ, Sanchez-Ramos J. Movement disorders and dopaminomimetic stimulant drugs. In: Lang AE, Weiner WJ, editors. *Drug-induced movement disorders*. Mt. Kisco, New York: Futura Publishing Co., Inc; 1992. p 315–337.
6. Lipkin PH, Goldstein IJ, Adelman AR. Tics and dyskinesias associated with stimulant treatment in attention-deficit hyperactivity disorder. *Arch Pediatr Adolesc Med* 1994;148:859–861.
7. Efron D, Jarman F, Barker M. Side effects of methylphenidate and dexamphetamine in children with attention deficit hyperactivity disorder: a double-blind, crossover trial. *Pediatrics* 1997;100:662–666.

8. Varley CK, Vincent J, Varley P, Calderon R. Emergence of tics in children with attention deficit hyperactivity disorder treated with stimulant medications. *Compr Psychiatry* 2001;42:228–233.
9. Tourette's Syndrome Study Group. Treatment of ADHD in children with tics. *Neurology* 2002;58:527–536.
10. Pascual-Leone A, Dhuna A. Cocaine-associated multifocal tics. *Neurology* 1990;40:999–1000.
11. Cardoso FE, Jankovic J. Cocaine-related movement disorders. *Mov Disord* 1993;8:175–178.
12. Rhee KJ, Albertson TE, Douglas JC. Choreoathetoid disorder associated with amphetamine-like drugs. *Am J Emerg Med* 1988;6:131–133.
13. Lundh H, Tunving K. An extrapyramidal choreiform syndrome caused by amphetamine addiction. *J Neurol Neurosurg Psychiatry* 1981;44:728–730.
14. Bartzokis G, Beckson M, Wirshing DA, et al. Choreoathetoid movements in cocaine dependence. *Biol Psychiatry* 1999;45:1630–1635.
15. Leys D, Destee A, Petit H, Warot P. Chorea associated with oral contraception. *J Neurol* 1987;235:46–48.
16. Rylander G. Psychoses and the punding and choreiform syndromes in addiction to central stimulant drugs. *Psychiatr Neurol Neurochir* 1972;75:203–212.
17. Prinzmetal M, Bloomberg W. The use of benzedrine for the treatment of narcolepsy. *JAMA* 1935;105:2051–2054.
18. Bray GA. Use and abuse of appetite-suppressant drugs in the treatment of obesity. *Ann Intern Med* 1993;119:707–713.
19. Mattson RH, Calverley JR. Dextroamphetamine-sulfate induced dyskinesias. *JAMA* 1968;204:108–110.
20. Weiner WJ, Nausieda PA, Klawans HL. Methylphenidate-induced chorea: case report and pharmacologic implications. *Neurology* 1978;28:1041–1044.
21. Seeman P, Madras B. Methylphenidate elevates resting dopamine which lowers the impulse-triggered release of dopamine: a hypothesis. *Behav Brain Res* 2002;130:79–83.
22. Winsberg B, Matinsky S, Kupietz S, Richardson E. Is there dose-dependent tolerance associated with chronic methylphenidate therapy in hyperactive children? Oral dose and plasma considerations. *Psychopharmacol Bull* 1987;23:107–110.
23. Ross DC, Fischhoff J, Davenport B. Treatment of ADHD when tolerance to methylphenidate develops. *Psychiatr Serv* 2002;53:102.
24. Solanto MV. Clinical psychopharmacology of AD/HD: implications for animal models. *Neurosci Biobehav Rev* 2000;24:27–30.
25. Klawans HL, Weiner WJ. The effect of d-amphetamine on choreiform movement disorders. *Neurology* 1974;24:312–318.
26. Nausieda PA, Bieliauskas LA, Bacon LD, et al. Chronic dopaminergic sensitivity after Sydenham's chorea. *Neurology* 1983;33:750–754.
27. Fox GC, Ebeid S, Vincenti G. Paroxetine-induced chorea. *Br J Psychiatry* 1997;170:193–194.
28. Bharucha KJ, Sethi KD. Complex movement disorders induced by fluoxetine. Complex movement disorders induced by fluoxetine. *Mov Disord* 1996;11:324–326.
29. Nielsen AS, Mors O. Choreiform dyskinesias with acute onset and protracted course following fluoxetine treatment. *J Clin Psychiatry* 1999;60:868–869.
30. Bradbury AJ, Costall B, Naylor RJ, Onaivi ES. 5-Hydroxytryptamine involvement in the locomotor activity suppressant effects of amphetamine in the mouse. *Psychopharmacology (Berl)* 1987;93:457–465.
31. Kuczenski R, Segal DS. Effects of methylphenidate on extracellular dopamine, serotonin, and norepinephrine: comparison with amphetamine. *J Neurochem* 1997;68:2032–2037.
32. Rebec GV, Alloway KD, Curtis SD. Apparent serotonergic modulation of the dose-dependent biphasic response of neostriatal neurons produced by d-amphetamine. *Brain Res* 1981;210:277–289.
33. Dewey SL, Smith GS, Logan J, et al. Serotonergic modulation of striatal dopamine measured with positron emission tomography (PET) and in vivo microdialysis. *J Neurosci* 1995;15:821–829.
34. Tiihonen J, Kuoppamaki M, Nagren K, et al. Serotonergic modulation of striatal D2 dopamine receptor binding in humans measured with positron emission tomography. *Psychopharmacology (Berl)* 1996;126:277–280.
35. Arnt J, Overo KF, Hyttel J, Olsen R. Changes in rat dopamine- and serotonin function in vivo after prolonged administration of the specific 5-HT uptake inhibitor, citalopram. *Psychopharmacology (Berl)* 1984;84:457–465.
36. Kameda K, Kusumi I, Suzuli K, et al. Effects of citalopram on dopamine D2 receptor expression in the rat brain striatum. *J Mol Neurosci* 2000;14:77–86.

Unusual Forehead Tremor in a Patient With Essential Tremor

Panida Piboolnurak, MD,¹ Seth L. Pullman, MD,¹
and Elan D. Louis, MD, MS^{1–3*}

¹Department of Neurology, College of Physicians and Surgeons, Columbia University, New York, New York, USA

²Gertrude H. Sergievsky Center, College of Physicians and Surgeons, Columbia University, New York, New York, USA

³Taub Institute for Research on Alzheimer's Disease and the Aging Brain, College of Physicians and Surgeons, Columbia University, New York, New York, USA



Abstract: Voice and head (neck) tremor commonly occur in patients with essential tremor (ET), but involvement of cranial musculature is generally limited to these specific cranial structures, and action tremor of the forehead has not been reported. We describe a patient with ET who had forehead tremor. The tremor seemed to be task-specific, and neurophysiological features suggested that the forehead tremor was dystonic. The presence of forehead tremor in a patient with ET probably indicates an additional pathophysiologic process. The explanation for the specificity of involvement of cranial musculature in ET is not known, but this clinical observation might help guide investigators who are interested in the underlying pathophysiology of this condition. © 2004 Movement Disorder Society

Key words: essential tremor; dystonia; clinical heterogeneity; neurophysiology; pathophysiology

Patients with essential tremor (ET) typically have kinetic tremor. The tremor is most commonly seen in the arms, but it can involve other parts of the body, including the head.^{1,2}

This article includes Supplementary Video, available online at <http://www.interscience.wiley.com/jpages/0885-3185/suppmat>

*Correspondence to: Dr. Elan D. Louis, Unit 198, Neurological Institute, 710 West 168th Street, New York, NY 10032.

E-mail: EDL2@columbia.edu

Received 11 November 2003; Accepted 22 December 2003

Published online 16 March 2004 in Wiley InterScience (www.interscience.wiley.com). DOI: 10.1002/mds.20080

Facial tremor, however, appears to be uncommon, and to our knowledge, it has not been reported. We present an ET patient with forehead tremor; however, clinical and neurophysiological features suggested that another process in addition to ET was the cause of the forehead tremor.

Case Report

Our patient is a 62-year-old, right-handed man whose tremor began at age 44 years with an action tremor of both arms, particularly on the right. Initially, the tremor was apparent during different activities (e.g., writing, eating, drinking) and gradually worsened so that he occasionally began to use his left hand for writing and pouring. He was given a diagnosis of ET by his family doctor, but no treatment was prescribed. By age 52 years, family members pointed out a head tremor, which was mild and did not bother the patient. At age 62 years, he was first seen by one of the authors (E.D.L.) at the Center for Parkinson's Disease and Other Movement Disorders at Columbia Presbyterian Medical Center. His main complaint was worsening arm tremor, for which he wanted treatment. He also noted a head (neck) tremor, although it was not bothersome. He did not notice forehead tremor. His medications were atenolol 50 mg per day for hypertension and clonazepam 0.25 mg twice a day for anxiety. He noted that ethanol (one glass of wine) had a mild beneficial effect on his tremor. His past medical history was unremarkable. His mother had died at age 72 years and had had head (neck) tremor for approximately 10 years. He had no siblings and his two children, aged 29 and 35 years, do not have tremor. His arm tremor was rated on examination with the Washington Heights-Inwood Genetic Study of Essential Tremor (WHIGET) Rating Scale³ (0 = no visible tremor; 1 = low-amplitude or intermittent tremor; 2 = moderate-amplitude tremor that is clearly oscillatory and usually present; 3 = high-amplitude tremor). The examination revealed a mild regular postural tremor of both arms (rating = 1) without dystonic posturing of the limbs, a moderate kinetic tremor of the right arm (rating = 2) and mild to moderate kinetic tremor of the left arm (rating = 1-2; see Video, Segments 1-3). Kinetic tremor was tested while pouring, drinking, using a spoon, touching finger-to-nose, and drawing spirals (see Video, Segments 2 and 3). There was no rest tremor. He had a mild head tremor but no voice tremor. There was no dystonic neck deviation. When he was sitting quietly and facing the examiner, there was no forehead tremor (see Video, Segment 4). While speaking, his frontalis muscles contracted, resulting in bilateral eyebrow elevation and forehead tremor (see Video, Segment 5). When he stopped speaking, the tremor stopped. When he was asked to speak while trying not to raise his eyebrows, there was no forehead tremor. When he raised his eyebrows without speaking, there was minimal and intermittent forehead tremor. His examination was otherwise normal. His gait and balance were normal. He was able to tandem walk without difficulty. He had no weakness, cranial nerve abnormalities, upper motor neuron signs, cerebellar signs, parkinsonism, or sensory impairment. His comprehensive metabolic panel and thyroid function tests were normal. To further evaluate his atypical forehead tremor, he was referred for a computerized tremor analysis test.

Neurophysiological Findings

Four channels were used to record frontalis and orbicularis muscles bilaterally with silver/silver chloride electromyogra-

phy (EMG) surface electrodes (Fig. 1). One channel recorded accelerometry using ultra-light piezoresistive tri-axial miniature accelerometers (± 25 g, weight: 1.2 g) with linear sensitivities of approximately 4.5 mV/g in the physiologic range, attached rostral to the left eyebrow. Data were acquired and analyzed using semiautomatic interactive software developed in the Clinical Motor Physiology Laboratory during the following tasks: sitting, reading quietly, reading out loud, talking, counting, finger-to-nose movement, pouring water, and writing. When seated and silent, there was no tremor of the forehead. When he was reading out loud, talking, or counting, there was a 1 to 3 Hz co-contraction of the frontalis and orbicularis oculi muscles, associated with forehead tremor. The tremor was irregular and associated with a mix of short duration (50-100 msec) and longer duration (200-800 msec) EMG bursts. EMG activities of bilateral frontalis and orbicularis oculi muscles were not always synchronous. No forehead tremor was present during motor tasks of the hands such as finger-to-nose movement, pouring water, or writing.

Discussion

Tremor is defined by an oscillatory movement of a body part, produced by rhythmic alternating or simultaneous contractions of antagonistic muscle groups. It is generally described by the affected sites, activating conditions, amplitude, frequency, regularity, and rhythmicity. Because tremors of different causes have their own characteristics, these differences can often aid in the differential diagnosis.

In patients with ET, facial tremor is uncommon. In a series of 350 patients with ET seen at a tertiary referral clinic, sites of tremor included the hand (89.7%), head (40.9%), voice (17.7%), legs (13.7%), jaw (7.1%), face (2.9%), trunk (1.7%), and tongue (1.4%).⁴ To our knowledge, forehead tremor has not been reported in patients with ET. Critchley, in a review article on ET, commented that tremor of the head and neck may occur at the occipitoatlantic articulation, in the masseters, facial muscles, eyelids, external ocular muscles, extrinsic and intrinsic laryngeal muscles, tongue, and palate,² but they did not comment on the forehead. In most clinical series, the presence of forehead tremor is not specifically commented upon.⁵⁻⁷ In a population-based study of 175 ET cases in Papua New Guinea,¹ the authors specifically reported that muscles of the upper face (frontalis and periorbital muscles) were not involved in any cases.

It can be difficult on general neurological examination to distinguish dystonic tremor from the action tremor of ET. Moreover, there are many reports of the coexistence of ET and dystonia in the same patient.⁸⁻¹⁴ Our patient's forehead tremor seemed to be task-specific, which suggested that it was dystonic. Furthermore, physiologically, the combination of irregular tremor, low tremor frequency, and co-contraction of antagonistic muscle groups with mixed short and long duration EMG bursts suggested that the forehead tremor was dystonic.

In summary, although voice and head (neck) tremor commonly occur in patients with ET, involvement of cranial musculature is generally limited to these specific cranial structures and action tremor of the forehead has not been reported. The presence of forehead tremor probably indicates an additional pathophysiologic process, and objective computerized physiologic testing may aid in the differential diagnosis. The explanation for the specificity of involvement of cranial musculature in ET is not known but this clinical observation might help

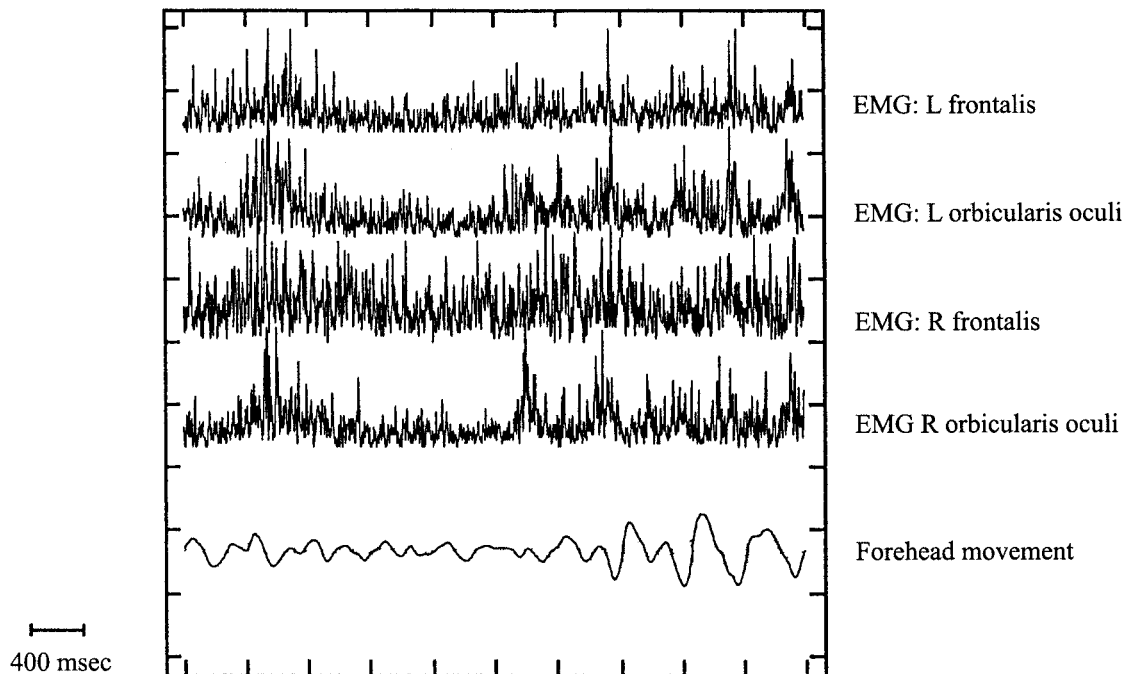


FIG. 1. Upper four traces show surface electromyogram (EMG) obtained from bilateral frontalis and orbicularis oculi muscles while the patient was speaking and experiencing forehead tremor. Note the irregularly timed short and long burst durations (50–800 msec) in all muscles. Note also the co-contractions of the antagonistic frontalis and orbicularis muscles. The bottom trace shows the corresponding irregular left forehead movements recorded rostral to the left eyebrow.

guide investigators who are interested in the underlying pathophysiology of this condition.

Acknowledgments: This study was funded by the National Institutes of Health (R01 NS42859, R01 NS39422, P30 ES09089, and RR00645 to E.D.L.).

Legends to the Video

Segment 1. The patient has mild postural tremor of both arms.

Segment 2. The patient is pouring water from one cup to another and using a spoon to bring water to his mouth. There is moderate kinetic tremor in the right arm and mild to moderate kinetic tremor in the left arm.

Segment 3. While he is performing the finger to nose maneuver, the patient has moderate kinetic tremor in the right arm and mild to moderate kinetic tremor in the left arm. No forehead tremor is visible.

Segment 4. When he is sitting quietly, there is no forehead tremor.

Segment 5. The patient is asked to speak. His frontalis muscles contract, resulting in elevation of the eyebrows and forehead tremor.

References

- Hornabrook RW, Nagurney JT. Essential tremor in Papua, New Guinea. *Brain* 1976;99:659–672.
- Critchley M. Observations on essential (heredofamilial) tremor. *Brain* 1949;72(Pt 2):113–139.
- Louis ED, Barnes L, Wendt KJ, Ford B, et al. A teaching videotape for the assessment of essential tremor. *Mov Disord* 2001;16:89–93.
- Lou JS, Jankovic J. Essential tremor: clinical correlates in 350 patients. *Neurology* 1991;41(Pt 1):234–238.
- Massey EW, Paulson GW. Essential vocal tremor: clinical characteristics and response to therapy. *South Med J* 1985;78:316–317.
- Findley LJ, Gresty MA. Head, facial, and voice tremor. *Adv Neurol* 1988;49:239–253.
- Longe AC. Essential tremor in Nigerians: a prospective study of 35 cases. *East Afr Med J* 1985;62:672–676.
- Couch JR. The relationship between spasmodic torticollis and essential tremor. *Trans Am Neurol Assoc* 1975;100:181–183.
- Deuschl G, Heinen F, Guschlbauer B, Schneider S, Glocker FX, Lucking CH. Hand tremor in patients with spasmodic torticollis. *Mov Disord* 1997;12:547–552.
- Dubinsky RM, Gray CS, Koller WC. Essential tremor and dystonia. *Neurology* 1993;43:2382–2384.
- Durr A, Stevanin G, Jedynak CP, Penet C, Agid Y, Brice A. Familial essential tremor and idiopathic torsion dystonia are different genetic entities. *Neurology* 1993;43:2212–2214.
- Ferraz HB, De Andrade LA, Silva SM, Borges V, Rocha MS. [Postural tremor and dystonia. Clinical aspects and physiopathological considerations]. *Arq Neuropsiquiatr* 1994;52:466–470.
- Koller WC, Busenbark K, Miner K. The relationship of essential tremor to other movement disorders: report on 678 patients. Essential Tremor Study Group. *Ann Neurol* 1994;35:717–723.
- Munchau A, Schrag A, Chuang C, et al. Arm tremor in cervical dystonia differs from essential tremor and can be classified by onset age and spread of symptoms. *Brain* 2001;124(Pt 9):1765–1776.

Refined Linkage to the RDP/DYT12 Locus on 19q13.2 and Evaluation of *GRIK5* as a Candidate Gene

Christoph Kamm, MD,¹ Joanne Leung, MS,¹
Soni Joseph, BS,² William B. Dobyns, MD,³
Alison Brashear, MD,⁴ Xandra O. Breakefield, PhD,¹
and Laurie J. Ozelius, PhD^{2*}

¹*Molecular Neurogenetics Unit, Departments of Neurology and Radiology and Neuroscience Program, Massachusetts General Hospital and Harvard Medical School, Boston, Massachusetts, USA*

²*Department of Molecular Genetics, Albert Einstein College of Medicine, Bronx, New York, USA*

³*Department of Human Genetics, Neurology and Pediatrics, University of Chicago, Illinois, USA*

⁴*Department of Neurology, Indiana University School of Medicine, Indianapolis, Indiana, USA*

Abstract: By examining two previously described families with rapid-onset dystonia parkinsonism, we have identified a key recombination event that places the disease locus (DYT12) into a 5.9 cM interval flanked by markers D19S224 and D19S900. Evaluation of a positional candidate gene, the glutamate receptor subunit *GRIK5*, revealed no mutations. © 2004 Movement Disorder Society

Key words: DYT12; rapid-onset dystonia–parkinsonism; kainate receptor

Rapid-onset dystonia–parkinsonism (RDP) is a rare, autosomal-dominantly inherited, disabling movement disorder. Typically, patients experience sudden onset over hours to days of dystonic posturing of the limbs, bradykinesia, postural instability, dysarthria, and dysphagia, followed by little or no progression.¹ Age of onset ranges from late childhood to early adulthood and may be triggered by stressful events, including physical exercise, emotional stress, fever, or childbirth. Linkage of this disease gene to an 8 cM region on chromosome 19q13, defined by flanking markers D19S587 and D19S900, has been reported.² In an attempt to reduce the minimal chromosomal region containing the disease gene, we genotyped 13 known polymorphic markers in the DYT12 region in 2 unrelated, previously described RDP families, RDP-1³ and RDP-2.⁴ Both of these families show linkage to the candidate region on chromosome 19q13, with the highest com-

bined two-point logarithm of odds score occurring at D19S198 ($Z = 4.04$ at $\theta = 0.0$).²

One of the candidate genes in this region, *GRIK5*, encodes a kainate-type glutamate receptor subunit, KA2. In rat brain, abundant *GRIK5* mRNA levels have been found in the basal ganglia, especially in the striatum, substantia nigra pars compacta, and subthalamic nucleus,⁵ regions that are critically involved in movement control.⁶ Given that corticostriatal glutamatergic neurons form the major afferent projection to the striatum, the KA2 subunit could act by modulating dopaminergic input into the striatum. To evaluate the role of the *GRIK5* gene in RDP, we screened two representative affected individuals from both of the RDP families for mutations in the coding region (exons 1–19) and one putative regulatory region.^{7,8}

Patients and Methods

Blood samples were collected from participants after obtaining informed consent, and DNA was extracted using standard procedures. Two representative affected individuals from each family, RDP-1 and RDP-2 (both Caucasian), containing the complete haplotypes across the region were used for mutational analysis along with 3 control subjects from the same ethnic group: Patients III-9 and II-4 from Family RDP-1 and patients II-2 and II-4 from Family RDP-2 [pedigree designations according to Kramer and colleagues²]. The structure, clinical features, and marker haplotypes of these 2 RDP families have been described in detail elsewhere^{3,4}; briefly, there were 12 affected members in Family RDP-1 and 4 affected members in Family RDP-2.

The exon–intron structure for the human *GRIK5* gene can be found under GenBank accession no. NT_011109 (LocusLink 2901, UniGene Cluster Hs.249141). The genomic sequence of the human *GRIK5* gene was used to design primer sets (see Table 1) to amplify fragments, spanning the entire coding region, splice junctions, and a putative regulatory region (778 bp) within the 5' untranslated region (UTR) of the human *GRIK5* gene.

The entire coding sequence of the human *GRIK5* gene was amplified from genomic DNA of 4 patients and 3 controls by polymerase chain reaction (PCR). Fragments of less than 350 bp were first screened for mutations using single-stranded conformation polymorphism (SSCP) analysis, followed by direct sequencing (see below). Variants seen on the SSCP gel were sequenced and compared to control samples. Fragments larger than 350 bp were sequenced directly without SSCP analysis. PCR products were sequenced using either the Thermo Sequenase radiolabeled terminator cycle sequencing kit (USB) or the Taq DyeDeoxy Terminator cycle sequencing kit (Applied Biosystems), and run on an ABI 3700 PRISM automated sequencer.

Genotyping was performed according to a standard PCR protocol (Research Genetics/Invitrogen) using an ABI 377 automated DNA sequencer. The Genescan and Genotyper software package from ABI was used to determine fragment sizes and to assign allele status. We used the following microsatellite markers on chromosome 19q13 spanning the DYT12 locus: D19S587 (59.36 cM), D19S224 (61.49), D19S570 (62.03), D19S220 (62.03), D19S422 (63.10), D19S417 (63.10), D19S200 (63.63), D19S223 (64.16), D19S400 (64.70), D19S198 (65.77), D19S420 (66.30), D19S408 (67.37), and D19S900 (67.37). Sex-averaged map positions in centimorgans (obtained online at <http://research.marshfieldclinic.org/genetics/>) are given in parentheses.

Dr. Kamm's present address is Department of Neurodegenerative Diseases and Hertie-Institute for Clinical Brain Research, University of Tuebingen, Germany

*Correspondence to: Laurie J. Ozelius, Department of Molecular Genetics, Albert Einstein College of Medicine, Ullmann 1211, 1300 Morris Park Avenue, Bronx, NY 10461.

E-mail: ozelius@aecom.yu.edu

Received 20 August 2003; Revised 18 December 2003; Accepted 29 December 2003

Published online 16 March 2004 in Wiley InterScience (www.interscience.wiley.com). DOI: 10.1002/mds.20095

TABLE 1. Primers used to amplify *GRIK5* fragments and PCR conditions

Exon	Forward primer (5'→3')	Reverse primer (5'→3')	Product size (bp)	PCR ann. temp. (°C)
5'UTR	CCCCCTTTTACTGCTCTG	TCACCCATGGCCAGTGATGAG	778	55°
1	CCACATAGTAATCTCCCCTTG	TCACCCATGGCCAGTGATGAG	185	60°
2	CTCCTTCTCAGGACTCAG	CTCACTGGTGTCCGTGGTC	220	60°
3	TTGCCAGTGTCTGATCCTC	CTCCATCCTGCTTCCCGC	285	55°
4	AGAAGCAGGATGGAGGCCA	TCACACTCAGCCTTGGCCG	207	62°
5	CATGCCTGGGTAGCCAGAAG	TCACCTTAGGAGGATGAG	234	60°
6	CCTGTGGGTCTCTGTCTCTCA	TGGGGCTAAGCCCTAATGGGA	178	62°
7	AGGCCTCACGCTCTTC	TGTGCAGAGTGTTCGG	233	66°
8	AGGCAGCCTCTTATCCATCC	ACCATGCCGAGGTAGTTC	199	62°
9	TGCCTTCTCTGTGGATGTC	CAGGTGCGGTAGAGTAC	344	57°
10	TGCCATGACCTCAGGCAG	TGCATCCCTCCACCTCAC	239	66°
11	CGCAACCCAGCCACTAGA	CTGCTTCTGAGGTTGCACTG	350	66°
12	AGGCCCTGAGCCTCCATG	CTCCGTGCATTTCTCTCTAAC	239	60°
13	TCCAGTAGGCAGTGGAC	GGTGTCTCCGGGTCTCAC	164	60°
14	GGCAGAGGCAGATAGAAAAG	ACACGCTGCACGTCTCTC	223	60°
15	AGCCTGAGAGGTTCTGG	ACTCCAGCCGCTGACTCAC	227	69°
16	GCCCTGCTGTGTCCACAC	CCTGGGTTGAGGGAGACTTC	339	60°
17	GGGAAGGGGACACCATAC	GGCACAGTTTGGGGTTTG	233	60°
18	CCCAATGCCACAATCTTCAC	ACAGCCCCAACTCCCTTTG	242	55°
19	AGCCTCCAGCCCTTCCTC	TGCCGAGCCCACTGCTA	526	69°

PCR, polymerase chain reaction; ann. temp., annealing temperature; UTR, untranslated region.

Results

Linkage was evaluated to 13 known polymorphic markers within the DYT12 region as described in Kramer and coworkers.² Families RDP-1 and RDP-2 do not share a common haplotype in this region.² In Family RDP-1, a key recombination event between marker D19S224 and the putative disease gene refined the candidate region to a 5.9 cM interval between this marker and D19S900 (Fig. 1, III.6). Several markers were generated between D19S224 and D19S220 in an attempt to further define the proximal crossover; however, all four markers tested were uninformative (data not shown). Further refinement of the distal recombination was not attempted, as marker D19S408 (according to <http://www.genome.ucsc.edu/cgi-bin/hgGateway>) is located within 120 kb of D19S900, but does not recombine (Fig. 1, III.16).

A 500-bp fragment within the 3' end of intron 1 of the rat *GRIK5* gene (exon 1 in rat is untranslated) has been identified as acting as a transcriptional silencer⁷ by binding to the nuclear orphan receptors COUP-TF1, EAR2, and NURR1.⁸ Alignment of the nucleotide sequence between rat and human genomic *GRIK5* sequences revealed significant sequence homology (86% identity over a 255-bp region within this 500-bp fragment) between the two species; therefore, we included this untranslated region in our screen for mutations in RDP patients.

Genomic DNA from 2 affected members from each family (RDP-1 and RDP-2) was used to amplify all *GRIK5* exons that contain coding sequence, as well as a putative regulatory fragment within the human 5' UTR using the flanking intronic primers listed in Table 1. Amplified fragments of appropriate length (<350 bp) were screened by SSCP. When no mutations were identified, all fragments from these individuals were sequenced; this screen did not reveal any changes in nucleotide sequence compared to 3 healthy Caucasian controls.

Discussion

We report further genetic studies in two previously described families with RDP with linkage to the DYT12 locus. By ob-

serving a key recombination in Family RDP-1, we were able to refine the DYT12 candidate region to a 5.9 cM interval between the microsatellite markers D19S224 and D19S900. This relatively large region, which does not overlap with a novel locus for late-onset Parkinson's disease on chromosome 19p13.3-q12 recently reported in a large Cuban family,⁹ contains many genes, approximately 230 (according to <http://www.ncbi.nlm.nih.gov>). In addition to RDP-1, there are 2 other published RDP families, but neither Family RDP-2¹ (this study) or an Irish family, RDP-3¹⁰ (Andrew Green, personal communication), show recombination events that would further refine the locus, so we decided to focus on positional candidates. Among these genes, *GRIK5* appeared to be a particularly attractive candidate, because it encodes an ion channel that is preferentially expressed in the basal ganglia. However, no mutations or polymorphisms in the coding region, splice junctions, or a putative regulatory region were found in 2 patients each from 2 RDP families. Thus, RDP in these 2 families is unlikely to be caused by mutations in *GRIK5*, although our analysis does not exclude gene rearrangements, large deletions, or mutations in other promoter or regulatory regions. Among the many genes in the region, a few that are expressed in the central nervous system and may be candidates for RDP include the Ryanodine receptor (*RYR1*), glia maturation factor, gamma (*GMF-g*), delta-like 3 (*DLL3*), Periaxin (*PRX*), *D4*, numb homolog (Drosophila)-like (*NUMBL*), and suppressor of Ty 5 homolog (*SUPT5H*). Information about genes and positions can be found online at LocusLink (<http://www.ncbi.nlm.nih.gov>).

Given the large candidate region, future efforts that aim to better define the region harbouring the disease gene will be critical to the eventual identification of the gene causing RDP. To that end, more families with the typical RDP phenotype need to be identified and, potentially, other molecular techniques, such as microarray analysis using positional candidates, should be applied. The eventual identification of the gene responsible for RDP is likely to reveal insights into molecular pathways common to both dystonia and parkinsonism.

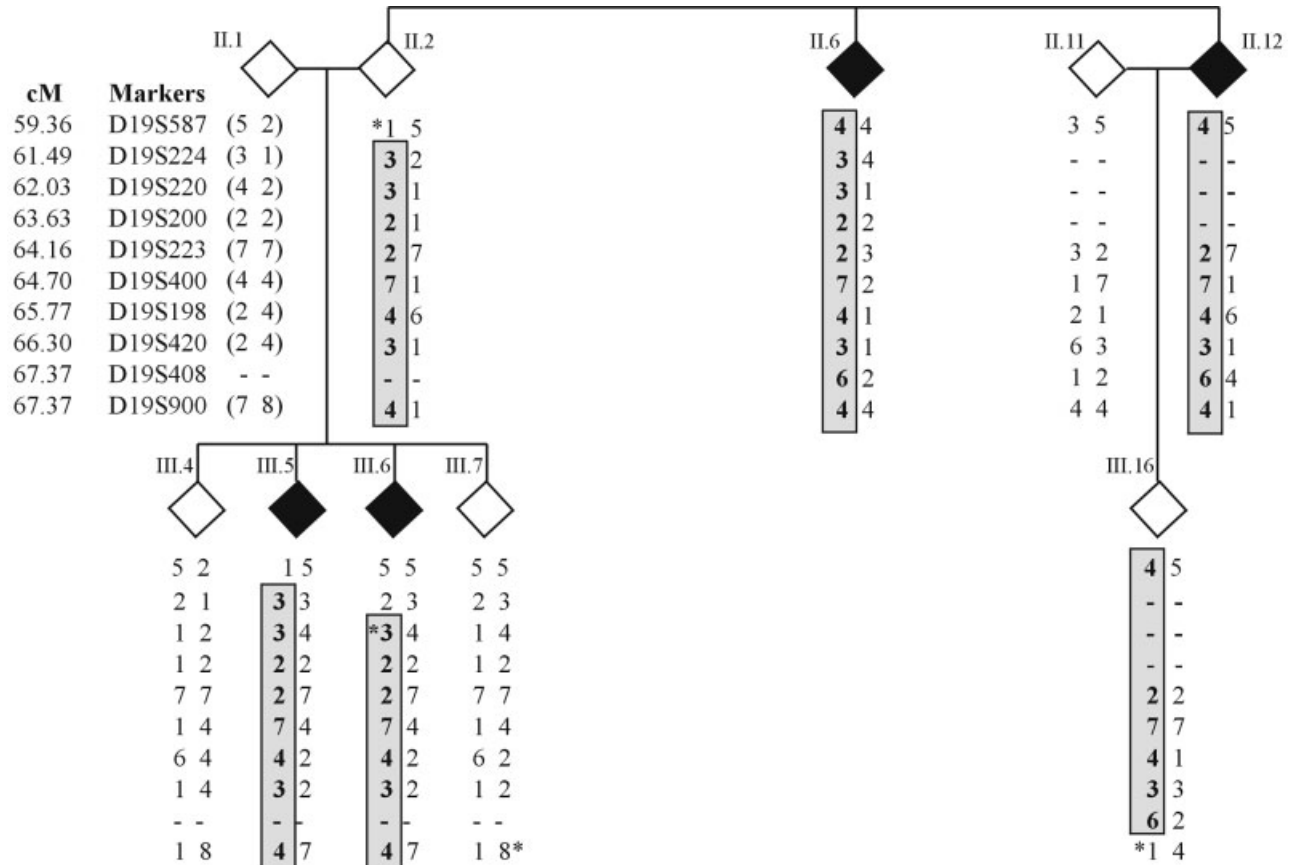


FIG. 1. Partial pedigree for Family RDP-1 showing recombination events. Haplotypes of informative markers are shown for critical family members of RDP-1. Marker order is given at the left of the figure, with genetic distances in centimorgans (cM) (according to <http://research.marshfieldclinic.org/genetics/>). Shaded individuals are affected, the haplotype of the disease-bearing chromosome is boxed and shaded, and an asterisk indicates cross-overs. Recombination events in individual III.6 (proximal) and III.16 (distal) place the DYT12 locus between markers D19S224 and D19S900 in a 5.9 cM interval. The pedigree has been anonymised to protect the identity of the family. RDP, rapid-onset dystonia-parkinsonism.

Acknowledgments: We thank all patients and family members who participated in this study. This study was supported in part by a research grant from the Dystonia Medical Research Foundation (DMRF; L.O.) and the National Institute of Neurological Disease and Stroke MGH/MIT Parkinson’s Disease Center (NS38372 to X.O.B.). C.K. was a fellow of the Deutsche Forschungsgemeinschaft (DFG).

References

1. Brashear A, Butler IJ, Ozelius LJ, et al. Rapid-onset dystonia-parkinsonism: a report of clinical, biochemical, and genetic studies in two families. *Adv Neurol* 1998;78:335-339.
2. Kramer PL, Mineta M, Klein C, et al. Rapid-onset dystonia-parkinsonism: linkage to chromosome 19q13. *Ann Neurol* 1999;46:176-182.
3. Dobyns WB, Ozelius LJ, Kramer PL, et al. Rapid-onset dystonia-parkinsonism. *Neurology* 1993;43:2596-2602.
4. Brashear A, DeLeon D, Bressman SB, Thyagarajan D, Farlow MR, Dobyns WB. Rapid-onset dystonia-parkinsonism in a second family. *Neurology* 1997;48:1066-1069.
5. Wullner U, Standaert DG, Testa CM, Penney JB, Young AB. Differential expression of kainate receptors in the basal ganglia of the developing and adult rat brain. *Brain Res* 1997;768:215-223.
6. Wichmann T, DeLong MR. Functional and pathophysiological models of the basal ganglia. *Curr Opin Neurobiol* 1996;6:751-758.
7. Huang F, Gallo V. Gene structure of the rat kainate receptor subunit KA2 and characterization of an intronic negative regulatory region. *J Biol Chem* 1997;272:8618-8627.
8. Chew LJ, Huang F, Boutin JM, Gallo V. Identification of nuclear orphan receptors as regulators of expression of a neurotransmitter receptor gene. *J Biol Chem* 1999;274:29366-29375.
9. Bertoli-Avella AM, Giroud-Benitez JL, Bonifati V, et al. Suggestive linkage to chromosome 19 in a large Cuban family with late-onset Parkinson’s disease. *Mov Disord* 2003;18:1240-1249.
10. Pittock SJ, Joyce C, O’Keane V, et al. Rapid-onset dystonia-parkinsonism: a clinical and genetic analysis of a new kindred. *Neurology* 2000;55:991-995.

Spinocerebellar Ataxia Type 2 With Levodopa-Responsive Parkinsonism Culminating in Motor Neuron Disease

Jon Infante, MD,¹ José Berciano, MD,^{1*}
Victor Volpini, MD,² Jordi Corral, MD,²
José Miguel Polo, MD,¹ Julio Pascual, MD,¹
and Onofre Combarros, MD¹

¹*Service of Neurology, University Hospital "Marqués de Valdecilla" (University of Cantabria), Santander, Spain*

²*Service of Genetics, Hospital "Durán i Reynals" (IRO), Barcelona, Spain*

Abstract: We describe an exceptional spinocerebellar ataxia type 2 (SCA2) phenotype combining cerebellar ataxia, levodopa-responsive parkinsonism, and motor neuron symptoms. We conclude that motor neuron symptoms and signs may be a striking manifestation in SCA2, masking pre-existing cerebellar and extrapyramidal semeiology. © 2004 Movement Disorder Society

Key words: SCA2; parkinsonism; ALS

The clinical hallmark of spinocerebellar ataxia type 2 (SCA2) is cerebellar gait and limb ataxia associated with slowed saccadic eye movements and hyporeflexia, but there may be considerable intra- and interfamilial variation of clinical semeiology.^{1–8} We describe an exceptional SCA2 phenotype combining cerebellar symptoms evolving to parkinsonism and upper and lower motor neuron semeiology mimicking amyotrophic lateral sclerosis (ALS).

Subjects and Methods

This pedigree comprises 5 affected individuals in two generations, 4 of whom were examined by the authors (Fig. 1). Informed consent was obtained from all patients and at-risk asymptomatic adult subjects for blood sampling. The study was approved by the Ethical Committee of the University Hospital "Marqués de Valdecilla." Permission for photographs was obtained from both the patient and her husband.

Genomic DNA was extracted from lymphocytes by standard methods. Screening of dynamic CAG and CTG (SCA8) mutations associated with autosomal dominant cerebellar ataxia (ADCA) was carried out as reported elsewhere.⁹

Results

Proband Patient

In June 1994, at age 61, this woman (Case III-4 in Fig. 1) developed gait imbalance, dysarthria, intermittent dysphagia, and urinary urgency. A diagnosis of idiopathic late onset ataxia (ILOCA) had been proposed elsewhere. Examination 6 months later revealed severe gait and limb cerebellar ataxia, spasmodic dysphonia, hyperreflexia with extensor plantar responses and minimal weakness in the upper limbs, impassive face and disproportionate anterocollis (Fig. 2), rigidity of all four extremities, bradykinesia, marked impairment of postural reflexes, and slowed eye saccades. We did not observe rest tremor or fasciculations. Neither weakness of extensor neck muscles nor difficulty in passive extension of the neck was noted, and no orthostatic hypotension was detected. Both the proband and her husband were unaware of any others possibly affected in the pedigree (vide infra). The proband's mother, 84 years of age, was asymptomatic, and her examination was normal; the proband's father died at age 28 during the Spanish civil war, and examination of her daughters, then between 30 and 40 years of age, was also normal. Routine laboratory investigations, including cerebrospinal fluid were normal. Brain magnetic resonance imaging (MRI) study showed severe brainstem and cerebellar atrophy (Fig. 3). Electromyography of tibialis anterior muscle and motor conduction studies of peroneal and median nerves were normal, and a diagnosis of multiple system atrophy (MSA) was established. She was given levodopa/carbidopa up to 600/150 mg with clear improvement of her rigidity and bradykinesia.

As of April 1995, the patient's clinical picture drastically deteriorated and was accompanied by progressive generalized weakness, persistent dysphagia, and urinary urgency and incontinence; there was no cognitive decline. In September 1995, she was chairbound; at that time, examination revealed anarthria, severe facio-lingual-masticatory weakness, quadriplegia (MRC grade 2-3/5), and generalized amyotrophy and fasciculations, including paraspinal, facial, and lingual muscles. There was also marked weakness of neck flexor–extensor musculature, but extensor weakness was so marked that she adopted an almost permanent posture of head drop (Fig. 2). Electromyography of all five muscles from upper and lower limbs revealed profuse fibrillation and fasciculation potentials, dropout of motor units with a decreased recruitment pattern, and large long duration of motor potentials units. Nerve conduction study was again normal with no evidence of conduction block. The clinical picture progressed to quadriplegia and complete bulbar palsy in the next 2 years. The patient died in September 1997 at home; an autopsy was not performed.

Other Cases in the Pedigree

In 1997, we evaluated Case III-6, allowing us to accurately delineate the pedigree (Fig. 1). Case II-3 was said to have gait ataxia and dysarthria beginning in adulthood; he died at age 75 of brain stroke.

Case II-9 began to complain of gait instability and urinary urgency in 1989 at age 62. Examination 10 years later showed mild gait and limb cerebellar ataxia and dysarthria; he was able to walk without support, and muscle reflexes were preserved. Neither ophthalmoplegia nor signs of sensorimotor neuropathy were noted. MRI study showed

*Correspondence to: José Berciano, Service of Neurology, University Hospital "Marqués de Valdecilla" (UC), 39008 Santander, Spain. E-mail: neuro@humv.es

Received 10 October 2003; Revised 17 December 2003; Accepted 29 December 2003

Published online 16 March 2004 in Wiley InterScience (www.interscience.wiley.com). DOI: 10.1002/mds.20090

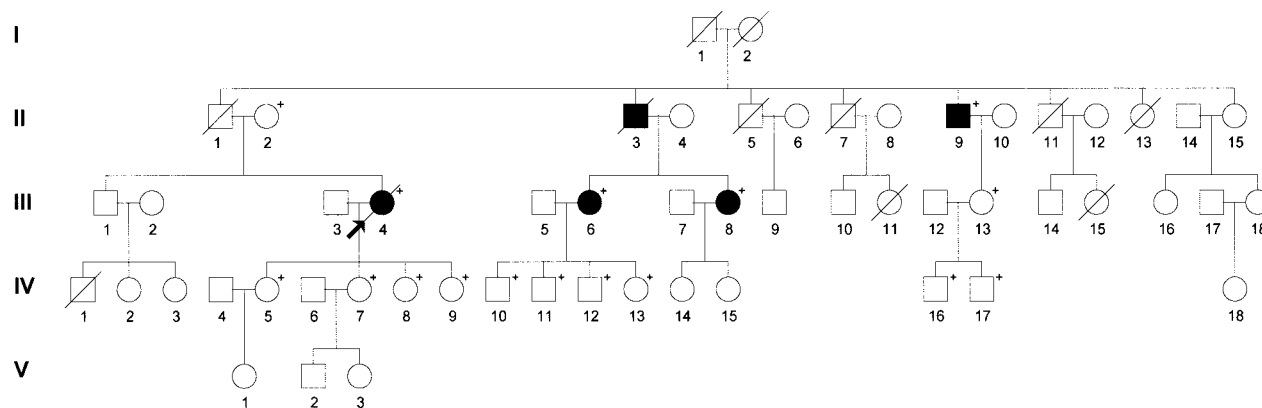


FIG. 1. Family pedigree. Plus signs indicate subjects examined by the authors. Squares represent males.

cerebellar and brainstem atrophy. Examination of his 40-year-old daughter was normal.

Case III-6 is a 59-year-old woman who developed gait instability at age 53. Examination in 2001 showed mild gait and limb cerebellar ataxia and dysarthria; she was able to walk without support. Again neither ophthalmoplegia nor signs of sensorimotor neuropathy were noted. Examination of her three sons and daughter, between 20 and 30 years of age, was normal.

Case III-8 was evaluated in 2001 at age 50. Since age 42, she has suffered from gait instability. She referred to occasional leg cramps. Examination showed dysarthria, slowed eye saccades, and moderate gait and limb cerebellar ataxia, although she was still able to walk without support. Muscle reflexes were preserved in the upper limbs and increased in the lower limbs; plantar responses were equivocal. There was stocking hypallegesthesia. Prominent facial myokymia and widespread fasciculations in the lower limbs were observed; despite this finding, neither leg amyotrophy nor paraparesis was noted. Electromyography, performed elsewhere, revealed a neurogenic pattern in muscles of the lower limbs with fibrillation and fasciculation potentials. MRI study showed brainstem and cerebellar atrophy. Examination of her two daughters, 35 and 37 years of age, was normal.

Genetic Study

DNA samples were available from cases II-9, II-15, III-4, III-6, III-8, and III-13. Cases II-15 and III-13 showed normal genotype (22/22 CAG repeats in both). All four clinically affected members had an expanded allele with 35/22 (case III-4), 36/22 (cases II-9 and III-6), and 38/22 (case III-8) repeat CAG numbers.

Discussion

The clinical picture in the proband was initially categorized as a form of ILOCA with cerebellar-plus syndrome or sporadic olivo-ponto-cerebellar atrophy (OPCA).^{10,11} Soon after, the combination of cerebellar ataxia, bradykinesia, and rigidity without tremor, hyperreflexia, spasmodic dysphonia, urinary urgency, disproportionate anterocollis, slowed eye saccades, and impairment of postural reflexes led us to establish a working diagnosis of MSA,¹² and as such was preliminarily reported.¹³ As reported here, a good initial motor response to L-dopa occurs in a third of parkinsonian

MSA patients, which may be sustained until death in 7% of them.¹⁴ Such L-dopa-responsive parkinsonism in MSA is accounted for by preservation of the putamen and striatal D₂ sites.^{15,16} Appearance of florid lower motor neuron signs mimicking ALS described here is a feature departure from both sporadic OPCA and MSA.^{11,12} On that score, a couple of clinicopathological descriptions, apparently breaking current diagnostic dogma, merit a brief comment.^{17,18}

Kulawik and colleagues¹⁷ reported on a sporadic OPCA patient who, at 59 years of age, developed a complex clinical picture characterized by cerebellar ataxia, parkinsonism, cognitive decline, sphincter disturbances, and hand and forearm amyotrophy. A diagnosis of ALS was given, which was not supported by an autopsy study, because olivo-ponto-cerebellar lesions were not accompanied by degeneration of anterior gray matter of the spinal cord. In retrospect, it is not possible to determine whether a misdiagnosis of ALS was made in this case. Be that as it may, subclinical degeneration of anterior horns of the spinal cord occurred in only 5 of 63 sporadic OPCA cases reviewed by Berciano.¹¹

Sima and coworkers¹⁸ described an MSA patient 34 years of age, who developed rapidly progressive motor neuron disease, nuclear ophthalmoplegia, and dysautonomic symptoms. Neuropathology showed extensive degeneration of brainstem and spinal motor nuclei, sympathetic and parasympathetic nuclei, striatonigral degeneration but with predominant involvement of globus pallidus, degeneration of inferior olivary nuclei, and glial inclusions localized in the white matter structures surrounding the putamen. Certainly this is a unique clinicopathological study and, as such, its atypical features for a diagnosis of MSA should be interpreted very cautiously.¹³

The general rule in inherited disorders that detailed investigation of the pedigree is an essential step in clinical diagnosis is applicable here. In effect, our initial evaluation comprised just examination of the proband and all her 4 daughters; furthermore, neither the parents nor grandparents were affected by history. Not surprisingly, we then gave a diagnosis of sporadic neurodegenerative disorder, namely MSA. Two years later, complete evaluation of the pedigree allowed us to detect four additional affected members and, therefore, to establish a diagnosis of ADCA type I. After screening the dynamic mutations associated with ADCA, a diagnosis of SCA2 was set up. Although the clinical picture, including intrafamilial variabil-

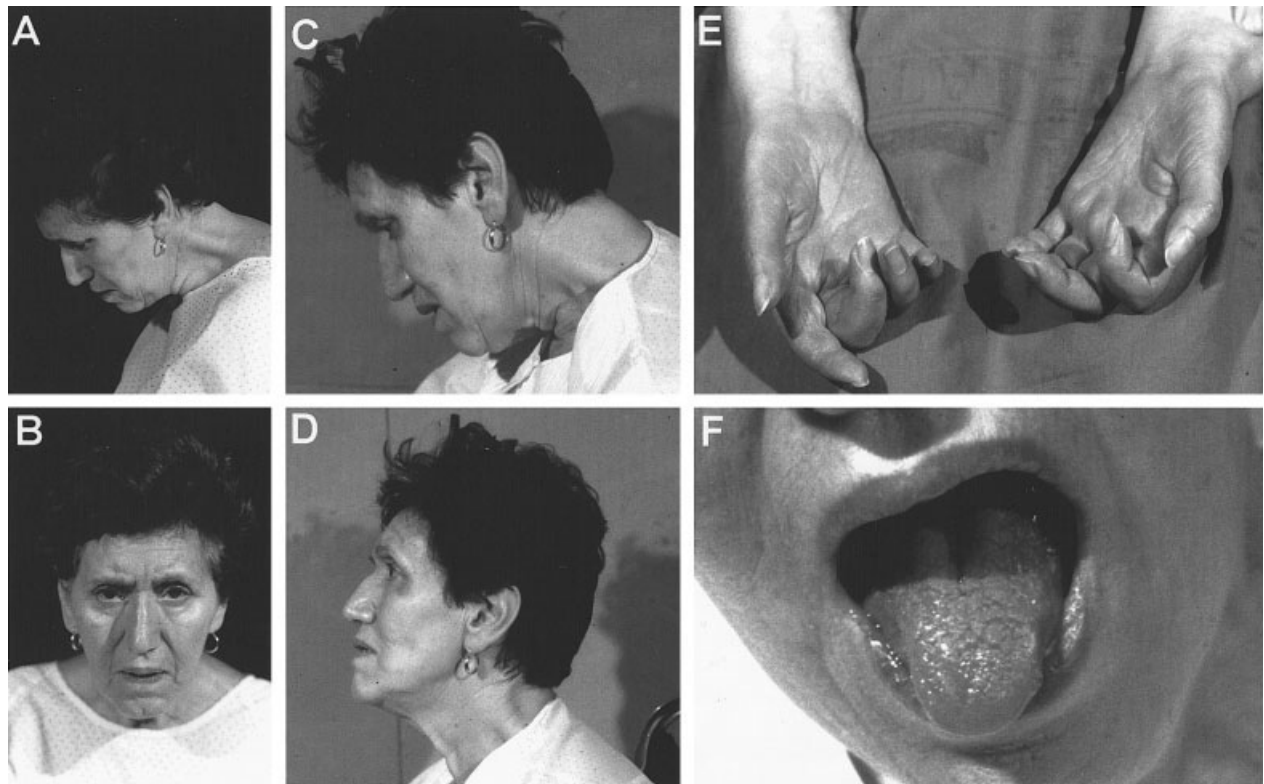


FIG. 2. Serial pictures of the proband taken in January 1995 (A,B) and February 1996 (C-F; see text for chronological appearance of semeiology). (A) Note pronounced anterocollis that her husband had noticed. (B) Impassive face. (C) Persistence of antecollis now accompanied by difficulty in head extension (D). Note wasting of muscles of hands (E) and tongue (F).

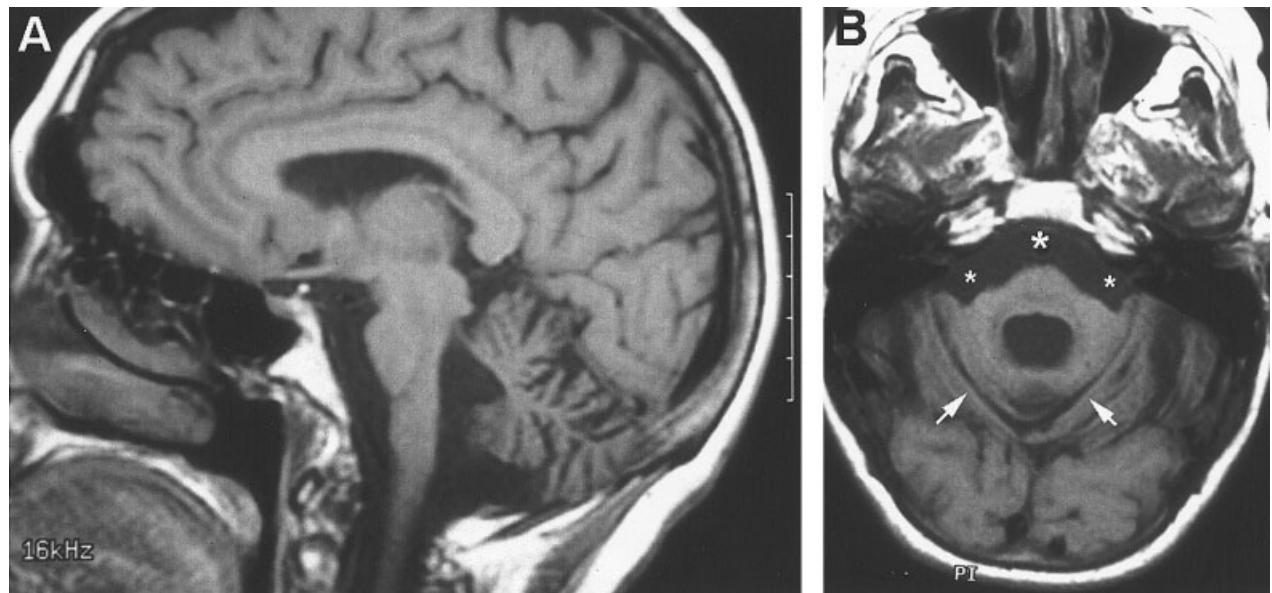


FIG. 3. Sagittal (A) and axial (B) magnetic resonance imaging pictures of proband. Note marked atrophy of brainstem and cerebellum, with enlargement of prepontine (large asterisk) and cerebellopontine (small asterisks) cisterns and hemispheric cerebellar sulci (arrows). Note also marked enlargement of the fourth ventricle.

ity, and neuroimaging findings observed in the present pedigree are comparable to those of other SCA2 studies,^{4–8,19} two outstanding manifestations in the proband, parkinsonism and amyotrophy, deserve a comment.

Autopsy studies in SCA2 have revealed constant loss of neurons in the substantia nigra, which is graded as moderate–severe⁴ or ranging between 91% and 33% of normal (mean reduction, 73%)²⁰; conversely, striatum is preserved or slightly involved. From these pathological data, it would be expected that most SCA2 patients, as occurred in our case, would show L-dopa–responsive parkinsonism. Intriguingly, this is not the case, as parkinsonian semeiology is reported to be absent in four series comprising 122 SCA2 patients^{4–6} or present in only 11 of 92 patients included in five other series^{7,21–24}; just in one study was bradykinesia/rigidity observed in one fifth of cases.²⁵ The reason for such a clinicopathological discrepancy remains unexplained; it may be that, like in OPCA, cerebellar-plus symptomatology could mask extrapyramidal rigidity and akinesia.¹¹ Corroborating our findings, extrapyramidal motor signs are more frequent in late-onset than in early-onset forms,^{22,25} although parkinsonism has been reported in a severe early SCA2 case with a large CAG triplet expansion.²⁵ As illustrated here, a SCA2 patient may be misdiagnosed as having MSA because of the absence of family history and presence of the constellation symptoms and signs characteristic of this disorder.²⁴ A further connection between parkinsonism and SCA2 has come from detecting SCA2 mutation in a reduced number of kindreds with familial L-dopa–responsive parkinsonism.^{26–30}

Two patients in the present pedigree showed a variable combination of fasciculations, amyotrophy, hyperreflexia, and extensor plantar responses, which in the proband led to quadriplegia and bulbar palsy; precisely, such coincidental semeiology argues in favour of a pathogenic role of the SCA2 mutation in the development of motor neuron dysfunction. Furthermore, fasciculations of the face, tongue, and limb muscles are common signs in most SCA2 pedigrees^{4–8,21–24,31}; distal amyotrophy may become prominent in late stages of the disease.³² A morphometric autopsy study in SCA2 showed reduction of lumbar motoneurons ranging between 33% and 83% of normal (mean, 57%) and of thoracic motoneurons between 27% and 64% (mean, 48%).²⁰ Pyramidal signs, not accompanied by degeneration of corticospinal tracts, are noted in approximately one third of SCA2 cases⁴; this gross clinicopathological disassociation is a well-established feature in OPCA.¹¹ In 1983, we reported a familial OPCA with 11 affected members in four generations whose proband patient, 27 years of age, showed a cerebellar-plus syndrome not including amyotrophy; autopsy revealed OPCA with extensive loss of motoneurons in the thoracic and lumbosacral sections of the spinal cord.³³ In a first cousin of the proband, then 31 years of age, we noted, in addition to cerebellar ataxia and slowed eye saccades, generalized fasciculations and amyotrophy. In 1982, examination of the proband's son, then 22 years of age, was normal. Six years later, he developed progressive ataxia, being chairbound since 2000. Yearly examinations since 1991 have revealed cerebellar-plus syndrome including facial myokymias, hyporeflexia and slowed eye saccades, and widespread fasciculations and amyotrophy in the last 4 years. Molecular study in this patient showed CAG repeat expansion in the SCA2 gene (39/23). In short, SCA2 may show the clinicopathological semeiology of upper and lower motor neuron disease, exceptionally mimicking ALS.

Disproportionate anterocollis has been noted in more than half of pathologically proved cases of MSA.³⁴ It does not seem to be due to weakness, because the neck can only with difficulty be passively and forcibly extended to its normal position, after which the chin rapidly drops back to the sternum.³⁴ To some degree, these characteristics occurred in our proband patient when the sign was first detected, although we could then extend the neck passively. One year later, however, florid signs of lower motoneuron dysfunction appeared, including weakness of neck flexor–extensor muscles. Retrospectively, we interpret that severe neck flexion was not due to dystonic disproportionate anterocollis but to early-onset dropped head syndrome symptomatic of her motor neuron disorder.³⁵

Acknowledgments: This work was supported by “Investigación en Red de las Enfermedades Neurológicas” (CIEN, CO3/06, ISCIII, Madrid, Spain) and by “Fondo de Investigación Sanitaria” (02/0027).

References

1. Pulst SM, Nechiporuk A, Nechiporuk T, et al. Moderate expansion of a normally biallelic trinucleotide repeat in spinocerebellar ataxia type 2. *Nat Genet* 1996;14:269–276.
2. Sanpei K, Takano H, Igarashi S, et al. Identification of the spinocerebellar ataxia type 2 gene using a direct identification of repeat expansion and cloning technique, DIRECT. *Nat Genet* 1996;14:277–284.
3. Imbert G, Saudou F, Ybert G, et al. Cloning of the gene for spinocerebellar ataxia 2 reveals a locus with high sensitivity to expanded CAG/glutamine repeats. *Nat Genet* 1996;14:285–291.
4. Dürr A, Smadja D, Cancel G, et al. Autosomal dominant cerebellar ataxia type I in Martinique (French West Islands). Clinical and neuropathological analysis of 53 patients from three unrelated SCA2 families. *Brain* 1995;118:1573–1581.
5. Bürk K, Abele M, Fetter J, et al. Autosomal dominant cerebellar ataxia type I. Clinical features and MRI in families with SCA1, SCA2 and SCA3. *Brain* 1996;119:1497–1505.
6. Filla A, De Michele G, Campanella G, et al. Autosomal dominant cerebellar ataxia type I. Clinical and molecular study of 36 Italian families including comparison between SCA1 and ACA2 phenotypes. *J Neurol* 1996;142:140–147.
7. Schöls L, Gispert S, Vorgerd M, et al. Spinocerebellar ataxia type 2. Genotype and phenotype in German kindreds. *Arch Neurol* 1997;54:1073–1080.
8. Giunti P, Sabbadini G, Sweeney MG, et al. The role of the SAC2 trinucleotide repeat expansion in 89 autosomal dominant cerebellar ataxia families. Frequency, clinical and genetic correlates. *Brain* 1998;121:459–467.
9. Pujana MA, Corral J, Gratacòs M, et al. Spinocerebellar ataxias in Spanish patients: genetic analysis of familial and sporadic cases. *Hum Genet* 1999;104:516–522.
10. Harding AE. “Idiopathic” late onset cerebellar ataxia. A clinical and genetic study of 36 cases. *J Neurol Sci* 1981;51:259–271.
11. Berciano J. Olivopontocerebellar atrophy. A review of 117 cases. *J Neurol Sci* 1982;53:253–272.
12. Quinn N. Multiple system atrophy. In: Marsden CD, Fahn S, editors. *Movement disorders*, 3. London: Butterworth-Heinemann; 1994. p 262–281.
13. Berciano J, Combarros O, Oterino A, Pascual J. Multiple system atrophy culminating in motor neuron disease. *Mov Disord* 1996; 11(Suppl.):26.
14. Wenning GK, Ben Shlomo Y, Magalhães M, Daniel SE, Quinn NP. Clinical features and natural history of multiple system atrophy. An analysis of 100 cases. *Brain* 1994;117:835–845.
15. Pascual J, Pazos A, del Olmo E, Figols J, Leno C, Berciano J. Presynaptic parkinsonism in olivopontocerebellar atrophy: clinical, pathological, and neurochemical evidence. *Ann Neurol* 1991;30: 425–428.

16. Berciano J, Valldeoriola F, Ferrer I, et al. Presynaptic parkinsonism in multiple system atrophy mimicking Parkinson's disease: a clinicopathological case study. *Mov Disord* 2002;17:812–816.
17. Kulawik H, Roitzsch E, Barz H. Zum Krankheitsbild der olivoponto-cerebellaren Atrophie (Dégérine-Thomas). *Psychiat Neurol Med Psychol (Leipzig)* 1972;3:119–127.
18. Sima AAF, Caplan M, D'Amato CJ, Pevzner M, Furlong JW. Fulminant multiple system atrophy in a young adult presenting as motor neuron disease. *Neurology* 1993;43:2031–2035.
19. Klockgether T, Skalej M, Wedekind D, et al. Autosomal dominant cerebellar ataxia type I. MRI-based volumetry of posterior fossa structures and basal ganglia in spinocerebellar ataxia types 1, 2 and 3. *Brain* 1998;121:1687–1693.
20. Estrada R, Galarraga J, Orozco G, Nodarse A, Auburger G. Spinocerebellar ataxia 2 (SCA2): morphometric analyses in 11 autopsies. *Acta Neuropathol (Berl)* 1999;97:303–311.
21. Sasaki H, Fukazawa T, Wakisaka A, et al. Central phenotype and related varieties of spinocerebellar ataxia 2 (SCA2): a clinical and genetic study with a pedigree in the Japanese. *J Neurol Sci* 1996;144:176–181.
22. Sasaki H, Wakisaka A, Sanpei K, et al. Phenotype variation correlates with CAG repeat length in SCA2. A study of 28 Japanese patients. *J Neurol Sci* 1998;159:202–208.
23. Ueyama H, Kumamoto T, Nagao S, Mita S, Uchino M, Tsuda T. Clinical and genetic studies of spinocerebellar ataxia type 2 in Japanese kindreds. *Acta Neurol Scand* 1998;98:427–432.
24. Lee WY, Jin DK, Oh MR, et al. Frequency analysis and clinical characterization of spinocerebellar ataxia types 1, 2, 3, 6, and 7 in Korean patients. *Arch Neurol* 2003;60:858–863.
25. Schöls L, Peters S, Szymanski S, et al. Extrapyrmidal motor signs in degenerative ataxias. *Arch Neurol* 2000;57:1495–1500.
26. Gwinn-Hardy K, Chen JY, Liu HC, et al. Spinocerebellar ataxia type 2 with parkinsonism in ethnic Chinese. *Neurology* 2000;55:800–805.
27. Shan DE, Soong BW, Sun CM, Lee SJ, Liao KM, Liu RS. Spinocerebellar ataxia type 2 as familial levodopa-responsive parkinsonism. *Ann Neurol* 2001;50:812–815.
28. Furtado S, Farrer M, Tsuboi Y, et al. SCA-2 presenting as parkinsonism in an Alberta family. Clinical, genetic, and PET findings. *Neurology* 2002;59:1625–1627.
29. Payami H, Nutt J, Ganchar S, et al. SCA2 may present as levodopa-responsive parkinsonism. *Mov Disord* 2002;18:425–429.
30. Lu CS, Chou YW, Yen TC, Tsai CH, Chen RS, Chang HC. Dopa-responsive parkinsonism phenotype of spinocerebellar type 2. *Mov Disord* 2002;17:1046–1051.
31. Pareyson D, Gellera C, Castellotti B, et al. Clinical and molecular studies of 73 Italian families with autosomal dominant cerebellar ataxia type I: SCA1 and SCA2 are the most common phenotypes. *J Neurol* 1999;246:389–393.
32. Bürk K, Stevanin G, Didierjean O, et al. Clinical and genetic analysis of three German kindreds with autosomal dominant cerebellar ataxia type I linked to the SCA2 locus. *J Neurol* 1997;244:256–261.
33. Berciano J, Ricoy JR, Rebollo M, Combarros O, Coria F, Val F. Atrofia olivopontocerebelosa familiar (tipo Menzel). A propósito de una estirpe seguida durante 46 años. *Arch Neurobiol (Madrid)* 1983;46:51–58.
34. Quinn N. Disproportionate antecollis in multiple system atrophy. *Lancet* 1989;1:844.
35. Gourie-Devi M, Nalini A, Sandhya S. Early or late appearance of "dropped head syndrome" in amyotrophic lateral sclerosis. *J Neurol Neurosurg Psychiatry* 2003;74:683–686.

Pregnancy in Stiff-Limb Syndrome

Stuart J.M. Weatherby, MD, MRCP¹
 Philippa Woolner, MBChB,¹
 and Carl E. Clarke, MD, FRCP^{1,2*}

¹Department of Neurology, City Hospital, Birmingham, United Kingdom

²University of Birmingham, Birmingham, United Kingdom

Abstract: To our knowledge, pregnancy in a patient with stiff-limb-syndrome (SLS) has not been reported. We present the case of a woman with SLS who improved during pregnancy, delivered a normal healthy baby by forceps-assisted vaginal delivery, and suffered a mild postpartum "relapse." © 2004 Movement Disorder Society

Key words: stiff-person syndrome; stiff-limb syndrome; pregnancy

Stiff-person and stiff-limb syndromes (SPS and SLS, respectively) are rare, related conditions characterised by muscle stiffness, rigidity, and spasms. An autoimmune pathogenesis has been postulated. To our knowledge, there is no previous reported case of pregnancy in a patient with either SPS or SLS. Management decisions, therefore, may be difficult in such a situation. We present the case of a 41-year-old woman with SLS who became pregnant.

Case Report

This 41-year-old woman was diagnosed with SLS at the National Hospital for Neurology and Neurosurgery in 1994 by Professor Marsden after a 4-year history of falls and lower limb muscle spasms. She eventually developed opisthotonos and severe falls with injuries as a result of stimulus-induced spasms. The patient noted that loud noises could precipitate spasm of the legs and that the rigidity and spasm became worse on standing or attempting to walk; her symptoms improved with alcohol and diazepam. There was no bladder or bowel disturbance, and the family history was unremarkable. When she was referred to us in 2002, examination revealed increased tone in the legs with brisk reflexes and bilateral flexor plantar responses; sensation was not affected, and examination of the cranial nerves and upper limbs was normal.

Investigations performed at the time of diagnosis included a full autoimmune screen which was negative; her anti-glutamic acid decarboxylase (GAD) antibody level was normal. The test was immunohistochemical, using IgG and IgM antibodies directed against rat cerebellum. Antibodies against isolated human Purkinje cells, cerebral cortex neurones, and central nervous system (CNS) white matter were also negative.

*Correspondence to: Dr. Carl E. Clarke, Neurology Department, City Hospital, Dudley Road, Birmingham B18 7QH, United Kingdom. E-mail: c.e.clarke@bham.ac.uk

Received 15 September 2003; Revised 9 December 2003; Accepted 5 January 2004

Published online 16 March 2004 in Wiley InterScience (www.interscience.wiley.com). DOI: 10.1002/mds.20094

Examination of the cerebrospinal fluid revealed oligoclonal bands. A magnetic resonance imaging scan and nerve conduction studies were normal. Electromyography revealed persistent motor unit firing in tibialis anterior and vastus, but not in the paraspinal muscles, consistent with a diagnosis of stiff-limb syndrome.

She was initially treated with baclofen and diazepam, which prevented further opisthotonus and most of her falls. A course of intravenous methylprednisolone gave little benefit. The possibility of intrathecal baclofen was considered at this time, but because the patient remained relatively well, she was kept on oral medication, remained clinically stable, and was able to hold down a busy job. She would use a wheelchair at work but, when at home, was able to move around the house using the support of rails and furniture. She was able to control most of the spasms with high doses of baclofen and diazepam (100 mg and 60 mg per day, respectively).

She became pregnant in 2002. The pregnancy itself was unremarkable; both maternal and foetal parameters remained within normal limits. One of our main concerns was the risk of side effects of both baclofen and diazepam on the foetus. However, the patient managed to reduce the dose of baclofen to 25 mg and diazepam to 15 mg per day. She was able to reduce her medication doses from the second trimester onward, as she found that her symptoms were improving significantly and her spasms, especially those in her legs, occurring less frequently. The birth itself was complicated by foetal distress, which required assisted forceps delivery. Although the patient had an epidural for analgesia, she developed a generalised spasm in response to the pain of the episiotomy. The baby remained well with no features of sedation or withdrawal fits, did not require any benzodiazepines and did not become drowsy, despite being breast fed.

After parturition, she deteriorated with increasing stiffness of the legs and stimulation-induced leg spasms. As a result, she increased the baclofen to 100 mg daily and the diazepam to 35 mg daily over 2 months, which improved the symptoms progressively, and the noise induced spasms that were particularly troublesome became less frequent. She remains optimistic that she can cope with her child, managing to nurse her on her lap while using the wheelchair. She is keen to have another baby, despite the limitations of her condition.

Discussion

SPS was first described in 1956 by Moersh and Woltman.¹ Initially, it affects the axial muscles leading to back discomfort but, as the condition progresses, proximal limb muscles become involved. Startle may lead to prolonged and painful spasms of both axial and limb muscles. Apart from the motor disorder, neurological examination is normal and intellect is preserved.

SPS has been subdivided into cases in which rigidity and spasms in the axial musculature dominate and those with spasm in one or more limbs, the so-called stiff limb syndrome; it has been suggested that SLS may be a condition distinct from SPS.^{2,3} A further and more unusual subgroup (progressive encephalomyelitis with rigidity) also has been described in which patients have a rapidly progressive condition characterised by widespread rigidity resulting in death in 6 to 16 weeks.³

The disease is sporadic: early suggestions that SPS was more common in males⁴ have not been substantiated in more recent studies.⁵ Insulin-dependent diabetes mellitus (IDDM) is asso-

ciated with SPS, the frequency of IDDM in patients with SPS having been estimated at more than 30 times that in the general population.⁵

SPS is associated in 70% of cases with serum autoantibodies to glutamic acid decarboxylase (GAD 65), the rate limiting enzyme for the synthesis of gamma-aminobutyric acid (GABA). An autoimmune pathogenesis within the CNS is suggested by the finding of intrathecal synthesis of anti-GAD IgG antibodies. Around 5% of patients have antibodies to amphiphysin and very rarely antibodies to gephyrin; the disease may be associated with cancer in this group.⁶ Anti-GAD 65 antibodies have been reported to be uncommon in SLS,⁵ and our patient was anti-GAD 65 negative. Nonetheless, an autoimmune process would appear likely for such patients, and the rationale for treatment (including for patients in whom autoantibodies have not been isolated) is based upon this premise. It is, however, important to note that recent series have suggested that anti-GAD 65 antibodies in SLS may be more common than previously recognized.⁷

To our knowledge, no case of pregnancy in a patient with SPS or SLS has been reported, so we had little evidence on which to base our counselling of the patient regarding care during pregnancy, delivery, the postnatal period, and care of the baby. One of our concerns was the possible risk of transplacental passage of putative autoantibodies causing a transient neonatal SPS, in a manner analogous to neonatal myasthenia gravis. The effects of baclofen and diazepam on the foetus were uncertain, and in addition, it was not known whether her disease would be affected by pregnancy and labour.

The clinical course of this patient during pregnancy is interesting: she improved during pregnancy but deteriorated soon after. Such a variation is in keeping with an autoimmune process and may be considered similar to the situation that occurs in multiple sclerosis, in which the rate of relapse decreases during pregnancy and increases in the first 3 months after delivery,⁸ which raises the possibility that sex hormones may act to modulate disease course in SPS. This possibility is not surprising, as exogenous steroids and intravenous immunoglobulin^{6,9} have proved an effective treatment for severe cases of SPS. We acknowledge, however, that it is also possible that the increase in severity after delivery may have been a return to baseline rather than a true relapse. In this context, it is important to note that, although the patient had to increase her medication after delivery, the increase did not reach prepregnancy levels.

That the patient was able to proceed with a vaginal delivery and delivered a healthy baby is encouraging for other GAD 65 antibody-negative women with SLS contemplating pregnancy. It is important to note that, despite the mother's medication, the newborn baby was not sedated or floppy. Assuming that an autoantibody is involved in GAD 65 antibody-negative cases of SLS, it would appear that they are either not causative or do not cross the placenta in sufficient quantities to cause significant clinical effects; clearly no conclusions can be drawn from this case regarding GAD 65 antibody-positive patients. We hope that this single case report and the tentative inferences herein may prove useful to other clinicians facing a similar situation.

References

1. Moersh FP, Woltman HW. Progressive fluctuating muscular rigidity and spasm ("stiff-man" syndrome): report of a case and some observations in 13 other cases. *Mayo Clin Proc* 1956;31:421-427.

- Brown P, Rothwell JC, Marsden CD. The stiff-leg syndrome. *J Neurol Neurosurg Psychiatry* 1997;62:31–37.
- Barker RA, Revesz T, Thom M, Marsden CD, Brown P. Review of 23 patients affected by the stiff man syndrome: clinical subdivision into stiff trunk (man) syndrome, stiff limb syndrome, and progressive encephalomyelitis with rigidity. *J Neurol Neurosurg Psychiatry* 1998;65:633–640.
- Gordon EE, Januszko DM, Kaufman L. A critical survey of stiff man syndrome. *Am J Med* 1967;42:582–599.
- Blum P, Jankovic J. Stiff person syndrome: an autoimmune disease. *Mov Disord* 1991;6:12–20.
- Vasconcelos OM, Dalakas MC. Stiff-person syndrome. *Curr Treat Options Neurol* 2003;5:79–90.
- Meinck HM, Thompson PD. Stiff man syndrome and related conditions. *Mov Disord* 2002;17:853–866.
- Confavreux C, Hutchinson M, Hours MM, Cortinvis-Tourniaire P, Moreau Th, and the Pregnancy in Multiple Sclerosis Group. Rate of pregnancy-related relapse in multiple sclerosis. *N Engl J Med* 1998;339:285–291.
- Wiles CM, Brown P, Chapel H, et al. Intravenous immunoglobulin in neurological disease: a specialist review. *J Neurol Neurosurg Psychiatry* 2002;72:440–448.

Markedly Asymmetrical Parkinsonism as a Leading Feature of Adult-Onset Huntington's Disease

Shih-Ching Wang, MD,¹ Guey-Jen Lee-Chen, PhD,² Cheng-Kung Wang, MD,^{2,3} Chiung-Mei Chen, MD, PhD,¹ Lok-Ming Tang, MD, MSc,¹ and Yih-Ru Wu, MD^{1*}

¹Second Department of Neurology, Chang Gung Memorial Hospital, LinKou Medical Center, Taipei, Taiwan

²Department of Life Science, National Taiwan Normal University, Taipei, Taiwan

³Jen-Teh Junior College of Medicine, Nursing and Management, Miaoli, Taiwan



Abstract: We report on a 28-year-old man who presented with right hand tremor, bradykinesia, and rigidity of his right side extremities. Our case report emphasizes that markedly asymmetrical parkinsonism can be an initial presentation of adult-onset Huntington's disease (HD), and different clinical presentations can be observed in members of an individual HD family with the same CAG repeat length. © 2004 Movement Disorder Society

Key words: hemiparkinsonism; Huntington's disease; anticipation

This article includes Supplementary Video, available online at <http://www.interscience.wiley.com/jpages/0885-3185/suppmat>

*Correspondence to: Dr. Yih-Ru Wu, Second Department of Neurology, Chang Gung Memorial Hospital, 199, Tung Hwa North Road, Taipei, Taiwan. E-mail: yihruwu@adm.cgmh.org.tw

Received 20 August 2003; Revised 11 December 2003; Accepted 6 January 2004

Published online 16 March 2004 in Wiley InterScience (www.interscience.wiley.com). DOI: 10.1002/mds.20093

Huntington's disease (HD) is an autosomal dominant neurodegenerative disorder caused by an unstable expansion of a CAG trinucleotide repeat in the *IT15* gene in the short arm of chromosome 4.¹ The classic presentation includes midlife onset of chorea, dementia, personality disorders, and a positive family history; dystonia and parkinsonism features usually appear later in the disease as it progresses.² A small number of patients may present with motor symptoms other than chorea.^{3,4} The "Westphal" variant is usually seen in juvenile-onset HD, and rarely seen in adult-onset disease. The phenotype is characterized by akinesia, rigidity, conspicuous mental deterioration, seizures, myoclonus, dystonia, pyramidal signs with rapid deterioration, and an affected father.⁵ Hemiparkinsonism is very rare in HD. We report a patient with genetically confirmed HD who had asymmetric parkinsonism as an initial presentation.

Case Report

A 28-year-old, right-handed man who had been well until the age of 26 years, when he developed involuntary tremor-like movements of his right hand. These tremors occurred mainly during action, rarely at rest, and could not be suppressed voluntarily. He noted gradual onset of stiffness in his right hand and difficulty in performing daily activities such as using chopsticks and writing. One year later, he developed clumsiness in his right leg during walking and his gait became slow and unsteady. He worked in a factory where he has not been exposed to solvents or any toxin. Between the age of 25 and 27, he developed an anxiety state and his social status deteriorated with suspiciousness with aggression. There was no history of encephalitis or exposure to neuroleptics antiemetics or herbicide. His father and his paternal aunt were thought to have stroke and psychosis, respectively.

On physical examination, the patient was alert and oriented. His mentality was good and language ability was preserved. He had a masked face, his speech was fluent, and there were no Kayser–Fleischer (KF) rings. Neurological examination was unremarkable except a postural and action tremor in his right hand, cogwheel rigidity and dystonia in his right wrist, bradykinesia of both limbs, more severely involved on the right, and decreased arm swing on the right side. No myoclonus or chorea was seen. Neuropsychological assessment revealed normal social function but with significant cognitive deficits, including verbal learning, executive function, visual perceptual function, and some psychopathological manifestations of obsessive–compulsive symptoms and hostility such as suspiciousness with aggression and loss of temper.

Normal or negative laboratory investigations included thyroid function, vitamin B12 level, blood copper and ceruloplasmin values, antinuclear antibody, and acanthocyte screen. Magnetic resonance image scan of the brain was normal, with no atrophy of cerebrum or striatum.

The patient was initially diagnosed as young-onset Parkinson's disease. Treatment with carbidopa/levodopa (25/100 mg) and pergolide (0.25 mg) three times a day produced a moderate motor improvement, including reduction of tremor and bradykinesia and improvement in gait. He had no untoward effects from the dopaminergic treatment. Because of an uncertain family history and lack of significant benefit from levodopa (L-dopa), genetic tests for HD, spinocerebellar ataxia (SCA) type 1–3,6–8,10,12,17 and dentatorubro-pallidolusian atrophy (DRPLA) were carried out. Screening for the expansion mutation in the HD gene by polymerase chain reaction assay re-

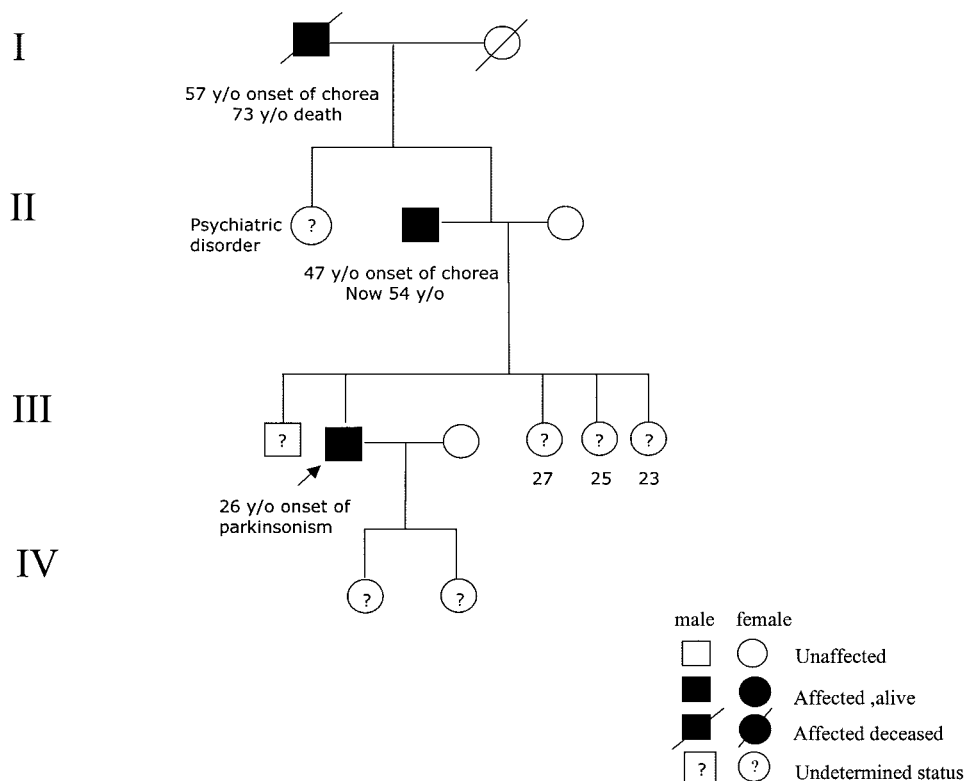


FIG. 1. Pedigree of the family. Arrow indicates the proband; black symbols denote affected persons; unaffected individuals are represented by unblackened symbols. Symbols with slashes represent deceased individuals; symbols with a question mark represent individuals with undetermined status.

vealed one allele containing 23 repeats and another allele containing 44 repeats confirming the diagnosis. Later, his father was proven to have HD carrying 2 alleles with 17 repeats and 44 repeats, respectively (Fig. 1). He had chorea, dementia, and some cognitive deficits typical of HD. At 2-years follow-up, the patient has continuing L-dopa responsiveness and no deterioration in cognitive function.

Discussion

We report on an adult-onset HD patient having marked asymmetrical, partially dopa-responsive parkinsonism without chorea, which is unusual. Although genetic testing was consistent with HD, other diseases may coexist. *Parkin* disease was considered in this case, the key clinical features being young age at onset (usually <40 years), foot dystonia, psychiatric symptoms, dramatic response to L-dopa treatment, and dose-dependent motor and psychiatric complications of drug therapy.^{6,7} This patient received carbidopa-L-dopa and pergolide for 2 years and obtained only moderate improvement in his tremor, bradykinesia, and unsteady gait, which made this diagnosis unlikely. Other confounding diagnoses, including drug-induced parkinsonism, Wilson's disease, neuroacanthocytosis, SCA, and DRPLA, were excluded by the history and laboratory test.

HD is generally regarded as a hyperkinetic syndrome. Besides chorea, patients with HD show a marked impairment of voluntary movement, which includes akinesia (inability to ini-

tiate), bradykinesia (slow execution of movement), and hypokinesia (reduction of movement).⁸⁻¹¹ Albin and colleagues¹² found a profound nonselective loss of all striatal projection neurons, including those projecting to the globus pallidus externa, globus pallidus interna (GPi), and substantia nigra (SN) in akinetic rigid HD with no reduction of neurons containing tyrosine hydroxylase in the SN, whereas those patients with HD with chorea had relative preservation of projections to the GPi. As nigrostriatal neurons containing dopamine were presumably preserved, the authors argued that the additional degeneration of the direct pathway might underlie the parkinsonian HD phenotype.

Patients with the late-onset hypokinetic-rigid form of HD have been reported to benefit from L-dopa.^{13,14} Therefore, we assumed the mechanism of L-dopa responsiveness is due to partially restore the activity of striatal projection neurons to the GPi. It is unusual for the patient and his father to have different clinical presentations but carry the same number of CAG triplets (47) on the *IT15* gene. The lack of anticipation in this family is also an uncommon feature.¹⁵

In conclusion, genetic examination is a useful diagnostic tool in patients with atypical forms of HD, especially in those with a family history of neurological or psychological disorders. L-Dopa-responsive, markedly asymmetrical parkinsonism may also be a presenting feature of adult-onset HD. Our patient further broadens the considerable clinical heterogeneity of movement disorders reported in late-onset HD.

Acknowledgments: We thank Professor Anthony E. Lang, Director of Movement Disorders Clinic, Toronto Western Hospital, for his invaluable assistance, and we also thank the participating patient for his cooperation.

Legend to the Video

Facial expression and the speech are normal. Moderate bradykinesia and rigidity, and mild action and postural tremor of the right hand are seen. Decreased arm swing and dystonic posturing of his right arm are noted during walking. Mild slowness of movement is also present in the left side.

References

1. A novel gene containing a trinucleotide repeat that is expanded and unstable on Huntington's disease chromosomes. The Huntington's Disease Collaborative Research Group. *Cell* 1993;72:971–983.
2. Louis ED, Lee P, Quinn L, Marder K. Dystonia in Huntington's disease: prevalence and clinical characteristics. *Mov Disord* 1999; 14:95–101.
3. Squitieri F, Berardelli A, Nargi E, et al. Atypical movement disorders in the early stages of Huntington's disease: clinical and genetic analysis. *Clin Genet* 2000;58:50–56.
4. Di Maio L, Squitieri F, Napolitano G, Campanella G, Trofater JA, Conneally PM. Onset symptoms in 510 patients with Huntington's disease. *J Med Genet* 1993;30:289–292.
5. Bittenbender JB, Quadfasel FA. Rigid and akinetic forms of Huntington's chorea. *Arch Neurol* 1962;7:275–288.
6. Shimura H, Hattori N, Kubo SI, et al. Familial Parkinson disease gene product, parkin, is a ubiquitin-proteinligase. *Nat Genet* 2000; 25:302–305.
7. Khan NL, Graham E, Critchley P, et al. Parkin disease: a phenotypic study of a large case series. *Brain* 2003;126(Pt 6):1279–1292.
8. van Vugt JP, van Hilten BJ, Roos RA. Hypokinesia in Huntington's disease. *Mov Disord* 1996;11:384–388.
9. van Vugt JP, Siesling S, Piet KK, et al. Quantitative assessment of daytime motor activity provides a responsive measure of functional decline in patients with Huntington's disease. *Mov Disord* 2001; 16:481–488.
10. Berardelli A, Noth J, Thompson PD, et al. Pathophysiology of chorea and bradykinesia in Huntington's disease. *Mov Disord* 1999;14:398–403.
11. Garcia Ruiz PJ, Gomez Tortosa E, Sanchez Bernados V, Rojo A, Fontan A, Garcia de Yébenes J. Bradykinesia in Huntington's disease. *Clin Neuropharmacol* 2000;23:50–52.
12. Albin RL, Reiner A, Anderson KD, Penney JB, Young AB. Striatal and nigral neuron subpopulations in rigid Huntington's disease: implications for the functional anatomy of chorea and rigidity-akinesia. *Ann Neurol* 1990;27:357–365.
13. Racette BA, Perlmutter JS. Levodopa responsive parkinsonism in an adult with Huntington's disease. *J Neurol Neurosurg Psychiatry* 1998;65:577–579.
14. Reuter I, Hu MT, Andrews TC, Brooks DJ, Clough C, Chaudhuri KR. Late onset levodopa responsive Huntington's disease with minimal chorea masquerading as Parkinson plus syndrome. *J Neurol Neurosurg Psychiatry* 2000;68(2):238–241.
15. Ashizawa T, Wong LJ, Richards CS, Caskey CT, Jankovic J. CAG repeat size and clinical presentation in Huntington's disease. *Neurology* 1994;44:1137–1143.

Distressing Belching and Neuroacanthocytosis

Igor Sibon, MD,* Imad Ghorayeb, MD, PhD,
Pierre Arné, MD, and François Tison, MD, PhD

*Fédération de Neurosciences Cliniques, Centre Hospitalier
Universitaire Bordeaux, Bordeaux-cedex, France*



Abstract: We report on an uncommon manifestation of molecularly proven neuroacanthocytosis in a 32-year-old man in whom dyspnea with desaturation while awake accompanied by continuous involuntary belching were the major consequences of the disease. © 2004 Movement Disorder Society

Key words: neuroacanthocytosis; belching

Belching is a complex physiological action due to gastropharyngeal reflux of air. Although mostly associated with gastrointestinal disorders,¹ it occasionally accompanies movement disorders such as Parkinson's disease (PD) and Huntington's disease (HD).^{2,3} Neuroacanthocytosis (CA) is an autosomal recessive movement disorder caused by several mutations in the CHAC gene on 9q21.⁴ The classic clinical picture of CA includes movement disorders (mainly chorea, epileptic seizures, cognitive deterioration, peripheral neuropathy) and some psychiatric manifestations.⁵ Although the orofacial region is often affected by choreic movements, tics, lip and tongue biting, continuous belching has not been reported in CA. We report on a patient with molecularly confirmed CA who developed progressive distressing belching and suggest that this curious disorder may be due to complex dystonic contractions of the diaphragm leading to abnormal respiratory rhythms and aerophagia.

Case Report

A 32-year-old, right-handed North African man presented with longstanding continuous belching. For the previous 7 years he had had chorea, dysarthria, and recurrent generalized epileptic seizures controlled by gabapentin (1,800 mg/day) and phenobarbital (100 mg/day). Fresh blood smear of the patient disclosed 10% acanthocytes. He had one sister who died at the age of 30 years with disabling movement disorders and another who currently presented with chorea, cerebellar signs, and psychiatric disturbances with self-aggressive behavior. Both were born from parental consanguinity.

Screening for the CHAC gene mutation by polymerase chain reaction assay revealed the same intronic mutation as that

This article includes Supplementary Video, available online at <http://www.interscience.wiley.com/jpages/0885-3185/suppmat>

*Correspondence to: Dr. Igor Sibon, Service de Neurologie, Hôpital Pellegrin, Place Amélie Raba-Léon, 33076 Bordeaux cedex, France. E-mail: igor.sibon@chu-bordeaux.fr

Received 15 September 2003; Revised 10 December 2003; Accepted 9 January 2004

Published online 16 March 2004 in Wiley InterScience (www.interscience.wiley.com). DOI: 10.1002/mds.20091

A

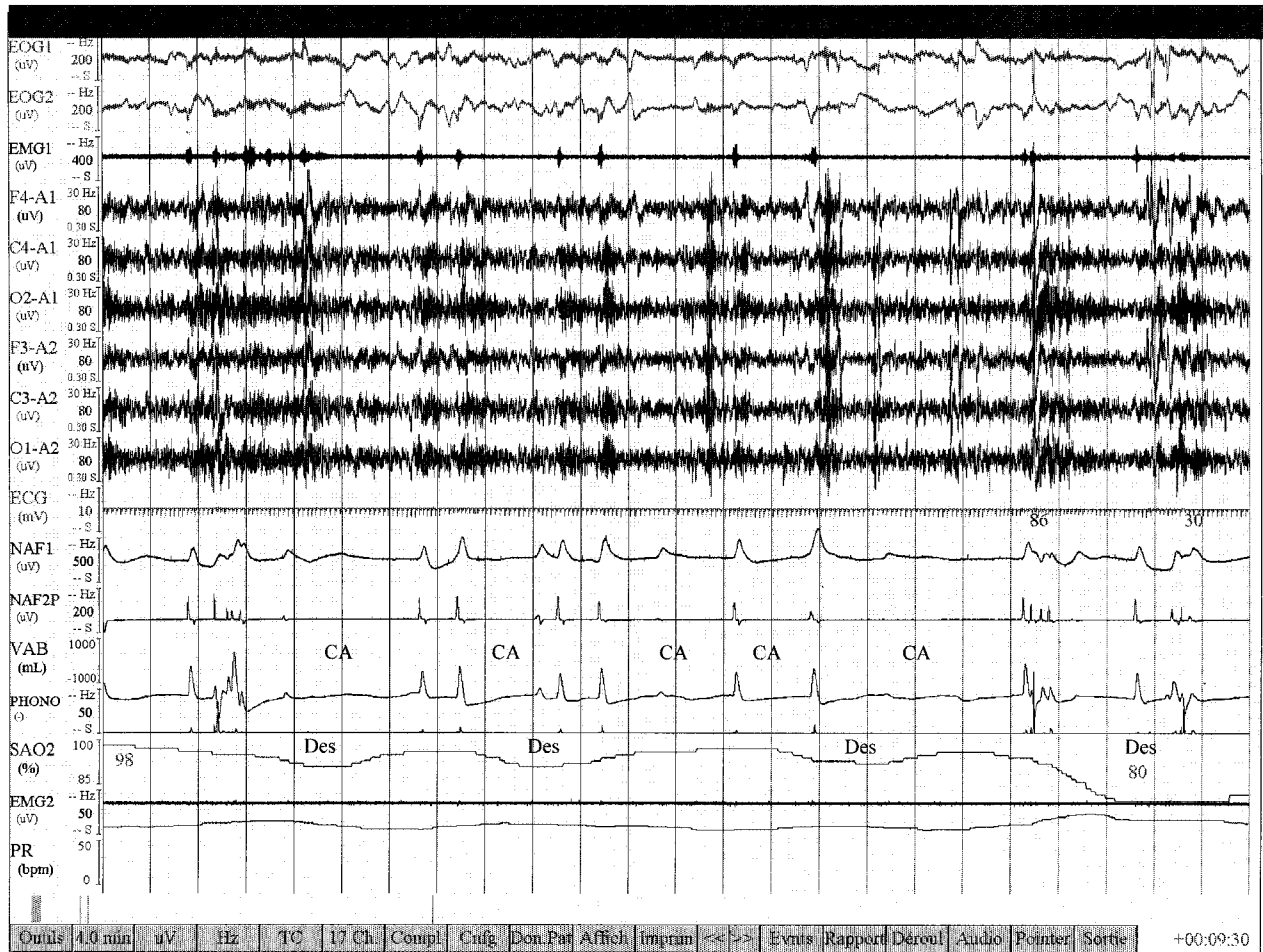


FIG. 1. A: Four-minute polysomnographic recording during wakefulness and drowsiness showing an irregular breathing pattern with prolonged central apnea and recurrent desaturation. CA, central apnea; Des, desaturation. **B:** Four-minute polysomnographic recording during stage 2 of sleep, showing regular breathing pattern without apnea or desaturation. (EOG, electro-oculogram; EMG1, chin electromyogram; ECG, electrocardiogram; NAF1, nasobuccal airflow (thermistance); NAF2, nasal airflow pressure; VAB, abdomino-thoracic effort; Phono, microphone; SAO2, oxygen saturation; EMG2, tibialis anterior electromyogram; PR, pulse rate). Scale bar = 10 sec.

found in his sister, which led to the molecular confirmation of CA (intron 26; 4242+1G>T; leading to aberrant splicing). On examination, lower limb deep tendon reflexes were absent, as well as moderate cerebellar signs (limb ataxia) and mild cognitive deterioration; chest radiography was normal as was a magnetic resonance imaging brain scan. Electroencephalography showed bilateral slow waves without epileptic features. For a year he had had continuous and distressing tasteless belching associated with aerophagia without swallowing disorders, dysphagia, or other symptoms of gastroesophageal reflux. The frequency of the belching had increased over that time and was affected by posture as belching only disappeared when the patient was in the supine position, whether asleep or not (see Video, Segment 1). He also had concomitant and recurrent episodes of dyspnea presenting as sensations of shortness of breath. Abdominal radiography showed air dilatation of the entire gastrointestinal tract. Endoscopy of the upper gastrointestinal tract was normal. Videofluoroscopy showed normal

deglutition and swallowing process with slight hypotonia of the inferior esophageal sphincter (IOS) that was confirmed by esophageal manometry. All-night polysomnography (PSG) with audio and video monitoring revealed irregular episodes of involuntary deep inspiration breathing followed by central apneas with arterial oxygen desaturation (up to 88%), then belching (Fig. 1A). These episodes occurred during wakefulness and were influenced by body position changes, speech, and effort, and persisted with attenuation during drowsiness. They disappeared during deep sleep, while a regular respiration pattern was noted with no oxygen desaturation (Fig. 1B). Electromyography of the diaphragmatic muscle with concentric needle electrodes did not disclose any diaphragmatic flutter, but did demonstrate repetitive recurrent arrhythmic and prolonged contractions of both diaphragmatic domes, concomitant with breathing irregularities (Fig. 2); phrenic nerve latencies were normal. Several treatment strategies failed to control the belching, including trials with neuroleptics, benzodiazepine, and

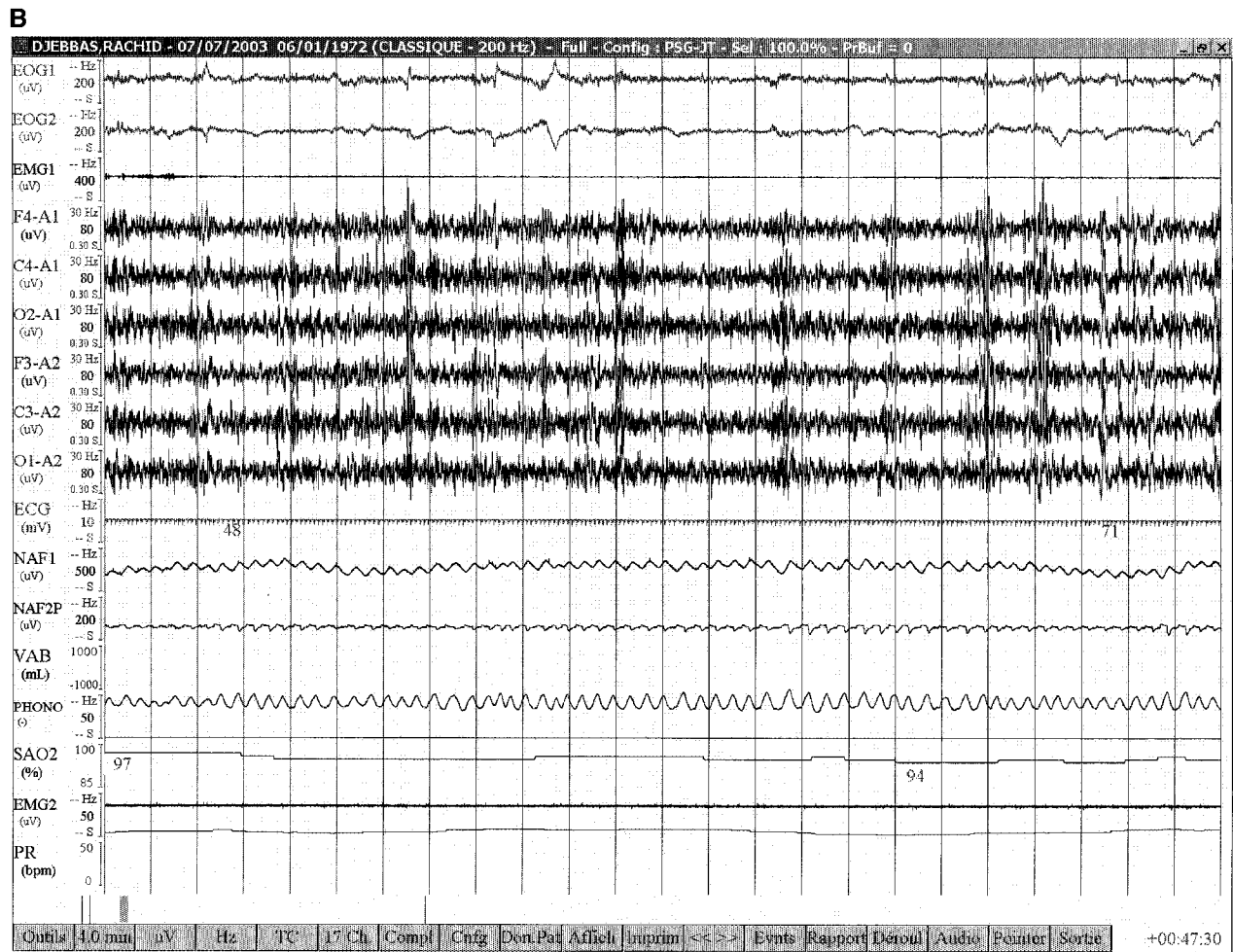


FIGURE 1. (Continued)

dopamine agonists, including apomorphine and levodopa (a L-dopa acute challenge test was performed with 250 mg of L-dopa/benserzide under fasting conditions and 2 days under domperidone, 60 mg/day).

Discussion

Belching is a physiological gastrointestinal activity that relieves distension of the gastric cardia and esophagus by oral expulsion of air inadvertently swallowed with meals.¹ Subjects

who complain of excessive belching are seldom found to have organic gastrointestinal disease and volitional aerophagia due to psychological factors may be suspected.^{6,7} Belching has already been encountered in neurodegenerative disorders, episodic belching during *off* periods with temporary improvement in response to L-dopa and apomorphine has been reported in 2 patients with PD.² Esophageal dystonia secondary to a disturbed striatal dopamine neurotransmission or Lewy body pathology in the dorsal vagal nucleus and the myenteric plexus

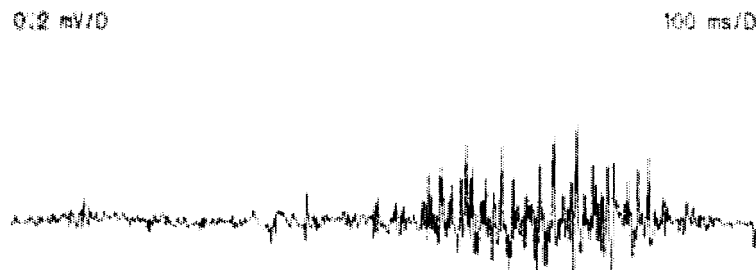


FIG. 2. Diaphragmatic electromyogram: arrhythmic prolonged contractions of the diaphragm during 250 msec with a 0.6 mV amplitude.

has been suggested as an underlying mechanism.⁸ Belching was also reported in a patient with HD with no response to dopamine agonists or neuroleptics.³ In CA, chorea is the most common movement disorder, but dystonia, tics, and parkinsonian features also occur.^{9,10} To our knowledge, involuntary belching has not been described previously in CA, and in our case, belching was the most disabling symptom of the disease. Gastroesophageal investigations did not disclose any disturbed upper oesophageal sphincter function nor esophageal abnormalities such as spasmodic contractions as previously described in PD and HD cases.^{2,3} Moreover, no improvement, as previously described in belching associated to PD was observed after L-dopa treatment.² However, EMG revealed abnormal contractions of the diaphragmatic muscle, suggesting focal diaphragmatic dysfunction that can be characterized as a dystonic movement disorder. This was further confirmed by PSG showing bursts of irregular breathing rhythm with central apneas. "Dystonic" breathing has been described in both primary and secondary dystonia¹¹ and was associated with spasmodic contractions of the upper airways and/or the diaphragm in most patients. Sleep and supine posture were associated with a reduction or cessation of belching and breathing irregularities, which is a common feature of dystonia and further underlines the diaphragmatic origin of these symptoms in our patient.

Indeed the phrenic nerve latencies were normal, as was the contractile response of the diaphragm, a finding which suggests that the peripheral nerve muscle axis is intact and favors a central origin of the diaphragmatic dysfunction observed in our patient. Abnormalities of striatal dopamine neurotransmission are well known both in CA and in PD and HD.¹² Evidence for disturbed dopaminergic neurotransmission in living patients with CA was provided by in vivo positron emission tomographic studies.¹² In addition, neuropathological studies revealed thalamic and nigral involvement, thus suggesting a role of the dopaminergic system in the occurrence of the movement disorders in CA.^{13,14} Our patient had no parkinsonian features but a slight chorea improved by neuroleptics, therefore pointing to a predominant postsynaptic striatal dysfunction accounting for the lack of efficacy of apomorphine. We suggest that diaphragmatic dystonic dysfunction of central origin is the primary disorder in our case, and this is further supported by postural modifications of belching occurrence. Consequent severe dysrhythmic respiration leading to aerophagia through hypotonic IOS may, at least in part, be responsible for this recurrent belching. However, a more complex origin of this rare disorder cannot be ruled out.

Legend to the Video

Recurrent belching and episodes of dyspnea.

References

1. Clearfield HR. Clinical intestinal gas syndromes. *Prim Care* 1996; 23:621–628. 2. Kempster PA, Lees AJ, Crichton P, Frankel JP, Shorvon P. Off-period belching due to a reversible disturbance of oesophageal motility in Parkinson's disease and its treatment with apomorphine. *Mov Disord* 1989;4:47–52.
2. Kempster PA, Lees AJ, Crichton P, Frankel JP, Shorvon P. Off-period belching due to a reversible disturbance of oesophageal motility in Parkinson's disease and its treatment with apomorphine. *Mov Disord* 1989;4:47–52.
3. Hu MT, Chaudhuri KR. Repetitive belching, aerophagia, and torticollis in Huntington's disease: a case report. *Mov Disord* 1998; 13:363–365.
4. Dobson-Stone C, Danek A, Rampoldi L, et al. Mutational spectrum of the CHAC gene in patients with chorea-acanthocytosis. *Eur J Hum Genet* 2002;10:773–781.
5. Critchley EM, Clark DB, Wikler A. An adult form of acanthocytosis. *Trans Am Neurol Assoc* 1967;92:132–137.
6. Levitt MD, Lasser RB, Schwartz JS, Bond JH. Studies of a flatulent patient. *N Engl J Med* 1976;295:260–262.
7. Zella SJ, Geenens DL, Horst JN. Repetitive eructation as a manifestation of obsessive-compulsive disorder. *Psychosomatics* 1998; 39:299–301.
8. Qualman SJ, Haupt HM, Yang P, Hamilton SR. Esophageal Lewy bodies associated with ganglion cell loss in achalasia. Similarity to Parkinson's disease. *Gastroenterology* 1984;87:848–856.
9. Hardie RJ, Pullon HW, Harding AE, et al. Neuroacanthocytosis. A clinical, haematological and pathological study of 19 cases. *Brain* 1991;114:13–49.
10. Spitz MC, Jankovic J, Killian JM. Familial tic disorder, parkinsonism, motor neuron disease, and acanthocytosis: a new syndrome. *Neurology* 1985;35:366–370.
11. Braun N, Abd A, Baer J, Blitzer A, Stewart C, Brin M. Dyspnea in dystonia. A functional evaluation. *Chest* 1995;107:1309–1316.
12. Brooks DJ, Ibanez V, Playford ED, et al. Presynaptic and postsynaptic striatal dopaminergic function in neuroacanthocytosis: a positron emission tomographic study. *Ann Neurol* 1991;30:166–171.
13. Rinne JO, Daniel SE, Scaravilli F, Harding AE, Marsden CD. Nigral degeneration in neuroacanthocytosis. *Neurology* 1994;44: 1629–1632.
14. Rinne JO, Daniel SE, Scaravilli F, Pires M, Harding AE, Marsden CD. The neuropathological features of neuroacanthocytosis. *Mov Disord* 1994;9:297–304.

Observations on the Human Rejection Behaviour Syndrome: Denny–Brown Revisited

Jason D. Warren, FRACP,¹ Michele T.M. Hu, MRCP, PhD,²
Malcolm Galloway, BSc, MBBS,³
Richard J. Greenwood, MD, FRCP,²
and Martin N. Rossor, MD, FRCP^{1,2*}

¹*Dementia Research Group, Institute of Neurology,
Queen Square, London, United Kingdom*

²*National Hospital for Neurology and Neurosurgery,
Queen Square, London, United Kingdom*

³*Division of Neuropathology, Institute of Neurology,
Queen Square, London, United Kingdom*



Abstract: The parietal avoiding–rejection behaviour syndrome, first described by Denny–Brown in the rhesus monkey, has been reported only rarely in humans. Here, we describe a patient with rejection behaviour in the setting of progressive cognitive decline accompanied by cortical myoclonus. © 2004 Movement Disorder Society

Key words: parietal avoiding syndrome; rejection behaviour; myoclonus

Denny–Brown and Chambers¹ described a neurobehavioural syndrome characterised by avoidance and withdrawal from visual and tactile stimuli after parietal lobe ablations in the rhesus monkey. Since their original description, a small number of human patients with a similar syndrome have been identified^{2–4} and the term “rejection behaviour” has been proposed.³ However, the human syndrome remains poorly characterized, and its pathophysiological basis is unclear. Affected individuals exhibit different types of avoiding responses that are organised at different levels of the motor hierarchy. These responses range from stereotyped flexion–withdrawal movements involving a single limb to elaborate avoiding behaviours. Associated clinical features are heterogeneous, including abnormalities of prehensile function,^{2,4} proprioceptive disturbances,² cortical visual and auditory disturbances,³ and rejection of food.³ The majority of cases have had extensive parietal or parietotemporal lesions, frequently bilateral.^{3,4} Several proposed human cases of avoiding phenomena have had a sensorimotor syndrome characterised by abnormal posturing of the limbs, cortical sensory deficits, and inability to manipulate objects,^{4,5–7} and it has been suggested that concurrent cortical sensory

deficits are necessary for true rejection behaviour to appear in humans.³ However, it is unclear whether such cases should be equated with the complex behavioural syndrome described in the monkey.³ Here, we describe a patient who developed rejection behaviour in the setting of progressive cognitive deterioration associated with stimulus-sensitive myoclonus and a paucity of cortical sensory signs.

Case Description

A 55-year-old, right-handed, retired painter and decorator presented with a 5-year history of increasing forgetfulness. He was unable to recall details of conversations, frequently misplaced items, and failed to keep appointments. During the 12 months before presentation, he had developed involuntary jerks of the limbs and trunk and found that he was unable to tolerate being touched by others, especially on the face, upper limbs, and trunk. His dislike of being touched gave rise to considerable apprehension on being approached: he would attempt to evade contact if possible, and would push others away if touch was sustained. Touch was not associated with pain or dysesthesias, and there were no other sensory symptoms; however, he had noticed a tendency for touch to trigger the limb and truncal jerks. There was no history of exaggerated startle or increased sensitivity to sound or light. During the 6 months before presentation, he had lost approximately a stone in weight (6.3 kg) and complained of generalised pruritus; there were no other systemic symptoms. His past history was unremarkable, and he took no medications. He was a smoker, and consumed occasional alcohol. His elder brother had been diagnosed with multiple sclerosis in middle life; there was no other family history of neurological or psychiatric illness.

On examination, he was severely impaired across a range of cognitive domains. Mini-Mental State Examination score was 13/30. He was distractible and mildly disinhibited, with impairment of frontal executive functions, including verbal fluency, proverb interpretation, motor sequencing, and set-switching. Spontaneous speech was fluent, however, there were phonemic and regularisation errors both in speaking and reading aloud, and naming was impaired. Visual and verbal recall were impaired. Calculation and perception of fragmented letters and pictures were impaired, but there was no evidence of visual disorientation. Bilateral upper limb dyspraxia was evident for both imitation of hand postures and pantomiming of learned actions, however, prehensile functions using either hand were normal. There were no primitive reflexes. Stimulus-sensitive multifocal myoclonus was present, involving the brows, ears, limbs, trunk, and abdominal wall and especially evident on lying down. Myoclonus could also be provoked by limb movements or by visual approach. There was mild supranuclear upgaze restriction and bilateral nonsustained gaze-evoked horizontal nystagmus but no palatal myoclonus or cranial nerve abnormalities. A mild cerebellar dysarthria was present. In the limbs, muscle bulk was generally reduced without focal wasting or fasciculations, and strength and coordination were normal. Tendon reflexes were normal and plantar responses were flexor bilaterally. Light touch, pin-prick, joint position, and vibration sense were normal. Cortical sensory functions, including stereognosis, graphaesthesia, and two-point discrimination were intact, and there was no evidence of sensory inattention or neglect. There was a mild cerebellar gait ataxia.

The patient displayed a profound intolerance of being touched, which was most pronounced over the face, mantle

This article contains Supplementary video available online at <http://www.interscience.wiley.com/jpages/0885-3185/suppmat>

*Correspondence to: Dr. Martin Rossor, Dementia Research Group, The National Hospital for Neurology and Neurosurgery, Queen Square, London WC1N 3BG, United Kingdom.

E-mail: m.rossor@dementia.ion.ucl.ac.uk

Received 26 August 2003; Revised 16 December 2003; Accepted 17 December 2003

Published online 4 March 2004 in Wiley InterScience (www.interscience.wiley.com). DOI: 10.1002/mds.20059

region, trunk, back, and both upper limbs. He became fearful when approached by either the examiner's hand or an object held beyond arm's reach (such as a tendon hammer) and would push the hand or object away if touch was sustained. A similar avoidance response was evident to a sound source (such as the examiner's voice) approaching from either side, and whether from the front or from behind the head. He denied any abnormality in the quality of touch. The symptoms were never provoked by his own touch or by clothing.

Neuropsychometry confirmed the clinical impression of severe global cognitive impairment; verbal IQ (68) and performance IQ (60) were both defective, and there were deficits of executive functions, verbal and visual memory, receptive language, and visual perception (affecting higher visual functions including perception of fragmented pictures but sparing early visual processing). Full blood count revealed a mild normochromic, normocytic anaemia (haemoglobin, 12.5 g/dl; range, 13–17 g/dl). There was a polyclonal increase in gammaglobulins, but no paraprotein was detected on electrophoresis. Serum chemistry, renal and liver function, and inflammatory markers were normal. Serological tests for syphilis, human immunodeficiency virus (HIV), and Lyme disease were negative. Antinuclear factor, anti-neutrophil cytoplasmic antibodies, anti-GAD antibodies, and anti-voltage-gated potassium channel antibodies were negative. Serum B12 was mildly reduced (156; range >180 ng/L). IgG anti-gliadin antibodies were positive, however, anti-endomysial antibodies were negative and there were no other features of malabsorption. On electroencephalography, there was mild slowing of alpha rhythm but no focal abnormalities and no epileptiform or periodic activity. Magnetic resonance imaging (MRI) of the brain revealed moderate generalised atrophy of both cerebral hemispheres and cerebellum, without regional predominance, and moderate periventricular and pontine small vessel ischaemic changes; MRI of the spinal cord was normal. Electrophysiological studies were normal; in particular, there was no evidence of denervation or neuromyotonia. Examination of the cerebrospinal fluid (CSF) revealed an inflammatory picture, with seven normal lymphocytes, and oligoclonal bands in both CSF and serum with an excess of bands in CSF; concentrations of protein and glucose in CSF were normal, 14-3-3 protein was negative, and Whipple's polymerase chain reaction was negative.

Serum immunohistochemistry revealed strongly positive staining against Purkinje cells and dorsal root ganglia, however, the identity of the antineuronal antibody could not be confirmed as Western blots were negative. Tumour markers (prostate-specific antigen, carcinoembryonic antigen, β -human chorionic gonadotropin, α -fetoprotein, CA-125, and CA-199) were not elevated. A chest radiograph suggested a subtle increase in density of the right mid-zone, however, computed tomography of chest and abdomen was normal and whole-body fluoro-deoxyglucose positron emission tomography showed no foci of abnormal uptake.

In view of the high clinical suspicion of a potentially treatable, inflammatory process, a right frontal full-thickness cerebral biopsy, including cortex, white matter, and overlying meninges, was performed. The leptomeninges and dura were normal. The cortex was mildly hypercellular, due to a diffuse astrogliosis and an increase in microglial cells; microglia showed positive CD68 and LCA staining with a dendritic morphology and were arranged either in focal nodules or diffusely spread in grey matter. Lymphocytic infiltrates were

prominent around some cortical vessels, however, there was no evidence of vasculitis or granulomatous inflammation. There were no intracellular inclusions. Bielschowsky staining for neurofibrillary pathology and immunocytochemical staining for prion proteins, β -A4, tau, α -synuclein, and ubiquitin were negative. Although not diagnostic, the inflammatory features, including activation of microglia with nodule formation and the presence of perivascular lymphocytic infiltrates, were compatible with paraneoplastic encephalitis.

An empirical trial of intravenous methylprednisolone (500 mg/day for 5 days) followed by oral prednisolone (80 mg/day for 3 days) produced no benefit. The patient's condition continued to deteriorate. Rejection behaviour for feeding developed: the patient would turn his head to avoid feeding, push the spoon away, or expel food from the mouth. A paraneoplastic syndrome with occult primary was considered the most likely diagnosis.

Discussion

In common with previous human cases of the rejection behaviour syndrome,³ this patient exhibited profound intolerance of touch, withdrawal from tactile, visual, and auditory approach, and later in the course of the illness, rejection of food. Unlike some previous cases,^{2–4} our patient had no difficulty using his hands to manipulate objects, and there were no abnormalities of proprioception, cortical visual, or auditory processing. His communicative capacities were initially preserved, providing an insight into the subjective accompaniments of the rejection behaviour syndrome: unlike patients with the thalamic syndrome of Dejerine and Roussy,⁸ he described touch as strange or unpleasant, rather than painful, and there was no alteration in the quality of touch per se. Although it was not possible to assess taste reliably in the later stages of the illness, it is possible that rejection of food was also a response to abnormal orolingual somatic sensation.

Associated clinical features, including dyscalculia and deficits of higher visual perception, implicate the inferior parietal lobes in the disease process,⁹ while the well-preserved visuomotor functions suggest that the superior parietal lobes were relatively spared.¹⁰ An inferior parietal localisation would be consistent both with previous studies of the rejection behaviour syndrome^{1,3} and with emerging evidence that the inferior parietal lobes play an important role in integrating information from multiple sensory (visual, tactile, and auditory) channels in both humans and non-human primates.^{6,11–15} To our knowledge, the avoiding responses to auditory approach displayed by our patient have not been described previously in this syndrome, however, they are in keeping with such a multisensory disturbance.

Stimulus-sensitive multifocal myoclonus was also a prominent feature here. Although the patient was unfortunately unable to tolerate detailed electrophysiological studies, it is likely that the myoclonus was primarily cortical in origin. Multifocal jerks occurring spontaneously or elicited by visual or other sensory stimuli may be associated with diffuse cortical pathological conditions^{16,17}; however, avoiding responses have not been described in previous cases of cortical myoclonus accompanied by marked stimulus sensitivity. Myoclonus in the present case could be precipitated by withdrawal movements of the limbs; the withdrawal response itself was highly organised and purposeful. With effort, the patient was sometimes able to tolerate sustained touch for several seconds before withdrawing. Moreover, the rejection of food that developed later in the illness could not be ascribed to myoclonus. It is, therefore,

unlikely that his rejection behaviour syndrome represented an elaborate form of myoclonus or an aversive response to myoclonus per se. Rather, we suggest that rejection behaviour and cortical myoclonus should be regarded as dual manifestations of disturbed cortical information processing.

In their original account of the parietal avoiding syndrome, Denny-Brown and Chambers¹ postulated that positive (exploratory) and negative (withdrawal) motor "tropisms," mediated by the parietal and frontal lobes, respectively, exist in equilibrium in the normal brain and that frontal withdrawal tropisms might be released after parietal lobe damage. In the present case, the pathological process was diffuse rather than focal and there were no associated clinical abnormalities of parietal motor or sensory functions: this finding suggests that an intrinsic alteration in cortical physiology, rather than a frontoparietal disconnection or deafferentation, can give rise to the rejection behaviour syndrome. Inflammatory,^{18,19} paraneoplastic,^{19,20} and infectious²¹ pathological states that disrupt information transfer between neurones may produce an electrophysiological lesion that manifests as a complex movement disorder or encephalopathy. Antibodies against voltage-gated potassium channels have been identified recently^{18,19} and illustrate one possible mechanism for such an electrophysiological disruption: however, these antibodies were not detected in the present case. Cortical myoclonus may reflect an intrinsic hyperexcitability of sensory cortex that results in abnormal processing of sensory traffic.^{16,17} On the basis of our observations in the present case, we argue that such abnormal processing may also give rise to the rejection behaviour syndrome. In certain contexts, distorted and "noisy" sensory processing can acquire a highly unpleasant subjective quality^{22,23}: in the somesthetic domain, abnormal processing of exogenous tactile signals might provoke both a cognitive and motor avoiding response. We propose that rejection behaviour can develop as a consequence of abnormal sensory integration in the inferior parietal lobe.

Acknowledgments: We thank the patient for participating in this study. We also thank Dr. Abha Ahuja of the Department of Neuropsychology, National Hospital for Neurology and Neurosurgery, for performing neuropsychometry.

Legends to the Video

The patient fears being touched, recoils from the examiner's hand, and pushes the hand away. Bilateral dyspraxia is evident on attempting to imitate hand positions; however, prehensile function (here manipulation of coins) is normal. Visual approach elicits synchronous myoclonic jerks affecting the proximal arms and upper body. Spontaneous myoclonus of the anterior abdominal wall is also prominent.

References

- Denny-Brown D, Chambers RA. The parietal lobe and behaviour. *Res Publ Assoc Res Nerv Ment Dis* 1958;36:35–117.
- Dehen H, Willer JC, Cambier J. Cutaneous reflexes in the avoidance reaction. *Eur Neurol* 1981;20:416–420.
- Mori E, Yamadori A. Rejection behaviour: a human homologue of the abnormal behaviour of Denny-Brown and Chambers' monkey with bilateral parietal ablation. *J Neurol Neurosurg Psychiatry* 1989;52:1260–1266.
- Vilensky JA, Gilman S. Positive and negative factors in movement control: a current review of Denny-Brown's hypothesis. *J Neurol Sci* 1997;151:149–158.
- Castaigne P, LaPlane D, Degos JD, Augustin P. Comportement tonique d'évitement d'origine sous-corticale. *Rev Neurol* 1971;124:166–168.
- LaPlane D, Meininger V, Bancaud J, Talairach J, Broglin D. Contribution à l'étude anatomo-clinique des phénomènes d'évitement. *Rev Neurol* 1979;135:775–787.
- De Smet Y, Theis C. Phénomène d'évitement provoqué par des accidents ischémiques transitoires. *Rev Neurol* 1990;146:705–706.
- Dejerine J, Roussy G. Le syndrome thalamique. *Rev Neurol* 1906;14:521–532.
- Simon O, Mangin JF, Cohen L, Le Bihan D, Dehaene S. Topographical layout of hand, eye, calculation and language-related areas in the human parietal lobe. *Neuron* 2002;33:475–487.
- Battaglia-Mayer A, Caminiti R. Optic ataxia as a result of the breakdown of the global tuning fields of parietal neurones. *Brain* 2002;125:225–237.
- Bohlhalter S, Fretz C, Weder B. Hierarchical versus parallel processing in tactile object recognition: a behavioural-neuroanatomical study of aperceptive tactile agnosia. *Brain* 2002;125:2537–2548.
- Bushara KO, Weeks RA, Ishii K, et al. Modality-specific frontal and parietal areas for auditory and visual spatial localization in humans. *Nat Neurosci* 1999;2:759–766.
- Warren JD, Zielinsky B, Green GGR, Rauschecker JP, Griffiths TD. Perception of sound source motion by the human brain. *Neuron* 2002;34:139–148.
- Banati RB, Goerres GW, Tjoa C, Aggleton JP, Grasby P. The functional anatomy of visual-tactile integration in man: a study using positron emission tomography. *Neuropsychologia* 2000;38:115–124.
- Poremba A, Saunders RC, Crane AM, Cook M, Sokoloff L, Mishkin M. Functional mapping of the primate auditory system. *Science* 2003;299:568–572.
- Obeso JA, Rothwell JC, Marsden CD. The spectrum of cortical myoclonus. From reflex jerks to spontaneous motor epilepsy. *Brain* 1985;108:193–224.
- Hallett M. Myoclonus: relation to epilepsy. *Epilepsia* 1985;26(Suppl. 1):S67–S77.
- Schott JM, Harkness K, Barnes J, Incisa della Rochetta A, Vincent A, Rossor MN. Amnesia, cerebral atrophy and autoimmunity: a treatable dementia associated with voltage-gated potassium channel antibodies. *Lancet* 2003;361:1266.
- Buckley C, Oger J, Clover L, et al. Potassium channel antibodies in two patients with reversible limbic encephalitis. *Ann Neurol* 2001;50:73–78.
- Roobol TH, Kazzaz BA, Vecht CJ. Segmental rigidity and spinal myoclonus as a paraneoplastic syndrome. *J Neurol Neurosurg Psychiatry* 1987;50:628–631.
- Warren JD, Kimber TE, Thompson PD. The silent period after magnetic brain stimulation in generalized tetanus. *Muscle Nerve* 1999;22:1590–1592.
- ffytche DH, Howard RJ. The perceptual consequences of visual loss: 'positive' pathologies of vision. *Brain* 1999;122:1247–1260.
- Griffiths TD. Musical hallucinosis in acquired deafness: phenomenology and brain substrate. *Brain* 2000;123:2065–2076.