

Emergency stent placement for symptomatic acute carotid artery occlusion after endarterectomy

Case report

STANLEY H. KIM, M.D., ADNAN I. QURESHI, M.D., ELAD I. LEVY, M.D.,
RICARDO A. HANEL, M.D., AMIR M. SIDDIQUI, M.D., AND L. NELSON HOPKINS, M.D.

Department of Neurosurgery and Toshiba Stroke Research Center, School of Medicine and Biomedical Sciences, University at Buffalo, State University of New York, Buffalo, New York; Neurosurgery, Endovascular, and Spine Center, Austin, Texas; and Department of Neurology and Neurosciences, University of Medicine and Dentistry of New Jersey, Newark, New Jersey

✓ The authors report a case of emergency carotid artery (CA) stent placement for a symptomatic acute CA occlusion following carotid endarterectomy (CEA). This 43-year-old man underwent a right-sided CEA for an asymptomatic 80% CA stenosis detected using duplex ultrasound testing. The patient experienced hypotension and possibly a myocardial infarction intraoperatively and a left hemiplegia immediately postoperatively. He was referred to the authors' institution for consideration of emergency coronary intervention and evaluation of stroke. A computerized tomography scan of the head demonstrated subtle early ischemic changes in the right posterior parietal region. Cerebral angiography revealed occlusion of the right common CA (CCA) at the CA bifurcation. Two coronary stents (Magic Wall; Boston Scientific Scimed, Maple Grove, MN) were placed in tandem in the right CCA and internal CA (ICA), overlapping at the proximal cervical ICA. Complete recanalization of the CA was achieved, and the patient made a clinically significant recovery. Diagnostic angiography can provide important information about CA and intracranial circulation that will aid in the evaluation of postoperative stroke after CEA. Stent placement should be considered as an alternative method of treatment for acute CA occlusion or dissection following CEA.

KEY WORDS • carotid artery occlusion • stent • endarterectomy • stroke

PROSPECTIVE, randomized clinical trials have demonstrated that CEA is an effective treatment that reduces the risk of stroke in symptomatic and asymptomatic patients with high-grade stenotic lesions of the CA bifurcation and extracranial ICAs.^{1,2} Nevertheless, in the NASCET, the incidence of perioperative disabling stroke at 30 days was found to be 1.8%.¹ Several reports have documented that acute thrombus at the endarterectomy site is a common cause of neurological deficit after CEA.^{5–10} Other causes include CA dissection, hypotension, embolization, and intracerebral hemorrhage. In some instances, the cause of stroke is unknown. Controversy exists as to which diagnostic tests should be performed and which definitive therapy is optimal. Immediate reoperation to explore the endarterectomy site for thrombus has led to mixed results. Recently, CA angioplasty with stent placement has emerged as an alternative treatment for CA dissection or occlusion. We report a case in which stent placement was used for the treatment of a symptomatic occlusion of the CA that occurred immediately after CEA.

Abbreviations used in this paper: AP = anteroposterior; CA = carotid artery; CCA = common CA; CEA = carotid endarterectomy; CT = computerized tomography; ICA = internal CA; MI = myocardial infarction; NASCET = North American Symptomatic CEA Trial; OPG/Gee = oculopneumoplethysmography/Gee.

Case Report

History and Examination. This 43-year-old right-handed man underwent a right-sided CEA for an asymptomatic 80% CA stenosis at another institution. The stenosis was detected using duplex ultrasonography testing. The patient's medical history was significant for an MI for which a stent had been placed in the right coronary artery 6 months before the CEA was performed. After the CA was clamped during the endarterectomy, the patient experienced acute hypotension, with systolic blood pressure ranging from 40 to 50 mm Hg. The hypotension was treated with vasopressors, and the operation was continued and completed. Immediately after surgery, the patient experienced a left hemiplegia while in the recovery room. Because of concern about possible inferior wall MI (on the basis of postoperative electrocardiogram findings), the patient was transferred to our institution for consideration of emergency coronary intervention. Nevertheless, the cardiologist determined that an acute MI had not occurred and that emergency coronary angiography was not needed. The patient was referred to the neuroendovascular service for evaluation of a perioperative stroke. Admission CT scans of the head revealed subtle early ischemic changes in the right posterotemporal parietal region in less than one third of the middle cerebral artery territory. Four hours after undergoing CEA, the patient remained intubated.

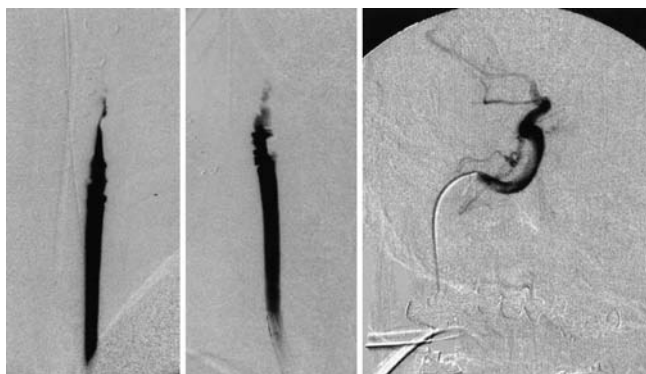


FIG. 1. Right CCA injection revealing occlusion of the right CCA in AP (*left*) and lateral cervical views (*center*). Microcatheter injection from the petrous portion of the ICA revealing the catheter in the true lumen of the artery (*right*).

ed and sedated; his blood pressure was maintained at 90/60 mm Hg with vasopressors. His left hemiplegia persisted. Consent was obtained from the patient's family for emergency cerebral angiography and possible endovascular intervention.

Procedure. A No. 6 French sheath was placed in the right femoral artery. A right CA angiogram revealed an occlusion of the right CCA at the carotid bifurcation (Fig. 1 *left* and *center*). A bolus of heparin (70 IU/kg) was administered intravenously to achieve an activated coagulation time of 300 seconds. A No. 6 French Envoy guide catheter (Cordis, Miami Lakes, FL) was then advanced over the guidewire into the CCA proximal to the occlusion. Then, a Prowler Plus microcatheter (Cordis) was coaxially advanced within the Envoy guide catheter over a microwire (Transcend EX; Boston Scientific Target, Fremont, CA) through the occluded right CCA to the distal cervical ICA. Angiography performed through the microcatheter provided assurance that the catheter was in the true lumen of the right ICA (Fig. 1 *right*). The distal, normal-appearing ICA measured 4.8 mm, and the CCA proximal to the bifurcation measured 5.6 mm. The Transcend EX microwire was exchanged with a Balance medium-weight microwire (Guidant; Advanced Cardiovascular, Inc., Temecula, CA). A 5 × 47-mm; coronary stent (Magic Wall; Boston Scientific Scimed, Maple Grove, MN) was placed from the distal to the proximal cervical ICA. A second Magic Wall coronary stent of the same size was then inserted overlapping the first one from the proximal cervical ICA to the CCA below the carotid bifurcation (Fig. 2 *left* and *center*). Recanalization of the right CCA and ICA was achieved; right CCA contrast angiography revealed excellent filling of the intracranial circulation (Fig. 2 *right*). No hemodynamic instability occurred during the procedure. The patient was kept intubated and was transferred to the intensive care unit.

Postprocedure Course. A 300-mg bolus of clopidogrel was administered through a nasogastric tube after the procedure. The patient was extubated the following day. He was maintained on a regimen of aspirin (325 mg daily) and clopidogrel (75 mg daily) after the procedure. A CT scan of the head obtained 24 hours after the CA stent placement revealed an infarction in the right posterior parietal region. The cardiologist determined that the patient had not experi-

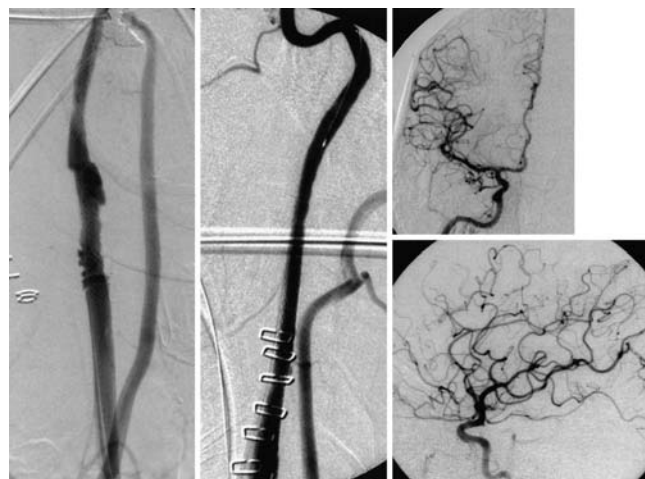


FIG. 2. Right CA angiogram following placement of tandem Magic Wall stents in the CCA and proximal cervical ICA seen in AP (*left*) and lateral (*center*) views. Excellent intracranial circulation is observed in AP (*upper right*) and lateral views (*lower right*) after CA stent placement.

enced an MI; the hypotension was thought to be related to CA clamping. The patient was transferred to a rehabilitation hospital on postoperative Day 10. Before discharge from that hospital, he was able to ambulate with assistance. At his 1-year follow-up evaluation, the patient had a modified Rankin Scale score of 3 and a patent right CA on carotid duplex ultrasonography.

Discussion

Perioperative stroke after CEA is uncommon, but the management of this complication has been controversial. In the NASCET, the overall rate of permanently disabling stroke and death was 2% at 90 days.⁴ There were nine (0.6%) stroke-related deaths and 13 (0.9%) permanently disabling strokes in the surgical group (1415 patients) at 90 days. Among the nine patients who died of stroke, eight suffered massive ipsilateral cerebral infarction. Seven of these nine patients were found to have an occlusion at the endarterectomy site, with the onset of stroke ranging from immediately postoperatively to 3 days afterward. Surgical exploration of the endarterectomy site was performed in four of these patients, with no benefit. In the group of 13 patients with permanently disabling strokes, seven awoke with a major deficit in the territory of the CEA. Two of these seven patients underwent exploration of the endarterectomy site; no abnormalities were found. In four of the 13 patients, the onset of stroke was delayed, ranging from 2 to 6 hours; removal of thrombus at the endarterectomy site resulted in no benefit. It is not clear how many of the six patients in whom CA reexploration was performed had undergone diagnostic tests such as cerebral angiography or carotid duplex ultrasonography before repeated operation. Poor outcome in some of the patients who underwent the second operation may have been a result of cerebral embolization or a delay in the timing of the operation.

In contrast to the poor results observed in the NASCET, others have emphasized the importance of urgent carotid reexploration and have reported successful results aided by

Stent placement for acute CA occlusion after endarterectomy

this approach.^{6,8,10} Nevertheless, many of these studies did not demonstrate a consistently reliable diagnostic tool with which to evaluate the mechanisms leading to cerebral ischemia. Diagnostic tests that have been used in the investigation of perioperative stroke after CEA include CT scanning of the head, carotid duplex or ultrasonography imaging, OPG/Gee, and cerebral angiography. More recently, emergency CA stent implantation for perioperative stroke occurring in 13 of 995 patients treated with CEA has been reported in the cardiac literature.³ Diagnostic angiography revealed dissection in five patients and definite or possible thrombus in eight patients. Our case adds to the number of patients whose perioperative stroke after CEA was treated with CA stent placement.

Although emergency reoperation is important, careful investigation of differential diagnoses in the management of acute perioperative stroke after CEA may be needed in select cases. Emergency reoperation will not benefit patients who suffer from ischemia resulting from clamping during CEA, from intracranial embolization, or intracerebral hemorrhage. Therefore, an emergency CT scan of the head to exclude the diagnosis of intracerebral hemorrhage and a carotid duplex or OPG/Gee study may be performed to screen for an obstructive CA lesion. Nevertheless, these noninvasive tests provide no information about intracranial embolization or the extent of CA thrombosis. Diagnostic angiography performed in a timely fashion may provide information about not only the endarterectomy site but also intracranial embolization and collateral circulation. Recent advance in the endovascular treatment of acute stroke, such as mechanical thrombolysis, may allow treatment of intracranial emboli.

At our institution, OPG/Gee is not routinely used. A CA duplex ultrasonography study could have been obtained in the patient reported here, but we proceeded with urgent diagnostic angiography to determine the status of the CA as well as the intracranial circulation. A microcatheter injection from the petrous portion of the ICA indicated that the occlusion probably extended from the CCA bifurcation up to the distal cervical ICA. The fact that placement of the stents resulted in recanalization of the CA indicated that an intimal flap might have been the cause of the occlusion. We considered using a distal protection device to capture any particles that might embolize distally during CA stent placement, but no such device was available at the time of the procedure. The Angiojet (Possis Medical, Inc., Minneapolis, MN), an endovascular thrombectomy device, could also have been used in this particular case, especially if the stent placement did not result in recanalization. Although no gross evidence of intracranial vessel occlusion was seen after CA stent placement, we cannot exclude the possibility that CA stent placement may have caused intracranial embolization (a potentially significant risk in this procedure). Intraarterial thrombolysis would be another alternative treatment, but the risk of a hemorrhagic complication in such a circumstance is unknown. Although stent placement resulted in complete recanalization of the CA, it is possible that the patient's outcome is not related to the procedure. Spontaneous recanalization of the occluded CA or devel-

opment of significant collateral blood supply to the region of the affected artery can result in improved neurological outcome.

The case reported here highlights the potential contribution of a diagnostic angiogram in the early investigation of postoperative stroke following CEA. The angiographic findings may aid the surgeon in the selection of the optimal treatment. This case also underscores the potential benefit of emergency CA stent placement in cases of acute CA dissection and occlusion. Advances in mechanical devices may provide promising treatment for cervical CA occlusion as well as intracranial emboli.

Disclosure

Dr. Hopkins receives research support from and is a consultant for Boston Scientific, Cordis, and Guidant; in addition, he has a financial interest in Boston Scientific and Guidant.

Acknowledgment

We thank Paul H. Dressel for preparation of the illustrations.

References

1. Anonymous: Beneficial effect of carotid endarterectomy in symptomatic patients with high-grade carotid stenosis. North American Symptomatic Carotid Endarterectomy Trial Collaborators. *N Engl J Med* **325**:445–453, 1991
2. Anonymous: Endarterectomy for asymptomatic carotid artery stenosis. Executive Committee for the Asymptomatic Carotid Atherosclerosis Study. *JAMA* **273**:1421–1428, 1995
3. Anzuini A, Briguori C, Roubin GS, et al: Emergency stenting to treat neurological complications occurring after carotid endarterectomy. *J Am Coll Cardiol* **37**:2074–2079, 2001
4. Ferguson GG, Eliasziw M, Barr HW, et al: The North American Symptomatic Carotid Endarterectomy Trial: surgical results in 1415 patients. *Stroke* **30**:1751–1758, 1999
5. Koslow AR, Ricotta JJ, Ouriel K, et al: Reexploration for thrombosis in carotid endarterectomy. *Circulation* **80**:III73–III78, 1989
6. Kwaan JH, Connolly JE, Sharefkin JB: Successful management of early stroke after carotid endarterectomy. *Ann Surg* **190**:676–678, 1979
7. Rosenthal D, Zeichner WD, Lamis PA, et al: Neurologic deficit after carotid endarterectomy: pathogenesis and management. *Surgery* **94**:776–780, 1983
8. Ross CB, Ranval TJ: Intraoperative use of stents for the management of unacceptable distal internal carotid artery end points during carotid endarterectomy: short-term and midterm results. *J Vasc Surg* **32**:420–428, 2000
9. Simma W, Hesse H, Gilhofer G, et al: Management of immediate occlusion after carotid-reconstruction. *J Cardiovasc Surg* **28**:176–179, 1987
10. Treiman RL, Cossman DV, Cohen JL, et al: Management of postoperative stroke after carotid endarterectomy. *Am J Surg* **142**:236–238, 1981

Manuscript received April 24, 2003.

Accepted in final form March 11, 2004.

Address reprint requests to: Stanley H. Kim, M.D., Neurosurgery, Endovascular, and Spine Center, 3303 Northland Drive, Suite 305, Austin, Texas 78731. email: stanleykim2001@hotmail.com.