

Generalized Spike-Wave Discharges with Focal Onset in a Patient with Head Trauma and Diffuse Cerebral Lesions: A Case Report with EEG and Cranial MRI Findings

F. Irsel Tezer, Nese Dericioglu and Serap Saygi

Key Words

Absence Seizures
Electroencephalography
Head Trauma
Magnetic Resonance Imaging

ABSTRACT

The role of cerebral lesions associated with absence seizures, outside the frontal lobe, has not been demonstrated by both electroencephalography and neuroimaging techniques until now, to our knowledge. We present a case with absence seizures and EEGs with generalized 3 Hz spike-wave patterns that were preceded by a burst of spike-waves on the right parieto-occipital region. The patient had a history of head trauma, and cranial MRI revealed lesions that might be responsible for the seizures. The patient's lateralized and localized EEG findings were probably a representation of secondary bilateral synchrony (SBS). The mechanism of SBS is considerably more complex than a simple triggering of generalized spike-wave complexes from a single cortical focus.

INTRODUCTION

Absence seizures are defined by impairment of consciousness concomitant with generalized, synchronous 3 Hz spike-wave complexes on normal background activity and are seen in age-related idiopathic epilepsies.¹ Typical absence seizures that were symptomatic due to tumors or other lesions have also been reported in the literature.^{2,7} The role of localized cortical areas, especially the frontal lobe, in these cases has been stressed. It was thought that secondary bilateral synchrony (SBS) was triggered due to these foci.⁸⁻¹³ Ictal EEGs with generalized 3 Hz spike-wave burst complexes preceded by focal spike-wave discharges were also reported in one patient with absence seizures.⁸ Although there was a focal finding in the ictal EEGs, the responsible lesions could not be demonstrated by neuroimaging techniques. The triggering of SBS from a lesion located outside the frontal lobe has not been demonstrated by EEG. We recently encountered a case whose EEGs showed a generalized 3 Hz spike-wave pattern beginning in the right parieto-occipital area during absence seizures. Cranial magnetic resonance imaging (MRI) showed lesions that might be responsible for the seizures.

Case Report

A 17-year-old male was admitted to our hospital for intractable seizures, which started at the age of 12. These consisted of staring, blinking, slight elevation of the right arm with partial loss of consciousness. They occurred 8-10 times a day and lasted for 10-15 seconds or more. The patient was put on carbamazepine after the initial seizures. Ictal behavioral characteristics changed slightly (sudden arrest of speech and motion, staring with blinking and perioral myoclonia). One year later he also developed generalized tonic-clonic convulsions. Several antiepileptic medications (valproic acid, carbamazepine, primidone, clonazepam), either alone or in combinations, were tried without significant benefit.

On admission, personal history revealed severe head trauma at the age of 9, which happened when he was cycling. He lost consciousness for 13 days. Although detailed records could not be obtained, the subject recovered without neurological sequelae. He was able to continue his education for 6 years, but he had to leave school when the seizures became frequent. Family history was unremarkable. The patient had no significant problems during the perinatal and infantile period. There was no consanguinity between his parents and no seizure history in his family. His neurological, physical and mental examinations were normal. Routine EEG showed frequent isolated spikes and spike-wave discharges in the posterior regions of the right hemisphere and generalized 3 Hz spike-wave complexes lasting for 10 seconds. Spike-wave discharges were more prominent at the posterior regions of the right hemisphere before they became generalized. The patient did not have photosensitivity. Cranial magnetic resonance imaging (MRI) indicated bilateral loss of periventricular white matter especially in the frontal lobes and right parieto-occipital area and a decrease in thickness of splenium of the corpus callosum. These were consistent with head trauma (Figure 1).

From the Departments of Neurology (F. I. Tezer, S. Saygi) and the Institute of Neurological Sciences and Psychiatry (N. Dericioglu), Hacettepe University School of Medicine, Ankara, Turkey.

Requests for reprints should be addressed to Serap Saygi, MD, Professor of Neurology, Yuksel Caddesi, 41/5 Ankara, Turkey.
Email: ssaygi@tr.net

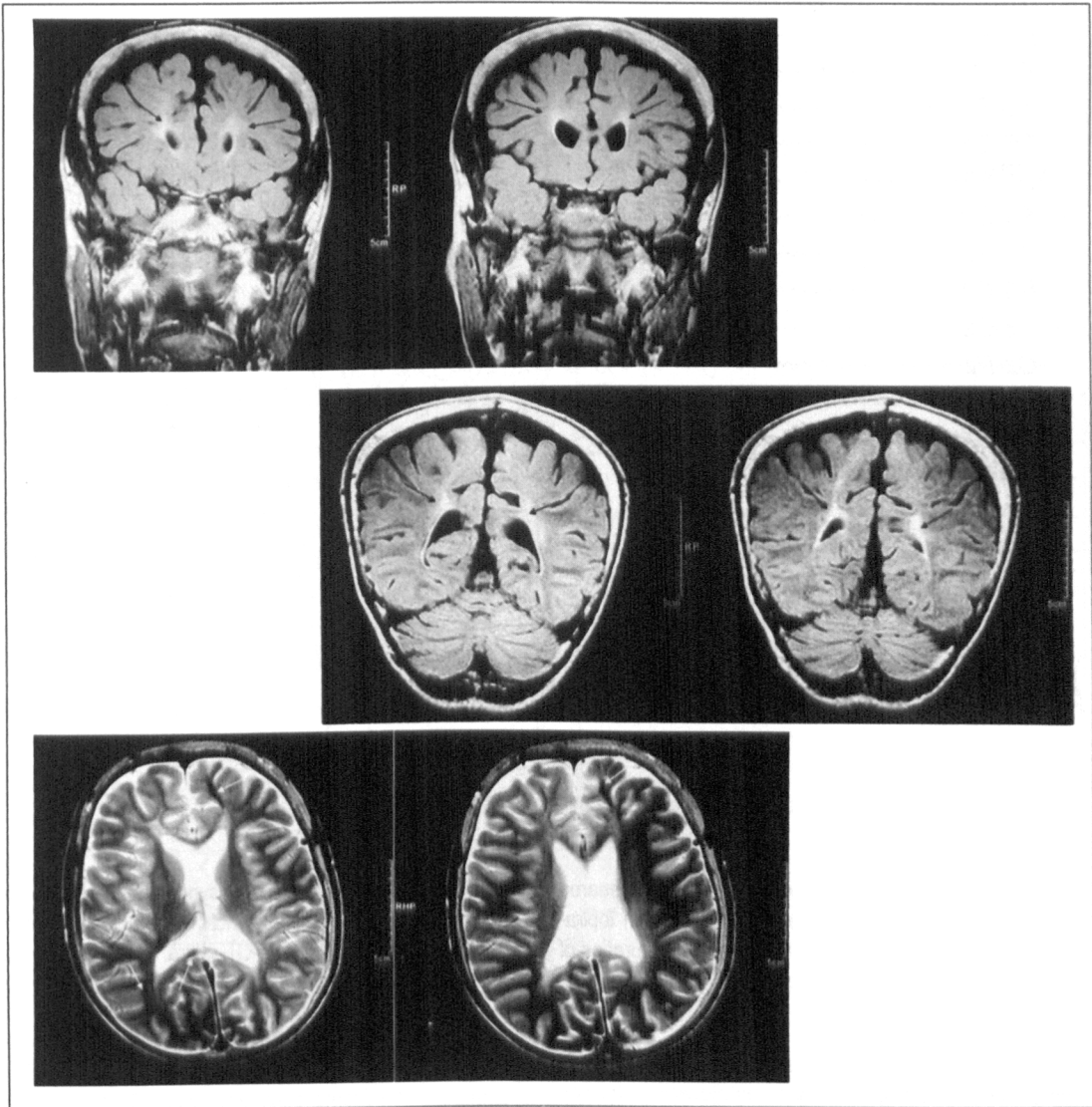


Figure 1:

Cranial MRI indicates bilateral loss of periventricular white matter especially in the frontal lobes and right parieto-occipital area with hemosiderin deposition that was attributed to head trauma.

After the addition of lamotrigine to primidone and clonazepam, generalized tonic-clonic seizures disappeared, and the frequency of absence seizures diminished to 3-4 times a day. Due to lack of seizure control, the subject was monitored with closed-circuit video-surface EEG for 2 days. The patient had 17 seizures. In 6 of them, generalized discharges, lasting 10-20 seconds, were preceded by right parieto-occipital spike-wave complexes for 2.5-3 seconds (Figure 2). The frequency of the burst remained almost unchanged at 3 Hz during the entire period. During one seizure, lateralization of discharges to the right hemisphere was prominent (Figure 3). In the remaining seizures, bursts

were already generalized at the beginning and lasted for 8-20 seconds. Seven seizures occurred during sleep and were not accompanied by any clinical findings.

The semiology was identical in all seizures but two. Volitional activities ceased, then staring, blinking and perioral myoclonia appeared. Consciousness was disturbed; the patient could not follow instructions and did not remember the code given during discharges. After the disappearance of discharges, he could follow the commands. In two seizures where right parieto-occipital discharges preceded generalized activity, the patient also had early eye deviation to the right. During sleep, isolated right parieto-occi-

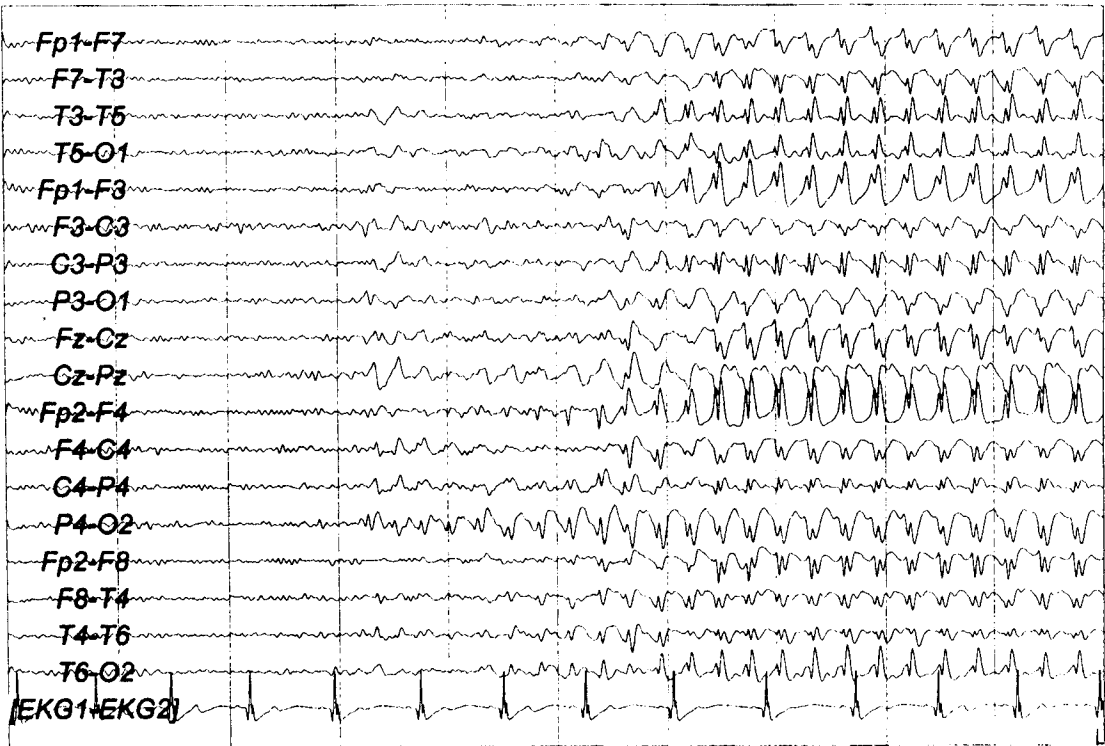

Figure 2:
Right parieto-occipital spike-wave complexes preceding 3 Hz generalized spike-wave discharges.

tal spikes or generalized spike-wave complexes appeared for 1-2 seconds (Figure 4). After this investigation topiramate was added to his therapy. Frequency and duration of seizures decreased on follow-up.

DISCUSSION

Absence seizures are included in age-related idiopathic generalized seizures, childhood and juvenile absence epilepsy. Symptomatic absence seizures with brain tumors, abscesses, congenital vascular-structural abnormalities and head injuries have also been reported,¹⁴ but these were poorly documented, so it is not easy to know how many patients had absence epilepsy. Recently, patients who had focal lesions associated with absences have been reported.^{3,7,13} Except one with multiple subcortical white matter lesions,⁹ all of these patients had frontal lesions. Their EEGs were interpreted as synchronous spike-wave discharges without lateralized or localized findings. Only neuroimaging techniques supported evidence that frontal lesions might be responsible for absence seizures.

Tükel and Jasper¹¹ reported that in some cases, generalized 3 Hz spike-wave complexes appeared in paramedian lesions with attacks resembling petit-mal. The authors defined the term secondary bilateral synchrony (SBS) to describe the generalized spike-wave complex that was

seen in focal lesions. Bilateral synchronous spike-wave discharges in patients with tumors were also reported in the literature during the pre-CT years.¹² With the stereo-electroencephalography recording, absence like partial seizures have been described after stimulation of the mesial frontal cortex.¹⁵ The role of the frontal lobe in absence seizures was also demonstrated on patients' EEG patterns.^{8-10,16-19} Frontal dominance on EEG was shown by interictal frontal slow waves or spike-waves,^{13,16,19} frontal spikes preceding the generalized spike-wave pattern,^{16,18} or frontal involvement in topographic mapping.¹⁷ But these findings were not supported by neuroimaging techniques in any case except two in whom interictal SPECT and ictal PET were used to demonstrate the foci.^{13,19} There was only one case with bursts of spike-wave complexes on the left hemisphere that spread to become generalized.⁸ Few cases of absence status with frontal lobe abnormality on CT scans and initial frontal focal ictal discharges on EEG have been reported.²⁰

In the present case, EEGs with generalized 3 Hz spike-wave patterns that were preceded by a burst of spike-waves on the right parieto-occipital region were demonstrated in seizures lasting 10-20 seconds. In addition to EEG findings, lesions that might be responsible for seizures were also detected in cranial MRI.

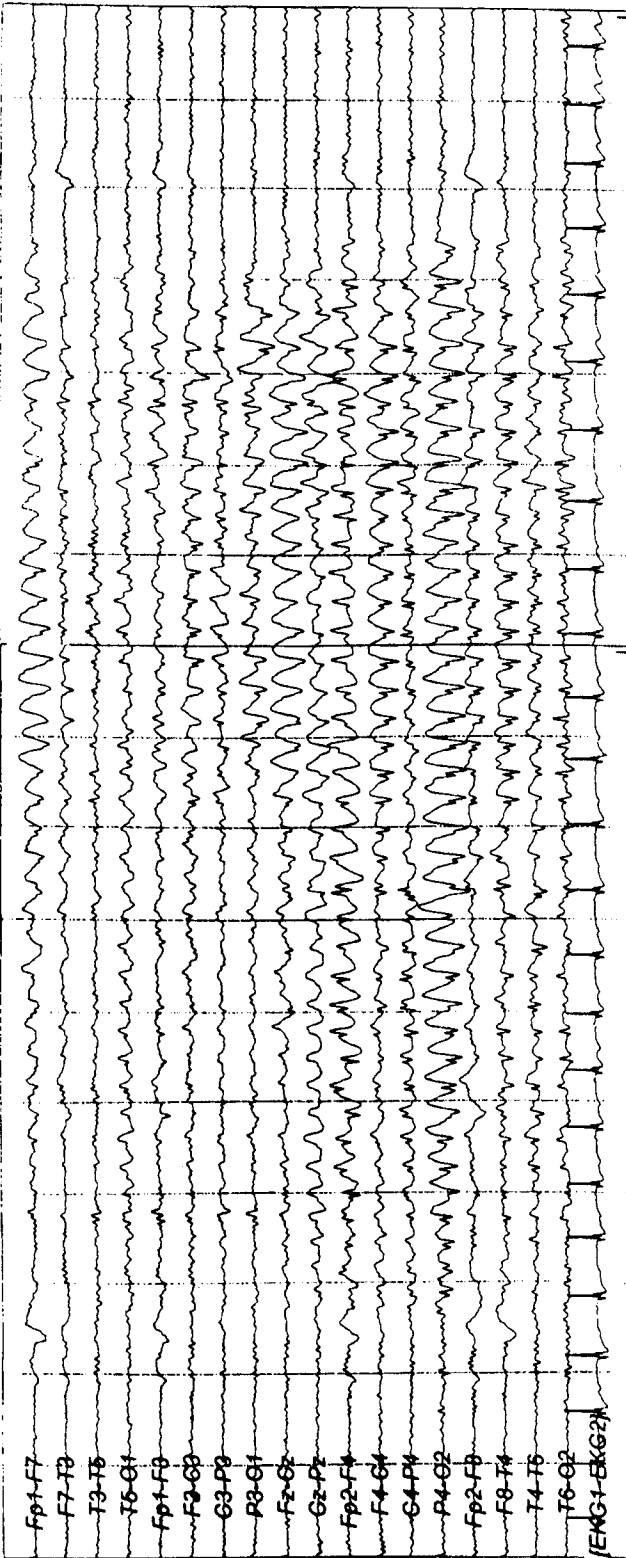


Figure 3:
Lateralization of 3 Hz spike-wave discharges to the right hemisphere throughout a seizure.

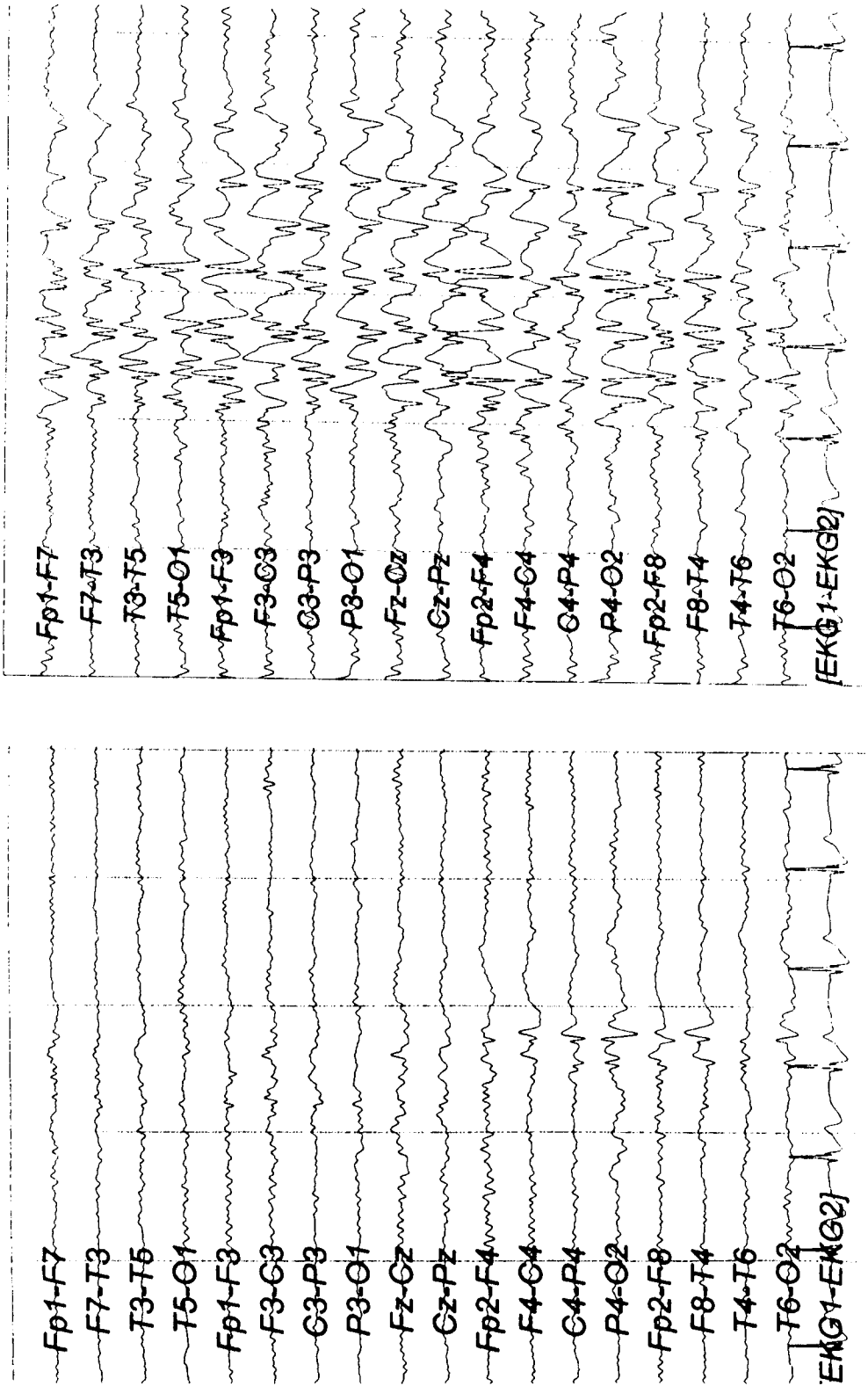


Figure 4:
Appearance of isolated right parieto-occipital spikes and brief generalized spike-wave complexes during the interictal period.

The clinical features of our patient's seizures, especially blinking and perioral myoclonia, resembled those of idiopathic generalized epilepsies with absences, eyelid myoclonia with absence seizures (EMAS) and perioral myoclonus with absence seizures (PMAS).^{21,22} But the patient's absence seizures lasted for 10-20 seconds, longer than EMAS and PMAS. He also had some absence seizures without eyelid myoclonia or blinking and had no family history consistent with idiopathic generalized epilepsy. On the other hand, ictal EEGs in EMAS and PMAS show generalized discharges of spikes, more often irregular polyspikes and slow waves at 3 Hz rather than generalized 3 Hz symmetric spike-wave discharges preceded by lateralized-localized spike-wave complexes.

Complex partial seizures that originate in the frontal lobe may also have similar clinical features to absence seizures.²³⁻²⁵ But EEGs with 3 Hz bilateral generalized symmetrical spike-wave discharges that lack frontal predominance, especially at the beginning of discharges, are incompatible with complex partial seizures of the frontal lobe or frontal absences.⁸⁻¹³ On the other hand, discharges beginning in the right parieto-occipital region in 6 of 17 recorded seizures might suggest complex partial seizures of the occipital lobe or absence seizures originating from the occipital lobe. However, to the best of our knowledge, bilateral generalized symmetrical 3 Hz spike-wave discharges have not been reported in seizures originating from the occipital lobe.^{24,26,27} Besides, the clinical features of the patient's seizures were not consistent with occipital lobe epilepsy.

In the literature, there is only one case with absence status that developed after left occipital ischemia extending to the ipsilateral thalamic region.²⁸ It was not due to the occipital lesion. The uninjured right thalamus was thought to generate oscillating excitation to the whole brain. To our knowledge, there are no reports with occipital or parietal lesions that generate absence seizures.

Another possible explanation is that juvenile absence seizures developed incidentally in our case after head trauma, and EEG revealed asymmetric features during absence seizures due to widespread post-traumatic lesions. The patient's cranial MRI findings with partial atro-

phy in splenium of the corpus callosum and periventricular white matter changes with hemosiderin deposition were compatible with head trauma. Centroraxial blows in traffic accidents produce lesions located mostly in deep structures.²⁹ In the literature we believe there is only one well-defined case report of absence seizures developing after head trauma,⁵ but unlike our patient, in this case there were no focal EEG findings.

The patient's lateralized and localized EEG findings were probably a representation of SBS that is differentiated from primary bilateral synchrony by poor symmetry and regularity. According to Niedermeyer,³⁰ some clinical characteristics developing after 10 years of age and a history of head injury suggested SBS. The mechanism of SBS is not clear. One theory is that interhemispheric pathways, especially the corpus callosum, are responsible for transfer of discharges from one hemisphere to the other; or areas maximally involved in the ictal discharge may have projections to the thalamus, to account for the abrupt alteration of awareness and bilateral ictal EEG findings. Mesial frontal cortex, rich in callosal connections or projection to the thalamus, is the most accountable region in the generation of SBS.⁷ The role of other lobes in the generation of SBS remains to be resolved. The temporal lobe was the second most common origin of SBS in the study of Blume and Pillay,³¹ but in Marcus and Watson's³² study occipital-temporal foci failed to produce bisynchronous discharges.

The mechanism of SBS is considerably more complex than a simple triggering of generalized spike-wave complexes from a single cortical focus. Secondary generalization might be such an alteration of inhibition.³³ Complex interaction of excitatory-inhibitory multiple cortical epileptiform discharges, acting through thalamic and callosal connection in generation of SBS, may be suggested. Multiple lesions may impair the ability of inhibitory mechanism on a region of epileptic discharge.³⁴ Multifocal lesions in our patient's MRI may reflect widespread cortical-subcortical dysfunction and SBS on EEG. The discussion whether the seizures were idiopathic or symptomatic of a cerebral lesion might be expanded with discovering the mechanisms of secondary bilateral synchronization.

REFERENCES

1. Commission on Classification and Terminology of the International League Against Epilepsy: proposal for revised clinical and electroencephalographic classification of epileptic seizures. *Epilepsia* 1981; 22:489-501.
2. Ferrie CD, Giannakodimos S, Robinson RO, Panayiotopoulos CP. Symptomatic typical absence seizures. In: Duncan JS, Panayiotopoulos CP, (eds). *Typical Absences and Related Epileptic Syndromes*. Edinburgh: Churchill Livingstone, 1995: 241-252.
3. Farwell, Stuntz T. Frontoparietal astrocytoma causing absence seizures and bilaterally synchronous epileptiform discharges. *Epilepsia* 1984; 25 (6): 695-698.

4. Bolay H, Ay H, Saygi S, Çiğir A, Saribas O. Late onset absence seizures in multiple sclerosis: a case report. *Clin Electroencephalogr* 1995; 26 (2): 124-130.
5. Dominguez FA, Chacon ML, Cruz GA, Cubero L, Sanchez GR, Lara HJ. Typical absence epilepsy in a patient with serious cranio-encephalic trauma. *Rev Neurol* 1999; 28 (3): 240-242.
6. Spencer MD. Leukoencephalopathy after CNS prophylaxis for acute lymphoblastic leukemia. *Pediatr Rehabil* 1998; 2 (1): 33-39.
7. So NK. Mesial frontal epilepsy. *Epilepsia* 1998; 39 (suppl 4): S49-61.
8. Kubota F, Shibata N, Shihara Y, Takahashi S, Ohsuka T. Frontal lobe epilepsy with secondarily generalized 3 Hz spike waves: a case report. *Clin Electroencephalogr* 1997; 28(3): 166-171.
9. Konishi T, Matsuzawa J, Hongou K, Murakami M, Yamatani M, Yagi S. Partial seizures during the course in patients with absence epilepsy. *No To Hattatsu*. 1999; 31 (5): 395-401.
10. Pavone A, Niedermeyer E. Absence seizures and the frontal lobe. *Clin Electroencephalogr* 2000; 31 (3): 153-156.
11. Tükel K, Jasper H. The electroencephalogram in parasagittal lesions. *Electroencephalogr Clin Neurophysiol* 1952; 4: 481-494.
12. Millichap JG, Bickford RG, Miller RH, Backus RE. The electroencephalogram in children with intracranial tumors and seizures. *Neurology* 1962; 12:329-336.
13. Milan E, Abou-Khalil B, Delbeke D, Konrad P. Case report: frontal localization of absence seizures demonstrated by ictal positron emission tomography. *Epilepsy Behav* 2001; 2: 54-60.
14. Ferrie CD, Giannokodimos S, Robinson RO, Panayiotopoulos CP. Symptomatic typical absence seizures. In: Duncan JS, Panayiotopoulos CP, (eds). *Typical Absences and Related Epileptic Syndromes*. Edinburgh:Churchill Livingstone; 1995: 241-252.
15. Bancaud J, Talairach J, Morel P, Bresson M, Bonis A, Geier S, et al. Generalized epileptic seizures elicited by electrical stimulation of the frontal lobe in man. *Electroencephalogr Clin Neurophysiol* 1974; 37:275-282.
16. Yamanouchi H, Suzuki H, Sakarugawa N, Kurokawa T. Absence attacks with secondary bilateral synchrony. *No To Hattatsu* 1992; 24 (3): 215-221.
17. Vuillemier P, Assal F, Blanke O, Jallon P. Distinct behavioral and EEG topographic correlates of loss of consciousness in absences. *Epilepsia* 2000; 41 (6): 687-693.
18. Lagae L, Pauwels J, Monte CP, Verhelle B, Vervisch I. Frontal absences in children. *Eur J Paediatr Neurol* 2001; 5 (6): 243-251.
19. Maruyama K, Itomi K, Ishiguro Y, Okumuro A, Negoro T, Watanabe K. A case with frontal lobe epilepsy presenting with absence seizures as cardinal manifestation: ictal EEG findings. *No To Hattatsu*. 2002 Jan; 34 (1): 72-76.
20. Niedermeyer E, Fineyre F, Riley T, Uematsu S. Absence status (petit mal status) with focal characteristics. *Arch Neurol* 1979; 36: 417-421.
21. Panayiotopoulos CP. Absence epilepsies. In: Engel J, Pedley TA, (eds). *Epilepsy. A Comprehensive Textbook*. Philadelphia: Lippincott-Raven; 1997: 2327-2346.
22. Hirsch E, Blanc-Platier A, Marescaux C. What are the relevant criteria for a better classification of epileptic syndromes with typical absences? In: Malofosse A, Genton P, Hirsch E, Marescaux C, Broglin D, Bernosconi R, (eds). *Idiopathic Generalized Epilepsies: Clinical, Experimental and Genetic Aspects*. London: John Libbey; 1994: 87-93.
23. Jobst BC, Siegel AM, Thadani VM, Roberts DW, Rhodes HC, Williamson PD. Intractable seizures of frontal lobe origin: clinical characteristics, localizing signs and results of surgery. *Epilepsia* 2000; 41 (9): 1139-1152.
24. Williamson PD, Spenser SS. Clinical EEG features of complex partial seizures of extratemporal origin. *Epilepsia* 1986; 27 (suppl 2): S46-S63.
25. Veilleux F, Saint-Hilare JM, Giard N, Turmel A, Bernier GP, Rouleau I, et al. Seizures of the human medial frontal lobe. *Adv Neurol* 1992; 57: 245-255.
26. Sveinbjornsdottir S, Duncan S. Parietal and occipital lobe epilepsy. *Epilepsia* 1993; 34 (3): 493-521.
27. Bancaud J. Les crises épileptiques d'origine occipitale: étude stéréo-électroencéphalographique. *Rev Otoneuroophthalmol* 1969;41:299-315.
28. Inghilleri M, Clemenzi A, Conte A, Frasca V, Manfredi M. Bilateral spike and wave discharges in a hemi-deafferented cortex. *Clin Neurophysiol* 2002; 113: 1970-1972.
29. Besenski N. Traumatic injuries: imaging of head injuries. *Eur Radiol* 2002; 12: 1237-1252.
30. Niedermeyer E. Primary generalized epilepsy. In: Niedermeyer E, Lopes da Silva F, (eds). *Electroencephalography*. 3rd ed. Baltimore, Munich: Urban and Schwarzenberg; 1995:501-510.
31. Blume W, Pillay N. Electrographic and clinical correlates of secondary bilateral synchrony. *Epilepsia* 1985; 26(6): 636-641.
32. Marcus EM, Watson CW. Bilateral synchronous spike wave electrographic patterns in the cat: interaction of bilateral cortical foci in the intact, the bilateral cortical callosal and adien-cephalic preperation. *Arch Neurol* 1966; 14: 601-610.
33. Jasper H. Neurophysiological basis of generalized epilepsies. In: Gastaut H, Jasper H, Bancaud J, Waltrengy A. (eds). *The Physiopathogenesis of the Epilepsies*. Springfield, Illinois: Charles C Thomas; 1969: Chapter 17.
34. Gloor P. Neurophysiological bases of generalized seizures termed centrencephalic. In: Gastaut H, Jasper H, Bancaud J, Waltrengy A. (eds). *The Physiopathogenesis of the Epilepsies*. Springfield, Illinois: Charles C Thomas; 1969.