



Hemorrhagic Stroke after Spinal Anesthesia and Minor Surgery

Thuc Tran, MD,* Deborah J. Culley, MD,†
Gregory Crosby, MD‡

Department of Anaesthesia Harvard Medical School, and Department of Anesthesiology, Perioperative and Pain Medicine, Brigham and Women's Hospital, Boston, MA

This report describes a case of hemorrhagic stroke that presented as an expressive aphasia after routine hernia repair under spinal anesthesia in an otherwise generally healthy middle-aged outpatient. Possible roles of preexisting migrainous headaches and perioperative ephedrine are discussed, but, as in most cases of perioperative stroke, the possibilities are numerous and the cause of the stroke difficult to determine. © 2004 by Elsevier Inc.

Keywords: Perioperative stroke; spinal anesthesia; surgery.

Introduction

The risk of stroke is increased threefold in the perioperative period, although it is still rare. Most perioperative strokes result from embolic or thrombotic events and are often associated with certain high-risk surgical procedures, co-existing vascular disease, or advanced age.¹ Herein we report a case of hemorrhagic stroke that presented as an expressive aphasia after routine hernia repair under spinal anesthesia in an otherwise generally healthy, middle-aged outpatient.

Case Report

A 48-year-old woman with a past medical history of depression treated with citalopram (20 mg/day), endometriosis, and a 2-month history of possible migraine headaches underwent an umbilical hernia repair with spinal anesthesia. Her past medical history was negative for hypertension, peripheral vascular disease, diabetes, oral contraceptive use or hormone replacement therapy, or smoking. After sedation with midazolam 1 mg and two unsuccessful attempts at the L₂-L₃ interspace with a 25-gauge Whitaker needle, a spinal was placed at the L₃-L₄ interspace with a 22-gauge beveled-tip needle, through which lidocaine 1.5%, 4 mL and fentanyl 25 µg was administered. Excessive cerebrospinal fluid leakage was not noted, and a T₁₀ spinal level was obtained. The only other medications she received were ephedrine 50 mg intramuscularly and cefazolin 1 g intravenously (IV) for prophylaxis of postoperative nausea and vomiting and infection, respectively. The intraoperative course was uneventful. The patient received 1200 mL of lactated Ringer's solution, and there was minimal blood loss. She remained awake throughout the procedure, with a blood pressure (BP)

*Resident and Clinical Fellow in Anaesthesia, Harvard Medical School

†Instructor in Anaesthesia, Harvard Medical School

‡Associate Professor of Anaesthesia, Harvard Medical School

Address correspondence to Dr. Culley, at the Department of Anesthesiology, Perioperative and Pain Medicine, Brigham and Women's Hospital, 75 Francis St., Boston, MA 02115, USA. E-mail: dculley@zeus.bwh.harvard.edu

Supported in part by an American Geriatrics Society Jahnigen Award and a Harvard/Hartford Foundation New Investigator Award to Dr. Culley, and by NIH Grant R01 AG20253 to Dr. Crosby.

Received for publication May 29, 2003; revised manuscript accepted for publication August 6, 2003.

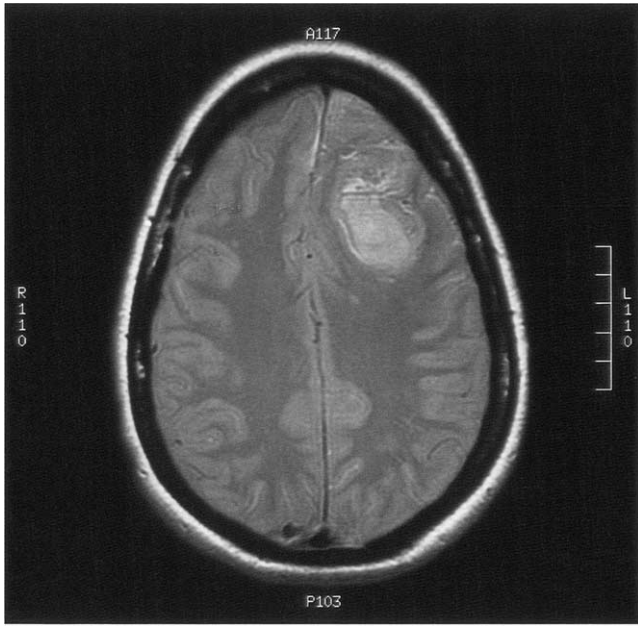


Figure 1. Magnetic resonance image demonstrating a large left frontal intraparenchymal hemorrhagic lesion with regional mass effect.

and heart rate (HR) of 120–150/70–90 mmHg and 60 to 80 beats per minute (bpm), respectively, which were similar to her preoperative values (BP: 100–140/60–85 mmHg; HR: 70 to 88 bpm).

During transfer to the postanesthesia care unit (PACU), she felt “faint.” Her HR was palpable at 40 bpm and the symptoms resolved with 0.2 mg of atropine and 10 mg of ephedrine IV. Upon arriving in the PACU, her BP was 174/97 mmHg, HR was 105 bpm, and oxygen saturation (SpO₂) was 100%. She developed emesis and stated that she felt “hypoglycemic.” She was treated with 4 mg of IV ondansetron and an IV bolus of 5% dextrose in water. Blood glucose was verified to be 236 mg/dL. Although symptoms improved slightly, she continued to have recurrent episodes of emesis and she developed a vague headache 1 hour after admission to the PACU. Two hours after PACU admission, the patient remained alert and cooperative but developed an expressive aphasia. A neurologic consultation was requested. The neurologic examination was unremarkable except that the patient was unable to speak. In the absence of other neurologic signs, the resident neurologist attributed this finding to psychogenic causes and no further work-up was recommended. However, at the insistence of the resident anesthesiologist, she was sent for a magnetic resonance imaging (MRI) scan. The MRI demonstrated a large left frontal intraparenchymal hemorrhagic lesion with regional mass effect (*Figure 1*). Subsequent studies, including brain computed tomography (CT), MRI, and magnetic resonance angiography, were negative for carotid or cerebral vascular abnormalities, or tumor. In addition, a metastatic work-up consisting of a mammogram and CT scans of the head, chest, abdomen, and pelvis, was negative. The patient was dis-

charged to a rehabilitation unit in stable condition on the fourth postoperative day.

Discussion

We describe the development of a hemorrhagic stroke in a 48-year-old patient without risk factors for stroke following a minor surgical procedure and uncomplicated spinal anesthetic. Stroke is uncommon and unpredictable after surgery and anesthesia, but for reasons that are not understood, the risk is threefold greater during the first 30 days after routine surgery and anesthesia.² In fact, most perioperative strokes occur postoperatively, usually within the first few days. Curiously, the risk appears to be similar regardless of whether central neuroaxis block or general anesthesia is used.²

This patient had none of the traditional risk factors for stroke, such as transient ischemic attacks, hypertension, a history of smoking, diabetes mellitus, ischemic heart disease, atrial fibrillation, or mitral valve disease. Our patient did have a 2-month history of headache, and there is a growing body of evidence that migraine headaches may be a risk factor for both hemorrhagic and ischemic stroke. In fact, a number of case reports describe the occurrence of stroke coincident with a migraine attack (migrainous stroke).^{3,4} However, our patient’s headaches were recent and were never diagnosed as migrainous. Because her headache complaints during the perioperative period were vague, it is difficult to decipher whether the headache was migrainous and proximally related to the stroke, resulted from the stroke, or was unrelated to either.

In part because it is so rare and difficult to study, the etiology of perioperative stroke in noncardiac, nonneurologic surgery such as was seen in this patient is an enigma. Several cases have attributed perioperative stroke to cerebral emboli, but this scenario requires both a source of emboli and the ability of embolic material to enter the arterial circulation. To our knowledge, umbilical herniorrhaphy is not associated with emboli and, although we did not investigate the possibility that the patient had a patent foramen ovale, emboli typically produce ischemic infarction. Hypotension is another perioperative event that has been associated with stroke. Prolonged and severe hypotension can clearly produce cerebral ischemia and infarction, but this patient had only a brief period of bradycardia and, presumably, hypotension that produced minimal cerebral symptoms, and was treated promptly. Although it is impossible to exclude mild hypotension as a contributing factor in this case, it is noteworthy that one small study suggests that conscious patients with a history of transient ischemic attacks can withstand a transient, 60% decrease in systolic blood pressure without stroke.⁵ Moreover, strokes caused by hypotension tend to be ischemic and occur in watershed areas between major cerebral vessels, neither of which is true in this case.⁶

Hypertension is an accepted cause of hemorrhagic stroke^{7,8} and, although this patient was only briefly and mildly hypertensive, the fact that she received ephedrine complicates the picture. Ephedrine is often used, as it was here, to prevent or treat spinal anesthesia-induced hypo-

tension, and it has recently gained favor to prevent postoperative nausea and vomiting.⁹ Ephedrine is also frequently found in over-the-counter medications, and there are numerous case reports of hemorrhagic or ischemic stroke after over-the-counter ephedrine use.¹⁰ The theory is that hemorrhagic stroke results from either the hypertensive action of ephedrine or a cerebral vasculitis, whereas thrombotic stroke results from ephedrine-mediated cerebral vasoconstriction. There is at least one case report of acute cerebral arteritis and hemorrhagic stroke in association with IV administration of ephedrine (10 mg) during routine surgery and anesthesia.¹¹ However, to date, no large, controlled studies have confirmed that ephedrine, particularly in the dosages used here, increases the risk of perioperative stroke, so it is difficult to say whether use of ephedrine and/or the brief period of hypertension contributed to our patient's stroke. In addition, stroke is listed as a potential side effect of the selective serotonin reuptake inhibitor (SSRI), citalopram, which this patient was using to treat depression. However, a recent large population-based case-controlled study found that SSRIs are not associated with an increased risk of intracerebral hemorrhage.¹² Indeed, it is important to recognize that in most cases of stroke the possibilities are numerous and the cause cannot be pinpointed.¹³

The approach to management of a patient with acute stroke has changed dramatically in the past several years. Whereas stroke treatment was historically simply supportive and rehabilitative (with the exception of hyperbaric therapy for treatment of air emboli), today stroke is considered a medical emergency. The main impetus for this change in attitude is the success of low molecular-weight heparin and thrombolytics for acute ischemic stroke.¹⁴ One of the main factors determining the likelihood that treatment will be effective is the interval from stroke to intervention, with patients who are treated within 3 hours having improved functional outcome compared with those in whom treatment was instituted later.¹⁵ Thrombolytics and anticoagulants have been used successfully in perioperative stroke,¹⁶ but they are contraindicated in the setting of a hemorrhagic stroke. Therefore, when a new and persistent focal neurologic deficit is detected perioperatively, a neurologic consultation should be obtained expediently because intracranial imaging is mandatory prior to initiating thrombolytic therapy and promptness of treatment is critical. Unfortunately, because of the hemorrhagic nature of the stroke, our patient was not a candidate for such therapy. In addition, although there is debate about what constitutes worrisome hyperglycemia in the setting, there is evidence linking hyperglycemia to poor neurologic outcome after stroke and, accordingly, exogenous administration of glucose should generally be avoided.^{17,18} In retrospect, glucose was neither required nor appropriate in this case but the likelihood that such modest hyperglycemia influenced the outcome seems low.

As is often the case, the cause of this patient's stroke is uncertain but the possibility that it was related to use of ephedrine or associated with possible migraine headaches

cannot be dismissed. Headache and emesis, early symptoms in this case, are common after anesthesia and surgery and, as such, may have delayed the diagnosis of stroke. Such a delay had no effect here but, in the event of an ischemic perioperative stroke, could adversely affect the probability that intervention would be successful. Thus, if a new and persistent neurologic deficit is identified perioperatively, neurologic consultation and imaging studies should be obtained expediently because time is of the essence and stroke is not a risk of just major surgical and anesthetic procedures.

References

1. Culley D, Crosby G: Perioperative stroke and markers of brain injury. *Curr Anesthesiol Rep* 2000;2:458–66.
2. Wong GY, Warner DO, Schroeder DR, et al: Risk of surgery and anesthesia for ischemic stroke. *Anesthesiology* 2000;92:425–32.
3. Buring JE, Hebert P, Romero J, et al: Migraine and subsequent risk of stroke in the Physicians' Health Study. *Arch Neurol* 1995; 52:129–34.
4. Rothrock JF, Walicke P, Swenson MR, Lyden PD, Logan WR: Migrainous stroke. *Arch Neurol* 1988;45:63–7.
5. Kendall RE, Marshall J: Role of hypotension in the genesis of transient focal cerebral ischaemic attacks. *BMJ* 1963;5353:344–8.
6. Bladin CF, Chambers BR: Frequency and pathogenesis of hemodynamic stroke. *Stroke* 1994;25:2179–82.
7. Klungel OH, Kaplan RC, Heckbert SR, et al: Control of blood pressure and risk of stroke among pharmacologically treated hypertensive patients. *Stroke* 2000;31:420–4.
8. Blumenfeld JD, Laragh JH: Management of hypertensive crises: the scientific basis for treatment decisions. *Am J Hypertens* 2001; 14(11 Pt 1):1154–67.
9. Rothenberg DM, Parnass SM, Litwack K, McCarthy RJ, Newman LM: Efficacy of ephedrine in the prevention of postoperative nausea and vomiting. *Anesth Analg* 1991;72:58–61.
10. Haller CA, Benowitz NL: Adverse cardiovascular and central nervous system events associated with dietary supplements containing ephedra alkaloids. *N Engl J Med* 2000;343:1833–8.
11. Mourand I, Ducrocq X, Lacour JC, Taillandier L, Anxiennat R, Weber M: Acute reversible cerebral arteritis associated with parenteral ephedrine use. *Cerebrovasc Dis* 1999;9:355–7.
12. Bak S, Tsiropoulos I, Kjaersgaard JO, et al: Selective serotonin reuptake inhibitors and the risk of stroke: a population-based case-control study. *Stroke* 2002;33:1465–73.
13. Pohjasvaara T, Erkinjuntti T, Vataja R, Kaste M: Comparison of stroke features and disability in daily life in patients with ischemic stroke aged 55 to 70 and 71 to 85 years. *Stroke* 1997;28:729–35.
14. Katzan IL, Furlan AJ, Lloyd LE, et al: Use of tissue-type plasminogen activator for acute ischemic stroke: the Cleveland area experience. *JAMA* 2000;283:1151–8.
15. Albers GW, Clark WM, Madden KP, Hamilton SA: ATLANTIS trial: results for patients treated within 3 hours of stroke onset. Alteplase Thrombolysis for Acute Noninterventional Therapy in Ischemic Stroke. *Stroke* 2002;33:493–5.
16. Chalela JA, Katzan I, Liebeskind DS, et al: Safety of intra-arterial thrombolysis in the postoperative period. *Stroke* 2001;32:1365–9.
17. Kagansky N, Levy S, Knobler H: The role of hyperglycemia in acute stroke. *Arch Neurol* 2001;58:1209–12.
18. Capes SE, Hunt D, Malmberg K, Pathak P, Gerstein HC: Stress hyperglycemia and prognosis of stroke in nondiabetic and diabetic patients: a systematic overview. *Stroke* 2001;32:2426–32.