

SPONTANEOUS CERVICAL EPIDURAL HEMATOMA: CASE REPORT AND LITERATURE REVIEW

David C. Adamson, M.D., Ph.D.,* Ketan Bulsara, M.D.,* and Peter R. Bronec, M.D.†
*Division of Neurosurgery and †Durham County Regional Hospital, Duke University Medical Center, Durham, North Carolina

Adamson DC, Bulsara K, Bronec PR. Spontaneous cervical epidural hematoma: case report and literature review. *Surg Neurol* 2004;62:156–160.

BACKGROUND

Spontaneously occurring epidural hematomas for which no etiology is identified are rare phenomenon. These are often neurosurgical emergencies; therefore, prompt diagnosis and treatment are paramount. Because of the rarity of this condition, we have illustrated in this recent case its presentation, evaluation and management.

METHODS

A 63-year-old male presented to our emergency room with right-sided hemiparesis and contralateral hypesthesia, consistent with a C5 Brown-Séquard syndrome. An initial evaluation for cerebral infarction was unremarkable, including a negative brain magnetic resonance image. Further imaging revealed a cervical epidural hematoma of unknown etiology.

RESULTS

The patient underwent emergent laminectomy for decompression and evacuation of the hematoma within 24 hours of his presentation to the emergency room. The patient's symptoms improved remarkably after surgery and a 4-month follow-up imaging evaluation revealed no recurrence of his hematoma.

CONCLUSION

This report highlights the various presentations, evaluation, and management options for this rare diagnosis. It emphasizes the necessity of prompt diagnosis for possible emergent intervention. © 2004 Elsevier Inc. All rights reserved.

KEY WORDS

Spontaneous cervical epidural hematoma, neurosurgical emergency.

Spontaneously occurring cervical epidural hematomas (SCEH) for which no etiology is identified were first described in 1869 and have

occasionally been reported since then [2,3,6–9,12,13,17]. The following report illustrates the occurrence of a SCEH in the absence of an underlying hematologic disorder, systemic disease, local disease, coagulopathy, anticoagulant therapy, vascular malformation, trauma, or physical exertion. As seen here, these epidural hematomas can cause dramatic and acute neurologic deficits, which can be satisfactorily reversed if diagnosed and treated immediately.

CASE REPORT

A 66-year-old male with a past medical history of hypertension, glaucoma, and a minor motor vehicle accident 9 months before admission presented to the emergency room (ER) with a chief complaint of neck pain and right-sided weakness. After sudden development of severe posterior neck pain, he took 2 baby aspirin and ibuprofen without any relief. Approximately 2 hours later, during the drive to the ER, he began to experience right-sided hand and leg weakness.

On initial evaluation in the ER, the patient was afebrile with a heart rate of 58 and blood pressure of 173/99. His neurologic examination was significant for 2/5 strength in his right dorsal interossei, 3/5 in his right biceps, triceps, and anterior tibialis; and 4/5 in his right deltoid, iliopsoas, and gastrocnemius. Sensation to temperature was decreased throughout his left leg and foot; however, sensation to light touch and pinprick were decreased throughout his entire left side, consistent with a C5 Brown-Séquard syndrome. Deep tendon reflexes were absent on the right. The remainder of his physical examination was unremarkable except for diffuse white lentigo spots over his chest and thighs that had been present since childhood.

Routine laboratory and diagnostic studies, in-

Address reprint requests to: David Cory Adamson, M.D., Ph.D., Division of Neurosurgery, Duke University Medical Center, Box 3807, Durham, NC 27710.

Received August 21, 2003; accepted October 6, 2003.

cluding coagulation parameters, were all within normal limits except for the presence of mild left ventricular hypertrophy on an electrocardiogram. Brain computed tomography (CT), magnetic resonance imaging (MRI), and MR angiography were notable only for mild periventricular chronic microvascular ischemic disease and hemodynamically insignificant internal carotid artery stenosis.

The patient's hemiparesis showed mild improvement while still in the ER. Because of the presumed diagnosis of transient ischemic attack, the patient was admitted to the medicine service and started on a heparin drip with a target prothrombin time of 45 seconds. During the evening of his admission, the patient developed worsening of his right-sided hemiparesis and contralateral hemihypesthesia. The heparin was discontinued and repeat neuroimaging was obtained, including a cervical magnetic resonance imaging (MRI).

Cervical MRI revealed an extradural mass posterior and to the right of the spinal cord extending from approximately C3 to C5 (Figure 1A and B). The mass produced compression and leftward displacement of the cord. Additionally, there was abnormal T2-weighted signal intensity within the cord consistent with focal edema. The extradural mass demonstrated T1-weighted signal greater than muscle but less than subcutaneous fat, as well as heterogeneously decreased T2-weighted signal. The mass did not show any intrinsic enhancement although there was very mild dural enhancement. There were no signs of associated neoplasm or vascular malformations. These findings were most consistent with an epidural hematoma.

The patient was emergently given fresh frozen plasma, protamine, and dexamethasone, with quick normalization of his coagulation parameters. He was then emergently taken to the operating room that evening where he underwent a C3 through C5 bilateral laminectomy for evacuation of an epidural hematoma, confirmed by gross and microscopic inspection. No other pathology was identified after complete evacuation of the hematoma.

The patient immediately recovered his deficits while in the recovery room except for 5-/5 strength in his right dorsal interossei, biceps, and iliopsoas. Patchy hypesthesia to pinprick persisted in his left leg. He began ambulating the following day with normalization of his examination except for mild right-sided apraxia. He was discharged from the hospital on postoperative day 4 with no further complications. The patient underwent a repeat cervical MRI during a routine 4-month follow-up visit, with no evidence of recurrent epidural hematoma (Figure 1C and D).

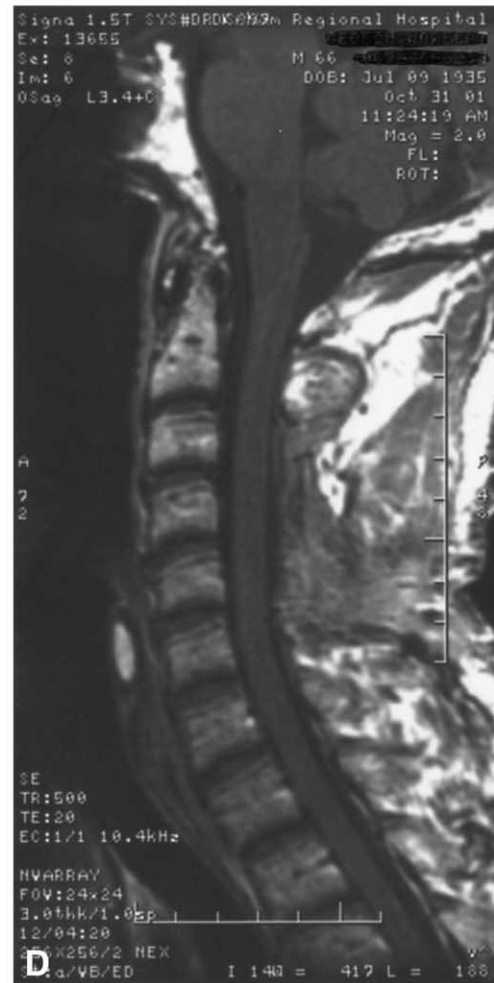
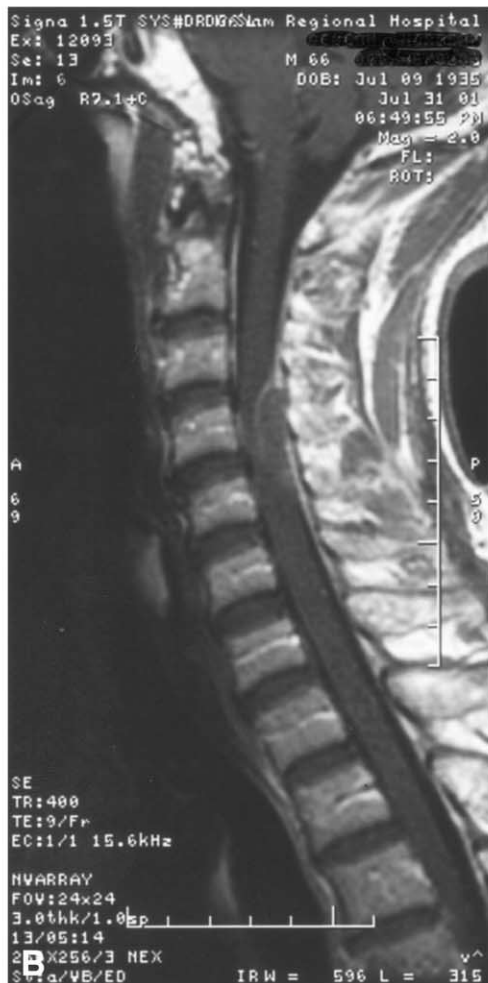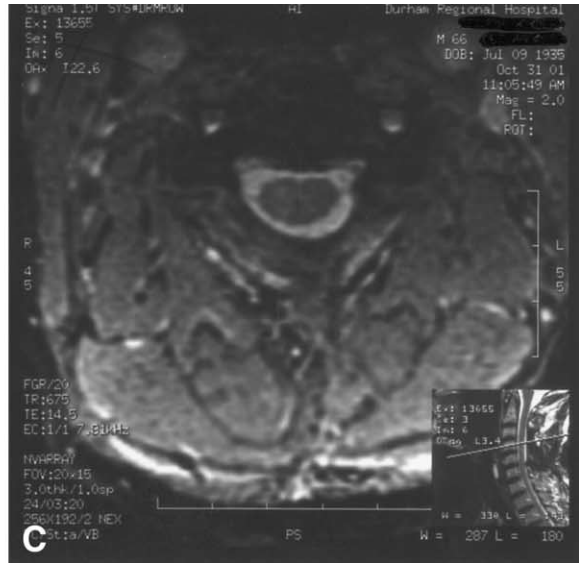
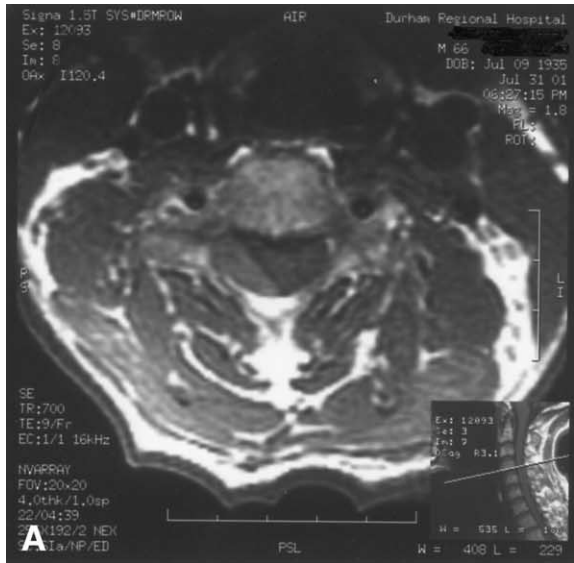
DISCUSSION

SCEH for which no etiology is identified are rare phenomena. They were first reported by Jackson in 1869 and have occasionally appeared in the literature since then [2,3,6–9,12,13,17]. SCEH is defined as hemorrhage in the absence of trauma, coagulopathy, anticoagulant therapy, vascular malformation, neoplasia, or systemic disease [10]. The vast majority of cases of CEH, however, are associated with an underlying hematologic disorder, systemic disease, local disease, or trauma [3,10]. SCEH have even occurred after mild physical exertion in predisposed individuals [3,5,11]. Documented activities resulting in SCEH have included sneezing, defecation, micturation, vomiting, coughing, coitus, bending, window-washing, wood-sawing, and swimming [4,11,15,16]. The patient in this report denied any significant past medical history except for hypertension and did not experience any recent trauma. He denied any antecedent exertional activity, sneezing, valsalva maneuver, coitus, or vomiting. His neck pain began spontaneously a couple of hours after awakening on the morning of admission.

An SCEH usually presents with acute neck or interscapular pain and neurologic deficits localizing to the level of the hematoma [3,10,16]. Radicular arm pain may also occur [3,10,16]. Neurologic deficits have included sensory and motor deficits occasionally accompanied by urine retention or loss of sphincter control [4,10,16]. Paresis is usually bilateral and rarely unilateral [1]. Flaccid paralysis has also been documented [3,4]. These signs can occur within minutes to hours after the event and usually after the onset of pain [4,10,16]. This case was unusual with the hemiparesis, but his hemisensory deficit clearly localized to the level of his SCEH. He did not have any radiculopathy; however, his neck pain was quite acute and severe.

Sixty-five percent of SCEH occur in women (3,5). C5 to C7 are involved in 95% of cases, and the hematoma covers three or more vertebra 50% of the time [3,10]. If the hematoma extends above C5, then the mortality rate rises to 30% [5]. Fortunately, this patient did not develop any respiratory difficulties or other morbidity despite the extension of his hematoma up to a C3 level. Perhaps the emergent decompression prevented this complication. As presented in this case, virtually all cases of SCEHs are located posterolaterally to the spinal cord [10].

Epidural venous plexi have been considered the source of hemorrhage for SCEH by many [10,14,15]; however, some have suggested that the hemorrhage is arterial [3]. Epidural veins may be more



1 (A, B) T1-weighted axial and sagittal (with contrast) MRI images of a spontaneous cervical epidural hematoma. The extradural mass is posterior and to the right of the spinal cord extending from approximately C3 to C5, producing compression and leftward displacement of the cord with approximately 30% canal compromise. Additionally, there was abnormal T2-weighted signal intensity within the cord consistent with focal edema (not shown). No intrinsic enhancement although there was very mild overlying dural enhancement. (C, D) T2-weighted axial and T1-weighted sagittal (with contrast) MRI images of a spontaneous cervical epidural hematoma after decompression 4 months later. The hematoma has been completely evacuated with no recurrence.

susceptible to rupture after activities that transiently raise venous pressure such as mild exercise, coughing, straining, or other valsalva events [10,15]. However, because cervical epidural venous pressure is lower than intrathecal pressure, venous bleeding should not be able to compress the dural sac. Therefore, it seems more logical that epidural arteries are the likely culprit, especially in light of the compression of the cord that can occur and the posterolateral location of most CEHs [3]. Some suggest that these arteries are susceptible to abnormal stretching during symmetrical arm movements [3].

Clinical history and neurologic examination are valuable tools for diagnosis; however, radiographic visualization of the SCEH is the most reliable diagnostic tool. CT and MRI are the most useful radiographic studies [5,7,10,13]. Myelography may be of assistance in patients with instrumentation that precludes adequate visualization with CT or MRI [10]. In the emergency room setting, an MRI may not be easily obtained at some facilities. In this situation, a CT should be adequate for diagnosis.

Patients with acute neurologic deficits because of a SCEH require immediate surgical decompression; however, rare spontaneous resolution without surgical intervention has been documented [1,10,11]. Surgical decompression usually involves bilateral laminectomy, or more rarely, hemilaminectomy with hematoma evacuation [1,5,10,14,16]. Decompression must be immediate since death from respiratory failure has been documented [5,16]. If a significant amount of time has passed since the event and neurologic symptoms are stable, it may be acceptable to closely monitor. However, any progressive changes demand immediate surgery. Mortality has been reported as high as 100% for patients without surgery, 25% within 4 months for patients with complete neurologic deficits, and 7% for those with incomplete deficits [5,16].

CONCLUSION

SCEH are rare neurosurgical emergencies and require immediate diagnosis and treatment. These should be suspected in patients presenting with acute neck pain, interscapular pain, upper and lower extremity motor weakness or a sensory deficit localizing to a cervical level. A thorough history and examination may identify trauma or medical conditions predisposing to a cervical epidural hematoma. Patients with acute neurologic deficits require immediate correction of coagulation abnormalities followed by decompressive surgery. As seen in this case, timely and appropriate surgical

intervention can reverse an otherwise devastating condition.

REFERENCES

1. Anderson TJ, Donaldson IM. Spontaneous resolution of cervical spinal epidural hematoma. *Postgrad Med J* 1989;65:488-90.
2. Awada A, Russell N, Fayez NA, Naufal R, Kohlani HA. Spontaneous cervical epidural hematoma: case report. *Spinal Cord* 1998;36:71-2.
3. Beatty RM, Winston KR. Spontaneous cervical epidural hematoma: a consideration of etiology. *J Neurosurg* 1984;61:143-8.
4. Correa AV, Beasley BAL. Spontaneous cervical epidural hematoma with complete recovery. *Surg Neurol* 1978;10:227-8.
5. Demierre B, Unger PF, Bongioanni F. Sudden cervical pain: spontaneous cervical epidural hematoma. *Am J Emerg Med* 1991;9:54-6.
6. Groen RJ, van Alphen HA. Operative treatment of spontaneous spinal epidural hematomas: a study of the factors determining postoperative outcome. *Neurosurgery* 1996;39:494-508.
7. Haykal HA, Wang AM, Zamani AA, Rumbaugh CL. Computed tomography of spontaneous acute cervical epidural hematoma. *J Comput Assist Tomogr* 1984;8:229-31.
8. Herrero JA, Saldana C, Jimenez A, Vazquez A, de Seijas EV, Mata P. Spontaneous cervical epidural hematoma with Brown-Séquard syndrome and spontaneous resolution. *J Neurosurg Sci* 1992;36:117-9.
9. Jackson R. Case of spinal apoplexy. *Lancet* 1869;2:5-6.
10. Lobitz B, Grate I. Acute epidural hematoma of the cervical spine: an unusual cause of neck pain. *South Med J* 1995;88:580-2.
11. Marinella MA, Barsan WG. Spontaneously resolving cervical epidural hematoma presenting with hemiparesis. *Ann Emerg Med* 1996;27:514-7.
12. Matsumae M, Shimoda M, Shibuya N, Ueda M, Yamamoto I, Sato O. Spontaneous cervical epidural hematoma. *Surg Neurol* 1987;28:381-4.
13. Morio Y, Kuranobu K, Yamamoto K. Chronic spontaneous cervical epidural hematoma. *Spine* 1993;18:405-6.
14. Pan G, Kulkarni M, MacDougall DJ, Miner ME. Traumatic epidural hematoma of the cervical spine: diagnosis with magnetic resonance imaging. *J Neurosurg* 1998;68:798-801.
15. Pear BL. Spinal epidural hematoma. *AJR Am J Roentgenol* 1972;115:155-64.
16. Williams JM, Allegra JR. Spontaneous cervical epidural hematoma. *Ann Emerg Med* 1994;23:1368-70.
17. Wisoff HS. Spontaneous intraspinal hemorrhage. In: Wilkins RH, Rengachary SS, eds. *Neurosurgery*. New York: McGraw-Hill, 1985:1500-4.

COMMENTARY

I have read with interest the report by Adamson et al regarding spontaneous cervical epidural hematomas. In these days of evidence based medicine,