

Case report

Hemiconvulsion–hemiplegia syndrome and primary human herpesvirus 7 infection

Jun-ichi Kawada^{a,b,*}, Hiroshi Kimura^b, Tetsushi Yoshikawa^c, Masaru Ihira^d,
Akihisa Okumura^b, Tsuneo Morishima^e, Fumio Hayakawa^a

^aDepartment of Pediatrics, Okazaki City Hospital, Okazaki, Aichi, Japan

^bDepartment of Pediatrics, Nagoya University Graduate School of Medicine, Nagoya, Japan

^cLaboratory of Virology, Research Institute for Disease Mechanism and Control, Nagoya University Graduate School of Medicine, Nagoya, Japan

^dDepartment of Pediatrics, Fujita Health University School of Medicine, Toyoake, Aichi, Japan

^eDepartment of Nursing, Nagoya University of Health Science, Nagoya, Japan

Received 24 April 2003; received in revised form 4 December 2003; accepted 4 December 2003

Abstract

We report a case of hemiconvulsion–hemiplegia (HH) syndrome. An 18-month-old female infant had a hemiconvulsion followed by left hemiplegia. Magnetic resonance imaging immediately after the onset of hemiplegia showed high intensity in the right hemisphere in diffusion-weighted images (DWI), while T1- and T2-weighted images were normal. Single photon emission computed tomography showed hypoperfusion of the right hemisphere in the acute phase. Virological analyses proved primary human herpesvirus 7 (HHV-7) infection. DWI are useful for the early evaluation of HH syndrome. Vascular disorders due to HHV-7 infection may have been related to the development of HH syndrome in this patient.

© 2004 Elsevier B.V. All rights reserved.

Keywords: Diffusion-weighted magnetic resonance imaging; Hemiconvulsion–hemiplegia syndrome; Human herpesvirus 7; Real-time quantitative PCR; Single photon emission computed tomography

1. Introduction

Hemiconvulsion–hemiplegia (HH) syndrome is characterized by prolonged seizures with unilateral predominance followed by the development of hemiplegia during the course of febrile disease in children, usually less than 4 years of age [1]. Although, HH syndrome can result from multiple causes, such as vascular disease, trauma, or inflammatory disease, its etiology in individuals is not always easy to determine. Neuroradiological studies have revealed hemiatrophy on computed tomography and magnetic resonance imaging (MRI) several weeks or months later in patients with HH syndrome [2]. However, there are few reports on neuroimaging findings during the acute stage of the illness. Herein, we report a case of HH syndrome that showed

interesting findings from MRI, magnetic resonance angiography (MRA), and single photon emission computed tomography (SPECT). In this unusual case, virological analyses suggested that primary human herpesvirus 7 (HHV-7) infection was associated with the development of HH syndrome.

2. Case report

An 18-month-old Brazilian girl was admitted to Okazaki City Hospital because of generalized convulsions, high fever, and decreased consciousness. Her development had been normal before the onset of illness. She had a history of exanthem subitum at 6 months of age and no history of varicella. On the first day of the disease, she had high fever of 39 °C and a generalized convulsion, which lasted for 40 min. On admission, she was stuporous, but neurological examinations were unremarkable. She had

* Corresponding author. Address: Department of Pediatrics, Nagoya University School of Medicine, 65 Tsurumai-cho, Showa-ku, Nagoya 466-8550, Japan. Tel.: +81-52-744-2294; fax: +81-52-744-2974.

E-mail address: k-kawada@qa2.so-net.ne.jp (J.-i. Kawada).

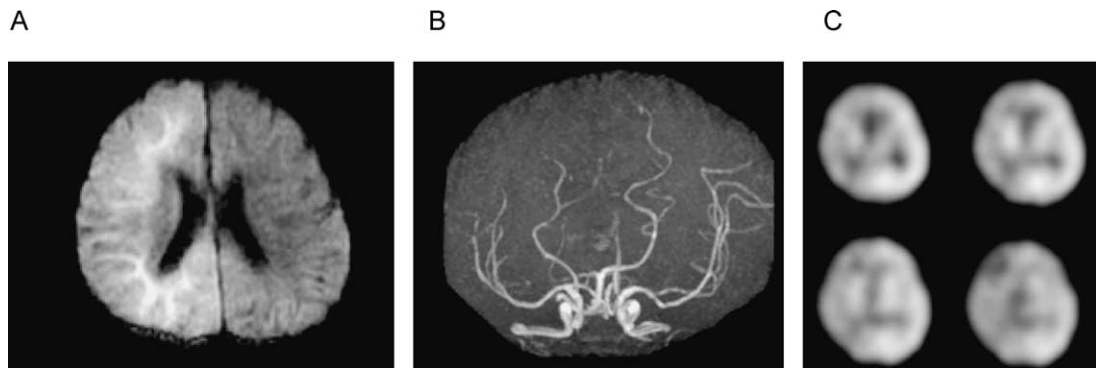


Fig. 1. (A) Diffusion-weighted magnetic resonance image on the 6th day of the illness showing high intensity in the right cerebral hemisphere. (B) Magnetic resonance angiography on the 6th day of the illness showing a narrow flow signal in the right distal cerebral artery. (C) Single photon emission computed tomography on the 9th day of the illness showing hypoperfusion of the right cerebral hemisphere.

a body temperature of 40.2 °C and a heart rate of 120 beats per min. Other results of the physical examination were normal. Cerebrospinal fluid (CSF) analysis revealed 1 cell per mm³, with a protein level of 18 mg/dl. Her white blood cell count was 15,800/mm³, but other hematological and biochemical findings were normal. Cranial computed tomography also showed normal findings. On the second day of admission, she became alert without motor impairment. However, an electroencephalogram revealed lazy activities in the right hemisphere and no epileptiform discharges. Although, her temperature returned to normal on the 4th day of the illness, she had recurrent hemiconvulsions in the left upper and lower extremities the following day. The first seizure was ended by a dose of midazolam 0.2 mg/kg, but the drug was not effective against subsequent seizures. She experienced an additional four hemiconvulsions that persisted for 10 min. Continuous infusion of lidocaine (3 mg/kg per h) was started to control the seizures. After the seizures stopped, she was noted to have left hemiplegia accompanied with dystonic posturing of the left side of her body. Hyper-reflexia was also observed in her left upper and lower extremities.

MRI showed high intensity of the right hemisphere in diffusion-weighted images (DWI) on the 6th day of the illness (Fig. 1A), although T1- and T2-weighted images were normal. MRA indicated a narrow flow signal in the distal part of the right cerebral artery (Fig. 1B). SPECT with ¹²³I-IMP showed hypoperfusion in the right cerebral hemisphere (Fig. 1C). MRI revealed atrophy of the right cerebral hemisphere on the 15th day of the illness. According to the clinical course and imaging results, HH syndrome was considered in this patient.

Her hemiplegia began to recover slowly from the third week after admission, and during her admission no skin rash appeared. Although, motor impairment in her left upper extremity remained for 3 months after the onset of the illness, she could walk without support and no mental retardation was apparent.

3. Virological analyses

To detect human herpesvirus 6 (HHV-6), HHV-7, herpes simplex virus and varicella zoster virus, a real-time quantitative PCR assay was performed, as previously described [3]. None of the DNA of these viruses was detected in the CSF of the patient. However, HHV-7 DNA was detected in serum during the acute phase of her illness, but not during the convalescent phase (Table 1). Both HHV-6 and -7 DNA were detected in peripheral blood leukocytes, although, the amount of HHV-7 DNA was much greater than that of HHV-6. Neither varicella zoster nor herpes simplex virus was detected in her serum or in her peripheral blood leukocytes.

Specific antibodies to HHV-7 were identified in a neutralization test [4] (Table 1). HHV-7 antibody was not detected during the acute phase, but antibody titers increased subsequently. Antibodies to herpes simplex virus and varicella zoster virus were not detected as determined by enzyme immunoassay. The presence of

Table 1
Virological analysis for HHV-6 and -7

	Day 6	Day 14	Day 31	Day 106
<i>Quantitative PCR assay</i>				
<i>HHV-7 DNA</i>				
Plasma (copies/ml)	30	Negative	Negative	Negative
PBL (copies/10 ⁶ cell)	n.d.	10,000	9000	Negative
CSF (copies/ml)	Negative	n.d.	n.d.	n.d.
<i>HHV-6 DNA</i>				
Plasma (copies/ml)	Negative	Negative	Negative	Negative
PBL (copies/10 ⁶ cell)	n.d.	2000	700	Negative
CSF (copies/ml)	Negative	n.d.	n.d.	n.d.
<i>Antibody</i>				
Anti-HHV-7 (NT)	<8	× 512	× 512	n.d.

PBL, peripheral blood leukocytes; CSF, cerebrospinal fluid; NT, neutralizing antibody; n.d., not done.

anti-viral antibodies, together with the existence of HHV-7 DNA in serum, suggested a primary HHV-7 infection in this patient.

4. Discussion

DWI can display subtle changes in the diffusion of water molecules. Regions of restricted or slower water molecular motion appear hyperintense [5]. For this reason, DWI is more sensitive than conventional MRI in the very early stages of the disease process. DWI may show signal changes related to decreased water diffusion under conditions when conventional T1- and T2-weighted images cannot reveal any abnormalities. In our patient, DWI was very useful in detecting the brain lesions even before hemiatrophy of the brain became apparent. DWI effectively identified the affected regions when T1- or T2-weighted images failed to detect them. These results suggest that DWI may be useful in determining whether organic lesions are present in children with repeated seizures. This more sensitive imaging technique may also contribute to treatment decisions, the monitoring of therapeutic effects, and the prognostication of neurological outcomes.

SPECT showed hypoperfusion of the right cerebral hemisphere in our patient. MRA detected narrow flow signals in the distal part of the right cerebral artery. Thus, hyperintensity areas on DWI were thought to reflect cytotoxic edema due to the ischemic lesions. This finding also indicates that ischemia in the right cerebral hemisphere was probably responsible for the hemiconvulsion and hemiplegia in this patient.

It is well known that primary infection with both HHV-6 and -7 can cause exanthem subitum [6]. There is one case-report of acute infantile hemiplegia associated with exanthem subitum caused by HHV-7 [7]. In our case, primary infection with HHV-7 was suspected following a PCR assay and the antibody neutralization test. However, HHV-6 DNA was also observed in peripheral leukocytes, so it is possible that reactivation of HHV-6 was induced by HHV-7. In vitro reactivation of HHV-6 by HHV-7 has been reported [8]. Clinical symptoms of primary infection with HHV-7 are rather atypical as compared to those with HHV-6 infection [6]. Therefore, it is not always easy to diagnose primary infection with HHV-7 based on clinical manifestations. There may be some unproven cases of HH syndrome caused by HHV-7, which had no characteristic symptoms such as skin rash after subsidence of fever.

Vascular disorders could have been the cause of ischemia in the right cerebral hemisphere in this patient. It is possible that the infection with HHV-7 or -6 caused a vascular disorder resulting in HH syndrome. It has been shown that HHV-6 can infect endothelial cells [9]. In one fatal case

with HHV-6 infection, HHV-6 antigen was detected in the endothelial cells of small vessels of the brain, although, the patient was co-infected with varicella zoster virus [10]. It is speculated that HHV-6 causes vasculitis [9]. However, there has been no direct proof of such vasculitis, because to our knowledge, there has never been an autopsied HH syndrome case with a single HHV-6 infection. In our case, HHV-6 and -7 DNA were not detected in the CSF of the patient, which suggests that it is unlikely that there was direct invasion of the brain by these viruses.

In summary, neuroradiological studies, especially DWI of MRI, were effective for understanding the pathogenesis of HH syndrome. Primary HHV-7 infection may be associated with HH syndrome in some patients.

Acknowledgements

This work was supported by a grant from the Ministry of Education, Culture, Sports, Science, and Technology of Japan (13670793).

References

- [1] Gastaut HPF, Payan H, Salomon G, Toga M, Vigouroux M. HHE syndrome: hemiconvulsions–hemiplegia–epilepsy. *Epilepsia* 1960;1: 418–47.
- [2] Salih MA, Kabiraj M, Al-Jarallah AS, El Desouki M, Othman S, Palkar VA. Hemiconvulsion–hemiplegia–epilepsy syndrome. A clinical, electroencephalographic and neuroradiological study. *Childs Nerv Syst* 1997;13(5):257–63.
- [3] Hara S, Kimura H, Hoshino Y, Tanaka N, Nishikawa K, Ihira M, et al. Detection of Herpesvirus DNA in the Serum of Immunocompetent Children. *Microbiol Immunol* 2002;46(3):177–80.
- [4] Yoshida M, Torigoe S, Ikeue K, Yamada M. Neutralizing antibody responses to human herpesvirus 6 and 7 do not cross-react with each other, and maternal neutralizing antibodies contribute to sequential infection with these in childhood. *Clin Diagn Lab Immunol* 2002;9(2): 388–93.
- [5] Nathaniel D, Wycliffe JRT, McLeary M, Holshouser BA. *Pediatric neuroimaging*, 3rd ed. St Louis: Mosby; 1999.
- [6] Torigoe S, Kumamoto T, Koide W, Taya K, Yamanishi K. Clinical manifestations associated with human herpesvirus 7 infection. *Arch Dis Child* 1995;72(6):518–9.
- [7] Torigoe S, Koide W, Yamada M, Miyashiro E, Tanaka-Taya K, Yamanishi K. Human herpesvirus 7 infection associated with central nervous system manifestations. *J Pediatr* 1996;129(2):301–5.
- [8] Tanaka-Taya K, Kondo T, Nakagawa N, Inagi R, Miyoshi H, Sunagawa T, et al. Reactivation of human herpesvirus 6 by infection of human herpesvirus 7. *J Med Virol* 2000;60(3):284–9.
- [9] Yoshikawa T, Asano Y. Central nervous system complications in human herpesvirus-6 infection. *Brain Dev* 2000;22(5):307–14.
- [10] Ueda T, Miyake Y, Imoto K, Hattori S, Miyake S, Ishizaki T, et al. Distribution of human herpesvirus 6 and varicella-zoster virus in organs of a fatal case with exanthem subitum and varicella. *Acta Paediatr Jpn* 1996;38(6):590–5.