

# Catastrophic Focal Epilepsy

Ruben Kuzniecky

*NYU Epilepsy Center, NYU School of Medicine, New York, New York, U.S.A.*

---

**Summary:** Focal epilepsy can present with a rapidly progressing course of intractable epilepsy in children. We present a typical example of such a patient with focal seizures due to a frontal lobe cortical lesion of developmental origin. MRI and SPECT

revealed abnormalities in the right frontal lobe. Surgical resection resulted in excellent outcome. **Key Words:** Focal epilepsy—Cortical dysplasia—Epilepsy surgery.

---

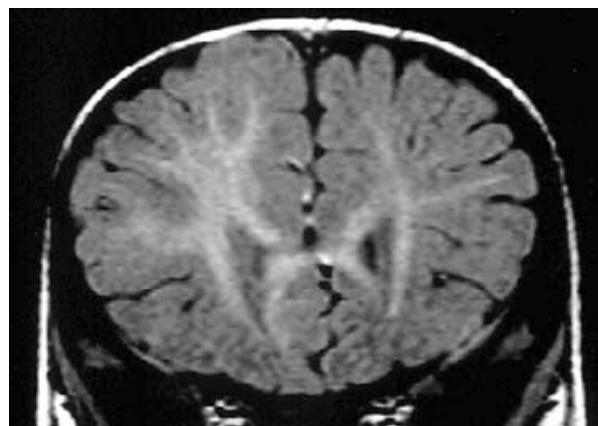
## CASE REPORT

The patient is a 10-month-old boy who was referred by his pediatrician for multiple paroxysmal episodes occurring every day since age 2 months. The patient was a product of a normal pregnancy and delivery. The mother was 26 years old during the pregnancy. The family history was negative for seizures or other neurologic disorders. The patient has a sibling who is 4 years old and healthy.

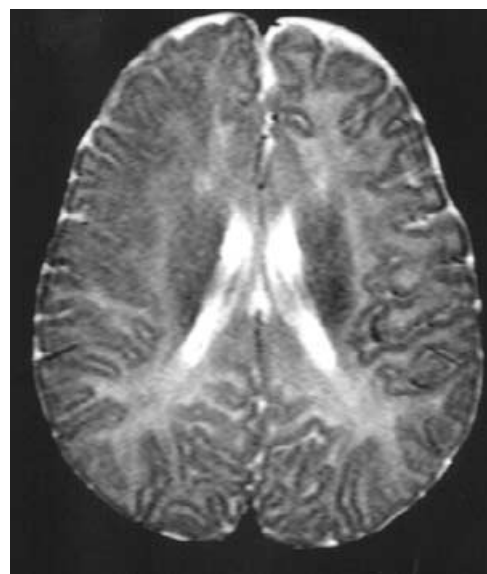
The mother reports that the child had no problems until approximately the sixteenth week of age when she began to notice quick extension of both arms and head and leg flexion. At first she saw a few episodes, particularly after feeding the baby. She thought for a while that this might be have been related to feeding. Eventually these episodes became more frequent, and within ~1 week after onset, she reported that the baby had  $\leq 20$  events per day. The patient was evaluated by a pediatrician and referred to a neurologist, who made the diagnosis of infantile spasms.

The patient was treated with a combination of valproate and phenobarbital and had no major improvement. A course of adrenocorticotrophic hormone was instituted, with resolution of the spasms within 1 week. The patient remained seizure free for 4 months without steroid therapy. Eventually he began to have seizures again, characterized by head and left arm extension. The events would occur 4 to 8 times per day. The events lasted ~20–30 s and were followed by a cry without major postictal symptoms.

Institution of therapy with carbamazepine followed by lamotrigine and topiramate did not improve the seizure frequency. At the time of referral, the parents reported an average of 10 seizures per day.



**FIG. 1.** Coronal T<sub>1</sub>-W image shows abnormal right frontal anatomy and gray–white matter organization.



**FIG. 2.** Axial T<sub>2</sub>-W image shows abnormal myelination pattern over right frontal lobe.

---

Address correspondence and reprint requests to Dr. R. Kuzniecky at NYU Epilepsy Center, NYU School of Medicine, 403 East 34<sup>th</sup> Street, New York, N.Y. 10016, U.S.A. E-mail: Ruben.Kuzniecky@med.nyu.edu

Neurologic examination revealed that the child was alert and able to interact with his surroundings. He was mildly sedated. The neurologic examination revealed minimal truncal hypotonia with difficulties with seating and a mild left hemiparesis. No stigmata of tuberous sclerosis were noted.

Interictal EEG recordings revealed background slowing of the frontal regions with slight predominance over the right hemisphere. Magnetic resonance imaging revealed evidence of mild lobar asymmetry, with the right hemisphere having an abnormal grey white matter pattern and cortical thickening. T<sub>2</sub>-W axial images also revealed an abnormal signal pattern over the right frontal region (see

Figs. 1 and 2). The patient underwent an ictal single-photon emission computed tomography study during one of the typical events; the study revealed hyperperfusion involving the right frontal region.

Because of intractability, the patient underwent an extensive right frontal resection. The resection included the mesial superior and lateral frontal precentral motor areas. After surgery, the patient was seizure free for 3 months with antiepileptic drug therapy. The parents reported improvement in his developmental status, with the patient beginning to walk at age 12 months. Pathologic examination demonstrated focal cortical dysplasia type 2.