

## Bilateral persistent trigeminal arteries presenting with brain-stem infarction

Y. Okada, T. Shima, M. Nishida, T. Yamada, K. Yamane, S. Okita, and R. Kagawa

Department of Neurosurgery, Chugoku Rousai Hospital, Kure, Japan

Received: 23 August 1991

**Summary.** A 43-year-old male with a left hemiparesis due to brain-stem infarction associated with bilateral persistent trigeminal arteries is reported. The clinicopathological and radiographic significance of persistent carotid-basilar arterial anastomoses in vertebrobasilar territory ischaemic attacks is also discussed.

**Key words:** Brain-stem infarction – Persistent trigeminal artery – Magnetic resonance imaging – Cerebral angiography – Vertebral artery occlusion

Although the primitive trigeminal artery (PTA) is the most common type of persistent carotid-basilar arterial anastomosis, and is estimated to be present in 0.1–0.6% of individuals in large angiographic series [1–5], bilateral PTAs are extremely rare. We could find only two cases of angiographically demonstrated bilateral PTAs [6, 7]. The clinicopathological significance of persistent carotid-basilar arterial anastomoses has not been clarified, because most cases have been shown incidentally by angiographic exploration of subarachnoid haemorrhage [3, 8–11], cranial nerve problems [12], brain tumours [1, 13], head injury [14] or cerebral ischaemia [15–22]. In these cases, brain-stem circulation would be principally via a persistent carotid-basilar anastomosis. Therefore, the clinicopathological and radiographic features of these cases should be investigated to clarify the pathogenesis of vertebrobasilar insufficiency.

We describe a case of brain-stem infarction in a patient with bilateral PTAs and discuss the clinicopathological features in brain-stem ischaemia with carotid-basilar arterial anastomoses.

### Case report

A 43-year-old right-handed man complained of left-sided weakness and impaired sensation involving the face. He was alert but hypertensive (170/86 mmHg) on admission. Positive findings on neuro-

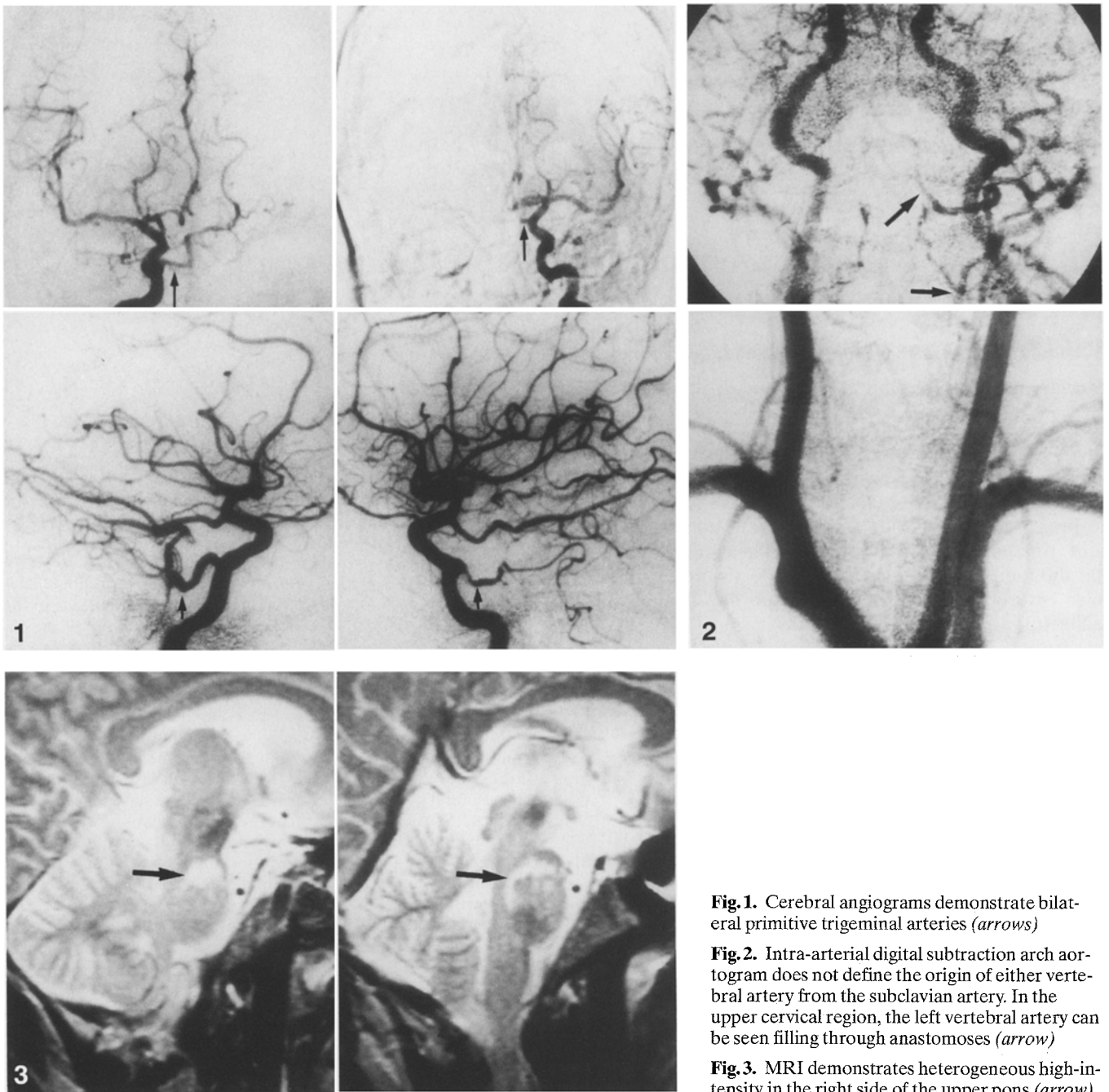
logical examination were left hemiparesis and numbness. Routine laboratory examination revealed normal haemoglobin, haematocrit, red blood cells, platelet count and blood sugar. An electrocardiogram did not reveal arrhythmia or atrial fibrillation.

Although CT on admission showed no evident lesion, 4 days later a small low-density area could be seen on the right side of the pons. Cerebral blood flow was investigated by the xenon 133 inhalation method using single photon emission computed tomography, which did not demonstrate an evident low-perfusion area. Cerebral angiography was performed via the femoral route. Bilateral common carotid artery injections revealed mild stenosis (20–30%) of both carotid bifurcations. A selective right internal carotid angiogram demonstrated a PTA, through which the contrast medium flowed into the basilar artery, giving excellent visualization of the contralateral posterior cerebral (PCA) and both superior cerebellar arteries (SCA) (Fig. 1 a,b). The vertebrobasilar arterial system proximal to the PTA was poorly seen. The ipsilateral PCA was visualized via a well-developed posterior communicating artery. A left internal carotid angiogram revealed another PTA, through which only the ipsilateral SCA was filled (Fig. 1 c,d). The vertebral arteries were investigated by intra-arterial digital subtraction angiography. There was no visualization of either vertebral artery origin from the subclavian arteries. The left vertebral V2–V4 segments filled via collaterals, along with the thyrocervical and occipital arteries (Fig. 2). Magnetic resonance imaging (MRI) at 1.5 T demonstrated brain-stem infarction, seen on T2-weighted images as a heterogenous high-intensity area on the right side of the upper part of the pons (Fig. 3).

As neither occlusive atherosclerotic lesions nor sources of emboli could be definitely identified, the patient was treated conservatively. During 3 months of rehabilitation his motor function recovered gradually, enabling him to walk without support.

### Discussion

The PTA arises where the internal carotid artery leaves the carotid canal and enters the cavernous sinus. The first angiographic description of this vessel was by Sutton [23], and it has subsequently been found not to be rare. To our knowledge, however, bilateral PTAs are extremely rare: even when other types of persistent carotid-basilar anastomoses are included, only six cases (including ours) are to be found in the English literature [6, 7, 24, 25]; their clinicopathological features are summarized in Table 1.



**Fig. 1.** Cerebral angiograms demonstrate bilateral primitive trigeminal arteries (arrows)

**Fig. 2.** Intra-arterial digital subtraction arch aortogram does not define the origin of either vertebral artery from the subclavian artery. In the upper cervical region, the left vertebral artery can be seen filling through anastomoses (arrow)

**Fig. 3.** MRI demonstrates heterogeneous high-intensity in the right side of the upper pons (arrow)

Saltzman [26] classified PTAs as follows: type I, the PTA supplies the entire vertebrobasilar arterial system distal to the anastomosis with poor filling of the posterior communicating artery; type II, the PTA mainly fills the SCA on both sides, while the PCA receives its blood through the posterior communicating artery; type III combines the two. Other rare types have been reported, such as those directly filling the ipsilateral SCA [27], anterior [28] or posterior inferior cerebellar arteries [29]. In our case, the right PTA supplies the cranial basilar artery, contralateral PCA and both SCAs, and the left PTA fills only the ipsilateral SCA.

With the advent of angiography persistent carotid-basilar anastomoses have been discovered as coincidental an-

giographic findings in patients with head trauma, tumours, subarachnoid haemorrhage and vertebrobasilar ischaemic attacks. Various researchers have attempted to correlate these persistent embryological arteries with other intracranial lesions. Eadie et al. [2] pointed out that the only significant association is between an isolated oculomotor palsy and a persistent trigeminal artery. However, there have been several reports of patients with a carotid-basilar anastomosis presenting with vertebrobasilar territory ischaemia. In general, brain-stem ischaemia has been ascribed to vertebrobasilar arterial occlusion due to atherosclerotic lesions [30, 31], embolism [20–22, 32] and external compression [33]. The circulation in the vertebrobasilar arterial system is known to be very complicated in

**Table 1.** Clinical and angiographic features of bilateral persistent carotid-basilar arterial anastomoses

Authors (year)	Age (years)	Sex	Symptoms	Anastomoses	Vertebral arteries	Diagnosis
Karasawa et al. (1976)	28	F	Headache (SAH)	L POA R PTA	L occluded R occluded	Angiomatous malformation
	39	M	Unconscious, headache, vertigo (SAH)	Bil. PHA	L absent R thin	SAH
Binet and Young (1977)	60	F	Gait disturbance, headache	Bil. PTA	L small R absent	Cerebellar tumour
Taguchi et al. (1978)	45	F	Double vision, exophthalmos	Bil. PTA	L hypoplastic R normal	Hyperthyroidism
Tanaka et al. (1983)	69	F	Hemiparesis, dysphasia	R PTA L proatlantal artery	L hypoplastic R not defined	Middle cerebral artery occlusion
Present case	43	M	Hemiparesis	Bil. PTA	Both absent from origin	Brain-stem infarct

F, Female; M, male; SAH, Subarachnoid haemorrhage; L, left; R, right; Bil., bilateral; PTA, primitive trigeminal artery; POA, primitive otic artery; PHA, primitive hypoglossal artery

occlusive diseases because of well-developed collateral channels. For example, even with bilateral vertebral artery occlusion, the clinical features and outcome are very variable [30, 31]. Caplan [30], reviewing 31 bilateral vertebral artery occlusions, suggested that the pathogenesis of vertebrobasilar ischaemic attacks in this condition was due principally to chronically reduced vertebrobasilar perfusion pressure and that extracranial-intracranial bypass would be effective in some cases.

The vertebral arteries tend to be hypoplastic or underdeveloped when the posterior circulation is mainly supplied via persistent carotid-basilar arterial anastomosis. In our case, neither V1 segment could be observed by arch aortography; only the left V2–V4 segments were seen, filling via collateral vessels in the neck. The ischaemic lesion was situated in the upper part of the pons, supplied by the basilar artery through the right PTA-basilar artery system. Accordingly, in patients with a persistent carotid-basilar arterial anastomosis three might be two possible mechanisms of brain-stem ischaemia: low-perfusion pressure in the vertebrobasilar system and embolization from the stenotic carotid lesions and/or the heart.

Five cases of embolic stroke with a carotid-basilar anastomosis have been reported [20–22]. Angiographically, they showed causative stenoses of the cervical internal carotid artery and were successfully treated by carotid endarterectomy. The results of operation indicated the pathogenesis in these cases would be microembolism originating from the cervical internal carotid artery, through a persistent carotid-basilar anastomosis.

In their review of the literature, Stern et al. [21] suggested that there might be a higher incidence of posterior fossa ischaemic attacks associated with persistent carotid-basilar anastomoses than previously thought. As Naritomi et al. [34] suggested, haemodynamic factors and dysautoregulation could also play a part in the pathogenesis of vertebrobasilar territory ischaemic attacks. Thus, the circulatory effects of a persistent carotid-basilar anastomosis should be investigated in detail to assess its clinicopathological significance in vertebrobasilar insufficiency.

## References

- Breutman ME, Fields WS (1963) Persistent hypoglossal artery. *Arch Neurol* 8: 369–372
- Eadie MJ, Jamieson KG, Lennon EA (1964) Persistent carotid-basilar anastomosis. *J Neurol Sci* 1: 501–511
- George AE, Lin JP, Morantz RA (1971) Intracranial aneurysm on a persistent trigeminal artery. Case report. *J Neurosurg* 35: 601–604
- Krayenbuhl HA, Yasargil MG (1982) Cerebral arteries. In Huber P (ed) *Cerebral angiography*, Thieme, Stuttgart, pp 57–61
- Wollschlaeger G, Wollschlaeger PB (1974) The circle of Willis. In: Newton TH, Potts GD (eds) *Radiology of the skull and brain angiography*. Mosby, St Louis, pp 1195–1196
- Binet EF, Young RF (1977) Bilateral persistent trigeminal arteries. Case report. *J Neurosurg* 47: 619–622
- Taguchi Y, Irikura T, Suzuki T, Nakamura N (1978) Unusual primitive trigeminal artery. Report of two cases. *No to Shinkei (Tokyo)* 30: 1209–1214
- Huber P, Rivoir R (1974) Aneurysm on a persistent left hypoglossal artery. Case report. *Neuroradiology* 6: 277–278
- Yamanaka C, Uozumi T, Okada Y, Iguchi T (1987) Cerebral aneurysm associated with persistent trigeminal artery and occlusion of subclavian artery. *Neurol Med Chir (Tokyo)* 27: 132–138
- Kodama N, Ohara H, Suzuki J (1976) Persistent hypoglossal artery associated with aneurysms. Report of two cases. *J Neurosurg* 45: 449–451
- Wolpert SM (1966) The trigeminal artery and associated aneurysm. *Neurology* 16: 610–614
- Kempe LG, Smith DR (1969) Trigeminal neuralgia, facial spasm, intermedium and glossopharyngeal neuralgia with persistent carotid basilar anastomosis. *J Neurosurg* 31: 445–451
- Begg AC (1961) Radiographic demonstration of the “hypoglossal artery”. A rare type of persistent anomalous carotid-basilar anastomosis. *Clin Radiol* 12: 187–189
- Carbomin C, Benedetti A, Cerri D, et al (1976) A case of persistent hypoglossal artery. *Neurochirurgia* 19: 231–236
- Harrison CR, Luttrell C (1953) Persistent carotid-basilar anastomosis. Three arteriographically demonstrated cases with one anatomical specimen. *J Neurosurg* 10: 205–215
- Wise BL, Palubinskas AJ (1964) Persistent trigeminal artery (carotid-basilar anastomosis). *J Neurosurg* 21: 199–206
- Jackson FE (1964) Case report and technical note. Syncope associated with persistent hypoglossal artery. *J Neurosurg* 21: 139–141
- Nakayama T, Fukumura A, Matsukada Y, Ozaki H (1970) Carotid-basilar anastomosis: primitive hypoglossal artery. *Kumamoto Med J* 23: 14–20, 1970

19. Debaene A, Farnarier P, Dufour M, Legré J (1972) Hypoglossal artery, a rare abnormal carotid-basilar anastomosis. *Neuroradiology* 4: 233–238
20. Waller FT, Simons RL, Kerber C, et al (1977) Trigeminal artery and microemboli to the brain stem. Report of two cases. *J Neurosurg* 46: 104–106
21. Stern J, Correll JW, Bryan JN (1978) Persistent hypoglossal artery and persistent trigeminal artery presenting with posterior fossa transient ischemic attacks. Report of two cases. *J Neurosurg* 49: 614–619
22. Quencer RM, Simon J (1979) Transient bilateral occipital lobe ischemia: microembolization through a trigeminal artery. *Neuroradiology* 18: 273–275
23. Sutton D (1950) Anomalous carotid-basilar anastomosis. *Br J Radiol* 23: 617–619
24. Karasawa J, Kikuchi H, Furuse S, et al (1976) Bilateral persistent carotid-basilar anastomoses. *AJR* 127: 1053–1056
25. Tanaka Y, Hara H, Momonse G, et al (1983) Proatlantal artery and trigeminal artery associated with an aneurysm. Case report. *J Neurosurg* 59: 520–523
26. Saltzman GF (1959) Patent primitive trigeminal artery studied by cerebral angiography. *Acta Radiol* 51: 329–336
27. Teal JS, Rumbaugh CL, Bergeron RT, et al (1972) Persistent carotid-superior cerebellar artery anastomosis: a variant of persistent trigeminal artery. *Radiology* 103: 335–341
28. Ito J, Takeda N, Suzuki Y, et al (1980) Anomalous origin of the anterior inferior cerebellar arteries from the internal carotid artery. *Neuroradiology* 19: 105–109
29. Chambers AA, Lukin R (1975) Trigeminal artery connection to the posterior inferior cerebellar arteries. *Neuroradiology* 9: 121–123
30. Caplan LR (1983) Bilateral distal vertebral artery occlusion. *Neurology* 33: 552–558
31. Bogousslavsky J, Gates PC, Fox AJ, Barnett HJM (1986) Bilateral occlusion of vertebral artery: clinical patterns and long-term prognosis. *Neurology* 36: 1309–1315
32. Pessin MS, Daneault N, Kwan ES, et al (1988) Local embolism from vertebral artery occlusion. *Stroke* 19: 112–115
33. Toole JF, Tucker SH (1960) Influence of head position upon cerebral circulation. Studies on blood flow in cadaver. *Arch Neurol* 2: 616–623
34. Naritomi H, Sakai F, Meyer IS (1979) Pathogenesis of transient ischemic attacks within the vertebrobasilar arterial system. *Arch Neurol* 36: 121–128

Dr. Y. Okada  
Department of Neurosurgery  
Chugoku Rousai Hospital  
1-5-1 Hirotagaya  
Kure 737-01  
Japan