

Occipital stroke shortly after cannabis consumption

Josef Finsterer^{a,*}, Prainer Christian^a, Kopsa Wolfgang^b

^a Department of Neurology, Krankenanstalt Rudolfstiftung, Juchg, 25, 1130 Vienna, Austria

^b Department of Radiology, Krankenanstalt Rudolfstiftung, Juchg, 25, 1130 Vienna, Austria

Received 10 September 2003; received in revised form 23 January 2004; accepted 3 February 2004

Abstract

There are several indications that imply cannabis consumption triggers cerebrovascular events. A right occipital ischemic stroke occurred in a 37-year-old Albanese man with a previously uneventful medical history, 15 min after having smoked a cigarette with approximately 250 mg of marijuana. Clinical manifestations of the stroke were left-sided hemiparesis, hemi-hypesthesia and blurred vision, which vanished spontaneously and almost completely after 3 days. He has been smoking joints regularly from the age of 27, with a frequency of 2–3 joints per week during the 6 months that preceded his stroke. Except for cigarette smoking and slight dyslipidaemia, classical risk factors for stroke/embolism were absent. Therefore, as the family history for cerebrovascular events, blood pressure, clotting tests, examinations for thrombophilia, vasculitis, extracranial and intracranial arteries and cardiac investigations were normal or respectively negative, the stroke was attributed to the chronic cannabis consumption.

© 2004 Elsevier B.V. All rights reserved.

Keywords: Drug abuse; Cerebral ischaemia; Vascular event; Stroke; Marijuana; Side effect

1. Introduction

Several reports have suggested a causal role of cannabis in the development of cerebro-vascular disease [1–9]. In the majority of these cases, patients experience a cerebral ischaemia during cannabis smoking. This report refers to a patient, who suffered from an ischemic stroke in the posterior circulation 15 min after having smoked a marijuana cigarette (joint).

2. Case report

The patient is a 37-year-old, HIV-negative Albanese man with a previously uneventful medical history. Except for smoking up to 20 cigarettes per day, classical risk factors for stroke/embolism were absent. He did not require any regular medication and there was no significant family history for cerebro-vascular disease. He drank regularly 2–2.5 l of non-alcoholic liquids per day. He has been smoking joints regularly from the age of 27, initially with a frequency of

1–2 per month. During the 6 months prior to his admission he had increased the frequency to 2–3 joints per week. He denied taking any amphetamines, ecstasy or any other illicit drugs. He was not screened for opiates, cocaine, cannabinoids, amphetamines, or benzodiazepines, but his relatives convincingly confirmed that he was taking cannabinoids exclusively. In May 2003 the patient was admitted as an emergency because of a sudden onset of left-sided hemiparesis, left-sided hemihypesthesia and recurrent double vision. These symptoms and signs developed acutely 15 min after having smoked a joint, containing approximately 250 mg marijuana, 2 h before his hospitalisation. Most of the symptoms disappeared within one hour after their onset.

Clinical neurologic examination on admission revealed blurred vision when looking to the upper and lower left, discrete left-sided dysdiadochokinesia, and a discrete weakness of the left upper limb (MRC grade 5-). There was no double vision and no visual field defect on confrontational perimetry. Blood pressure was 130/70 mmHg. The ECG showed sinustachycardia of 112 per min. Blood chemical investigations revealed a creatine-kinase of 229 U/l (normal: <170 U/l), which decreased to 179 U/l 2 days later, a cholesterol level of 208 mg/dl (normal: <200 mg/dl), a HDL-cholesterol level of 37 mg/dl (normal: >55 mg/dl), a LDL-cholesterol level of 160 mg/dl

* Corresponding author. Tel.: +43-1-71165-92085; fax: +43-1-4781711.

E-mail address: duarte@aonmail.at (J. Finsterer).

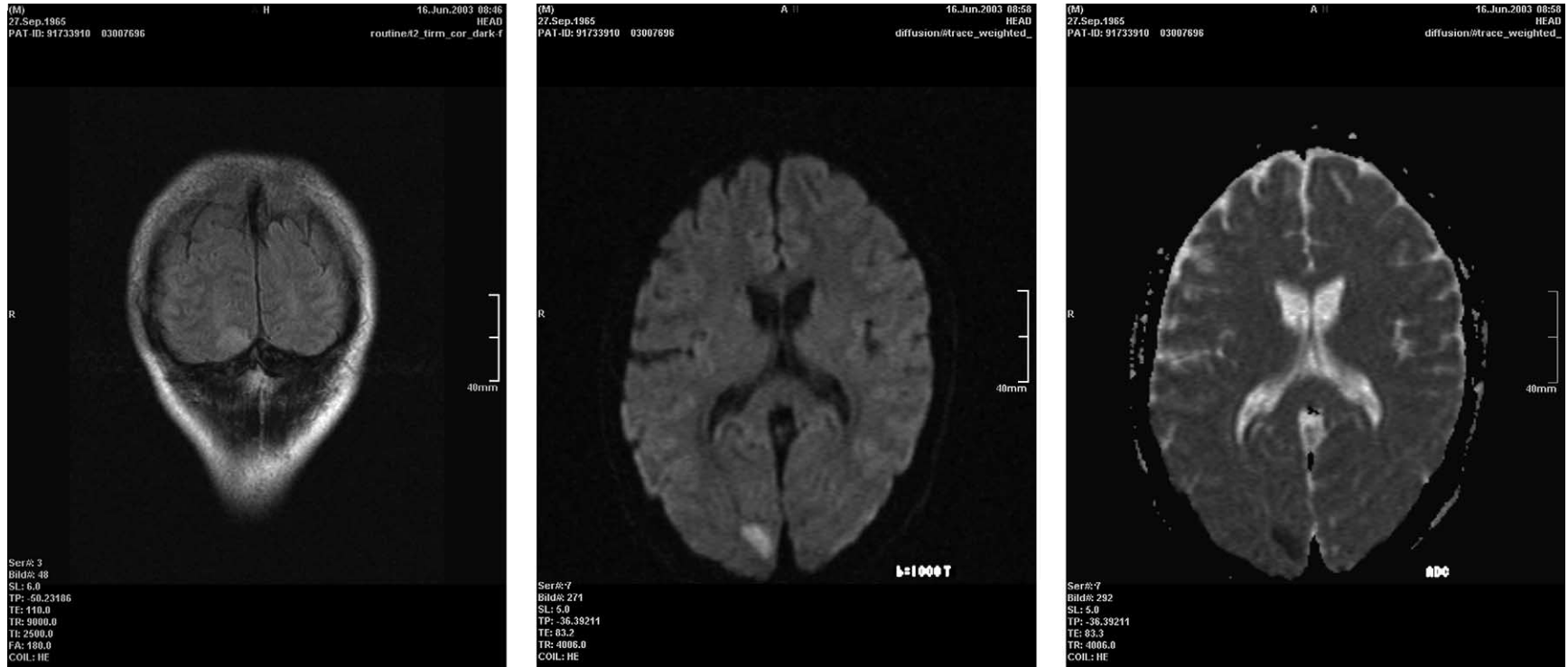


Fig. 1. Coronal MRI of the brain shows a slightly hyperintense lesion on the base of the occipital lobe (left). On diffusion-weighted MRI ($B = 1000$ T) this area is hyperintense (middle) and hypointense on the corresponding ADC sequences (right).

(normal: <130 mg/dl), but normal clotting tests. Risk factors for thrombosis including: homocystein, antithrombin, protein-S, protein-C, factor-VIII, factor-IX, APC-resistance, lupus-antigen, β -glykoprotein-antibodies and the 20.210 G \rightarrow A prothrombin-mutation were normal or negative. Parameters indicating vasculitis were negative. Ultrasound investigations of the extracranial and intracranial arteries were normal. Transthoracic echocardiography did not reveal intracardial thrombi or any other cardiac abnormality. A cerebral CT scan on admission was normal, but a diffusion-weighted MRI revealed an area of impaired diffusion, 2 cm in diameter, in the right occipital area sub-cortically (Fig. 1). Acetylsalicylic acid with dipyridamol and atorvastatin were begun. On dismissal 3 days after the stroke, blurred vision when looking to the left had remained the only neurological deficit.

3. Discussion

Although strokes in the posterior circulation during marijuana smoking have been reported earlier [5,8], the presented patient is noteworthy for right-sided occipital ischaemia, occurring less than 15 min after having smoked a marijuana cigarette. Except for nicotine smoking and slight dyslipidaemia, risk factors for stroke/embolism were absent. ECG and transthoracic echocardiography excluded a cardiac source of embolism. Extracranial and intracranial cerebral arteries were morphologically and functionally normal. The examination for thrombophilia and vasculitis was negative and there was no known family history of cardiovascular disease. Consequently, the stroke was attributed to the cannabis consumption rather than nicotine cigarette smoking or the slight dyslipidaemia.

Previous reports, showing an association or even causal relationship between strokes and drug abuse [1,3,6,9] and the documented vasogenic effect of marijuana [10–17] support the arguments for cannabis as the cause of the stroke in this case. Marijuana increases catecholamine levels, carboxy-haemoglobin, supine blood pressure, heart rate, cardiac output, and impairs peripheral vasomotor reflex, occasionally producing marked orthostatic hypotension [8,17,18]. With repeated exposure, supine blood pressure decreases slightly, orthostatic hypotension disappears, blood volume increases, and the reaction to the Valsalva manoeuvre diminishes [19], consistent with centrally mediated reduced sympathetic and increased parasympathomimetic drive. Concerning the cerebral perfusion, marijuana increases the pulsatility index, a measure of the cerebrovascular resistance, increases systolic velocity [20] and reduces cerebral blood flow [21]. In chronic marijuana abusers the cerebral blood flow is reduced during abstinence [10–12,22]. However, acute administration of marijuana, increases the cerebral blood flow [13–17]. Additionally, marijuana diminishes the cerebral autoregulatory capacity.

It could be possible that, marijuana had increased the

systolic blood pressure in the presented patient, which has been previously reported as a pathogenetic mechanism of strokes in these patients [9]. Another speculation suggests drug-induced reversible vasospasms due to marijuana consumption [9]. This assumption is supported by the fact that most of the previously reported strokes associated with cannabis abuse occurred whilst the drug was actually being smoked. However, there are also single cases, in which strokes have occurred up to half an hour after the last joint has been smoked [9]. A further assumption suggests strokes due to an immune-complex vasculitis [23]. Sinus-tachycardia in the presented patient was also interpreted as cannabis-induced. Usually the cardiovascular effects of cannabis are not associated with serious health problems for young, healthy volunteers. Nevertheless, occasionally, myocardial infarction, stroke and other cardiovascular adverse events occur in chronic cannabis users [19]. The reasons for the rarity of strokes in cannabis users, remain speculative. Contrary to the negative effects, marijuana has also a therapeutic potential in disorders resulting from cerebral ischaemia [24]. Whether the patient suffered from drug-induced arteriopathy or arteriitis, causing the infarct, remains speculative as no intra-arterial angiography had been carried out.

In conclusion, this case shows that marijuana smoking may cause stroke and that there may be a latency between resorption of the drug and the occurrence of the cerebrovascular event. Deficits caused by the stroke may be short-lived and may be followed by complete recovery after a few days.

References

- [1] Alvaro LC, Iriondo I, Villaverde FJ. Sexual headache and stroke in a heavy cannabis smoker. *Headache* 2002;42:224–6.
- [2] Barnes D, Palace J, O'Brien MD. Stroke following marijuana smoking. *Stroke* 1992;23:1381.
- [3] Cooles P, Michaud R. Stroke after heavy cannabis smoking. *Postgrad Med J* 1987;63:511.
- [4] Lawson TM, Rees A. Stroke and transient ischaemic attacks in association with substance abuse in a young man. *Postgrad Med J* 1996;72:692–3.
- [5] Marinella MA. Stroke after marijuana smoking in a teenager with factor V Leiden mutation. *South Med J* 2001;94:1217–8.
- [6] McCarron MO, Thomas AM. Cannabis and alcohol in stroke. *Postgrad Med J* 1997;73:448.
- [7] Mesec A, Rot U, Grad A. Cerebrovascular disease associated with marijuana abuse: a case report. *Cerebrovasc Dis* 2001;11:284–5.
- [8] White D, Martin D, Geller T, Pittman T. Stroke associated with marijuana abuse. *Pediatr Neurosurg* 2000;32:92–4.
- [9] Zachariah SB. Stroke after heavy marijuana smoking. *Stroke* 1991;22:406–9.
- [10] Amen DG, Waugh M. High resolution brain SPECT imaging of marijuana smokers with AD/HD. *J Psychoactive Drugs* 1998;30:209–14.
- [11] Block RI, O'Leary DS, Hichwa RD, Augustiniak JC, Ponto LL, Ghonein MM, et al. Cerebellar hypoactivity in frequent marijuana users. *Neuroreport* 2000;11:749–53.
- [12] Lundqvist T, Jonsson S, Warkentin S. Frontal lobe dysfunction in long-term cannabis users. *Neurotoxicol Teratol* 2001;23:437–43.

- [13] Mathew RJ, Wilson WH, Turkington TG, Hawk TC, Coleman RE, DeGrado TR, et al. Time course of tetrahydrocannabinol-induced changes in regional cerebral blood flow measured with positron emission tomography. *Psychiat Res* 2002;116:173–85.
- [14] Mathew RJ, Wilson WH, Chiu NY, Turkington TG, DeGrado TR, Coleman RE. Regional cerebral blood flow and depersonalization after tetrahydrocannabinol administration. *Acta Psychiat Scand* 1999;100:67–75.
- [15] Mathew RJ, Wilson WH, Coleman RE, Turkington TG, DeGrado TR. Marijuana intoxication and brain activation in marijuana smokers. *Life Sci* 1997;60:2075–89.
- [16] Mathew RJ, Wilson WH, Humphreys DF, Lowe JV, Wiethe KE. Regional cerebral blood flow after marijuana smoking. *J Cereb Blood Flow Metab* 1992;12:750–8.
- [17] O'Leary DS, Block RI, Koepfel JA, Flaum M, Schultz SK, Andreasen NC, et al. Effects of smoking marijuana on brain perfusion and cognition. *Neuropsychopharmacol* 2002;26:802–16.
- [18] Sidney S. Cardiovascular consequences of marijuana use. *J Clin Pharmacol* 2002;42(Suppl):S64–70.
- [19] Jones RT. Cardiovascular system effects of marijuana. *J Clin Pharmacol* 2002;42(Suppl):58S–63S.
- [20] Herning RI, Better WE, Tate K, Cadet JL. Marijuana abusers are at increased risk for stroke. Preliminary evidence from cerebrovascular perfusion data. *Ann NY Acad Sci* 2001;939:413–5.
- [21] Mathew RJ, Wilson WH. Substance abuse and cerebral blood flow. *Am J Psychiat* 1991;148:292–305.
- [22] Tunving K, Thulin SO, Risberg J, Warkentin S. Regional cerebral blood flow in long-term heavy cannabis use. *Psychiat Res* 1986;17:15–21.
- [23] Krendel DA, Ditter SM, Frankel MR, Ross WK. Biopsy proven cerebral vasculitis associated with cocaine abuse. *Neurology* 1990;40:1092–4.
- [24] Nagayama T, Sinor AD, Simon RP, Chen J, Graham SH, Jin K, et al. Cannabinoids and neuroprotection in global and focal cerebral ischemia and in neuronal cultures. *J Neurosci* 1999;19:2987–95.