

Case report

Aphemia-like syndrome from a right supplementary motor area lesion

Mario F. Mendez*

Department of Neurology, Reed Neurological Research Center, University of California at Los Angeles, Neurobehavior Unit (116AF),
VA Greater Los Angeles Healthcare, 11301 Wilshire Blvd., Los Angeles, CA 90073, USA

Received 7 April 2003; received in revised form 9 December 2003; accepted 17 December 2003

Abstract

Lesions in the left supplementary motor area (SMA) can result in a transcortical motor aphasia with nonfluent spontaneous verbal output and relatively preserved repetition. Reading and writing are proportionally affected. We report a patient with an ischemic lesion in the right SMA. He had impaired articulation and normal repetition plus preserved reading and writing, consistent with an aphemia. This patient supports the dissociation of articulatory fluency and linguistic fluency and suggests that both SMAs affect the initiating of articulatory movements required to produce words whereas the left SMA also affects linguistic aspects of speech.

© 2004 Elsevier B.V. All rights reserved.

Keywords: Aphemia; Aphasia; SMA

1. Introduction

Supplementary area (SMA) lesions can cause speech and language changes. There is debate over the specific changes due to SMA lesions. Some report transcortical motor aphasia, others report a more specific disorder of articulation or speech, and others focus on the motor initiation function of the SMA [1,2]. We report a patient with a right SMA who manifested a aphemia-like syndrome. This patient helps clarify the role of the SMA in language and speech function.

2. Case report

A 55-year-old right-handed clerk had the acute onset of speech difficulty with intact comprehension, repetition, and written language. He presented with hesitant, “slurred” speech and difficulty with speech production. Initially, he had little verbal output, but the onset was at night and was not observed. His past medical history was remarkable for hypertension, narcolepsy, and sciatica from an L3–4 disc herniation.

His initial examination disclosed prominent speech impairment. He had labored, effortful speech and misarticulated words. There were no word-finding difficulties or paraphasic errors. He generated word lists of 15 animals/minute and 12 “F” words/minute. He scored 15/15 on a confrontational naming task. Auditory comprehension was entirely normal. Despite his nonfluency, his ability to repeat aloud was strikingly preserved. Reading comprehension and writing were also normal, and he much preferred to communicate by writing.

The rest of his examination was mostly normal. His mini-mental state examination score was 28/30 [3]; he missed two attentional items only. His digit span was 7 forwards and 5 backwards, and his memory was 6/10 words at 15 min with 8/10 on recognition. He had good knowledge of current events. His mental status was normal for visuo-spatial constructions, elementary calculations, praxis testing in the upper extremities, Luria alternating programs, and idiom and proverb abstraction. He did not have orobuccal apraxia to commands such as “suck a straw,” “lick your lips,” or “blow out a match.” His cranial nerves were intact. His gait examination showed a slight eversion of his left foot, and he had decreased fine finger movements in the left hand and mild quadriceps weakness in the left leg. These neurological changes occurred coincident with the onset of his speech impairment. Reflexes were normal and symmetrical without pathological reflexes. There were no sensory changes.

* Corresponding author. Tel.: +1-310-478-3711;
fax: +1-310-268-4181.

E-mail address: mmendez@ucla.edu (M.F. Mendez).

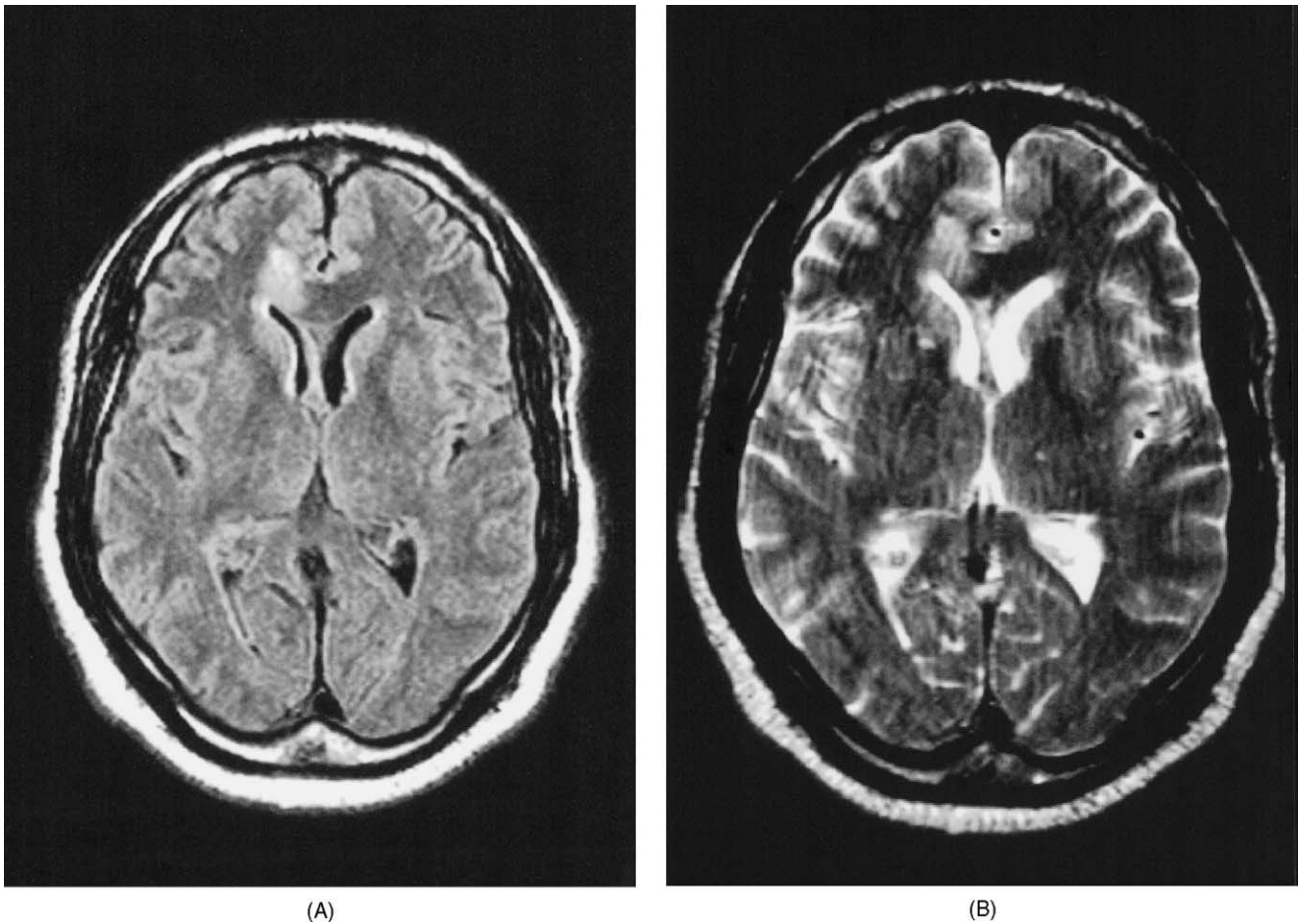


Fig. 1. Horizontal magnetic resonance images of patient with a right supplementary area infarction. (A) FLAIR sequence; (B) T2-weighted sequence.

Neuroimaging revealed a right hemisphere stroke of probable embolic origin (see Fig. 1). Magnetic resonance imaging showed a recent right anterior cerebral artery infarction involving the right aspect of the corpus callosum and the distribution of its pericallosal branch. On magnetic resonance angiography, there was an abrupt cut-off 1 cm from the origin of this branch suggesting an embolic occlusion. The patient completed a stroke work-up that was essentially unremarkable, and he was treated with clopidogrel and aspirin.

The patient had an extensive speech and language assessment. He was frustrated that people had difficulty understanding his speech, and he resorted to writing for communication. Although hesitant to attempt speech, he was a functional communicator if given enough time to express himself. The patient underwent the Boston Diagnostic Aphasia Examination and the Boston Naming Test (BNT) [4,5].

This assessment showed predominant difficulty with articulatory fluency with preservation of language aspects of speech. He had frequent and multiple speech sound repetitions, particularly on the initial sound or syllable. His forward flow of speech was disrupted by these repetitions and

by lengthy pauses while preparing for the next utterance. Dysfluencies particularly occurred in the following sounds in initial position: “k, pl, n, d, f, w.” He also had frequent vowel distortions and substitutions, fluctuating resonance, and dysprosody with a halting staccato rhythm and an intermittent harsh vocal quality. These articulatory changes gave some listeners the impression that he had a foreign accent.

His language examination was otherwise normal. His speech had intact grammar and syntax, and there were no paraphasic errors. He had an excellent vocabulary and a good command of written language. He scored 57/60 on the BNT, higher than the mean of 55 for normals [5], and he had 100% accuracy on a naming subtest of the BDAE. He had 100% accuracy when responding to complex ideational and other auditory comprehension tasks from the BDAE. Repetition and automatic sequences were fluent, without dysarthria or other speech difficulties, and without errors on the BDAE. Reading comprehension was also normal, and he wrote grammatically correct sentences without spelling errors.

The patient’s speech and language examination was relatively unchanged six months after his stroke.

3. Discussion

This patient had speech difficulty from a right SMA lesion. Despite his pronounced articulatory impairment, he had normal linguistic fluency, repetition, and reading and writing. The nature of his deficit confirmed that SMA lesions can dissociably affect different aspects of fluency. His right-sided SMA lesion impaired articulatory fluency but spared linguistic aspects of speech.

Left SMA lesions cause a reduction in the initiation spontaneous or voluntary speech and language [6,7]. These patients have a transcortical motor aphasia-like picture usually with initial muteness, followed by hypophonic and grammatically intact verbal output, short phrase length, and severely impaired writing [1,8]. Like Broca's aphasia, left SMA lesions appear to impair both articulatory and linguistic fluency [9–11]. Linguistic nonfluency includes short phrase length, word-finding difficulty, agrammatism, and phonemic paraphasias with phonemic reiterations or anticipations. Articulatory nonfluency includes phonetic disintegration with articulatory reduction or a decreased repertoire of phonemes and a shift of voiced to voiceless consonants [12].

This right-handed patient with a right-sided SMA lesion had articulatory impairment without linguistic difficulty in naming, grammar, or written language. His speech was labored and effortful with hesitations, false starts, and repetitions. Investigators have postulated that this articulatory difficulty from SMA lesions results from a disturbance in the articulatory buffer; there is impaired initiation of sequential phonological strings or speech movement sequences temporarily stored in this buffer [11].

This patient differed from many patients with SMA lesions in that he had preservation of written language consistent with an aphemias [13,14]. Indeed, he preferred to communicate in writing. Aphemias is not an aphasia but a disturbance of motor speech [13]. Similar to some aphemias patients, this patient's difficulty at both the phonemic level and at the prosodic or supra-segmental level gave the impression of a foreign accent to some listeners [12,15].

This patient also differed from the traditional aphemias syndrome. First, unlike aphemias, his articulatory difficulty disappeared with repetition and automatic speech. Second, aphemias usually results from lesions within Broca's area or subcortical, disconnecting outflow [14,16]. There was no evidence of injury in these areas. The focus of his injury was in the right SMA, a region involved in the spontaneous initiation of articulation [10,11,17]. Finally, this patient did not have the typical foreign accent syndrome as the majority of listeners remained aware of his speech hesitations and difficulties, and he lacked damage to the region of the precentral gyrus [15].

In conclusion, this patient with a right-sided SMA lesion illustrates the bilateral role of the SMA in the control of articulation. There is a bilateral role of the SMA in the initiation of speech and, specifically, the initiation of sequential articulations [10,11,17]. Left SMA lesions may additionally impair the initiation of language production [2]. The literature further suggests that both SMAs are necessary for continuously feeding the content of the articulatory buffer into the motor execution component [11].

References

- [1] Masdeu JC, Schoene WC, Funkenstein H. Aphasia following infarction of the left supplementary motor area: a clinicopathologic study. *Neurology* 1978;28:1220–3.
- [2] Pai MC. Supplementary motor area aphasia: a case report. *Clin Neurol Neurosurg* 1999;101:29–32.
- [3] Folstein MF, Folstein SE, McHugh PR. Mini-mental state: a practical method for grading the cognitive state of patients for the clinician. *J Psychiatric Res* 1975;12:189–98.
- [4] Goodglass H, Kaplan E, Barresi B. The assessment of aphasia and related disorders. 3rd ed. Philadelphia: Lippincott Williams & Wilkins; 2001.
- [5] Kaplan E, Goodglass H, Weintraub S, Segal O. Boston naming test. 2nd ed. Philadelphia: Lippincott Williams & Wilkins; 2001.
- [6] Bannur U, Rajshekhar V. Post operative supplementary motor area syndrome: clinical features and outcome. *Br J Neurosurg* 2000;14:204–10.
- [7] Krainik A, Lehericy S, Duffau H, Vlaiu M, Poupon F, Capelle L, et al. Role of the supplementary motor area in motor deficit following medial frontal lobe surgery. *Neurology* 2001;57:871–8.
- [8] Freedman M, Alexander MP, Naeser MA. Anatomic basis of transcortical motor aphasia. *Neurology* 1984;34:409–17.
- [9] Jonas S. The supplementary motor region and speech emission. *J Commun Disord* 1981;14:249–373.
- [10] Petrovici JN. Sprachstörungen bei Tumoren der supplementar-motorischen Region. *Zentralbl Neurochir* 1983;44:97–104.
- [11] Ziegler W, Kilian B, Deger K. The role of the left mesial frontal cortex in fluent speech: evidence from a case of left supplementary motor area hemorrhage. *Neuropsychologia* 1997;35:1197–208.
- [12] Benson DF, Ardila A. Aphasia: a clinical perspective. New York: Oxford University Press; 1996. p. 252–61.
- [13] Fox RJ, Kasner SE, Chatterjee A, Chalela JA. Aphemias: an isolated disorder of articulation. *Clin Neurol Neurosurg* 2001;103:123–6.
- [14] Kushner M, Reivich M, Alavi A, Greenberg J, Stern M, Dann R. Regional cerebral glucose metabolism in aphemias: a case report. *Brain Lang* 1987;31:201–14.
- [15] Carbary TJ, Patterson JP, Snyder PJ. Foreign accent syndrome following a catastrophic second injury: MRI correlates. *Brain Cogn* 2000;43:78–85.
- [16] Schiff HB, Alexander MP, Naeser MA, Galaburda AM. Aphemias. Clinical-anatomic correlations. *Arch Neurol* 1983;40:720–7.
- [17] Krainik A, Lehericy S, Duffau H, Capelle L, Chainay H, Cornu P, et al. Postoperative speech disorder after medial frontal surgery: role of the supplementary motor area. *Neurology* 2003;60:587–94.