

Occurrence of Intracerebral Aneurysm in an HIV-Infected Child: A Case Report

César A. Martínez-Longoria, MD*,
José J. Morales-Aguirre, MD*,
Claudia P. Villalobos-Acosta, MD*,
Demóstenes Gómez-Barreto, MD[†], and
Miguel Cashat-Cruz, MD, MSc*[‡]

A 12-year-old female diagnosed with human immunodeficiency virus infection at age 1 was admitted to our hospital with complaints of headache, left hemiparesis, and blurry vision. On admission, her CD4+ count was 97 cells/mm³ (13%) and her viral load 44,783 ribonucleic acid copies/mL. Treatment had been initiated 3 months before admission with lopinavir/ritonavir, lamivudine, and stavudine. A computed tomographic scan and magnetic resonance imaging of the head revealed an aneurysm of the right middle cerebral artery. A head angiographic scan was consistent with intracranial arteritis. Six months after the initiation of antiretroviral therapy, her CD4+ cell count was 226 cells/mm³ (16%) and her viral load was undetectable (less than 50 copies ribonucleic acid/mL). Magnetic resonance angiography of the head performed 15 months after the diagnosis demonstrated resolution of the aneurysm and the intracranial arteritis. This case highlights the association of human immunodeficiency virus infection with the occurrence of intracerebral aneurysms in the context of human immunodeficiency virus-vasculopathy, as well as its improvement with highly active antiretroviral therapy. © 2004 by Elsevier Inc. All rights reserved.

Martínez-Longoria CA, Morales-Aguirre JJ, Villalobos-Acosta CP, Gómez-Barreto D, Cashat-Cruz M. Occurrence of intracerebral aneurysm in an HIV-infected child: a case report. *Pediatr Neurol* 2004;31:130-132.

Introduction

An association between human immunodeficiency virus (HIV) infection and central nervous system abnormalities has been well documented. These abnormalities range from cognitive dysfunction to serious cerebrovascular diseases [1,2]. Neurologic abnormalities such as developmental delay, loss of developmental milestones, or a decline in motor and neurocognitive functions have been reported in over 80% of HIV-infected pediatric patients. In contrast, the incidence of serious cerebrovascular diseases (i.e., infarctions and aneurysms) has been reported to be 1.3%. However, autopsies have revealed lesions in over 25% of HIV pediatric cases [3].

The occurrence of cerebral aneurysms in nonimmunocompromised pediatric patients is rare. In contrast, 24 cases of cerebral aneurysms have been reported in HIV-infected children. These patients often develop clinical symptoms related to the aneurysms, and mortality is usually high. Because of the high risk of complications related to the aneurysms, the optimal medical or surgical management of these patients has not been well established. To our knowledge, this is the first report describing the resolution of a cerebral aneurysm in an HIV-infected infant treated with highly active antiretroviral therapy.

Case Report

A 12-year-old female with HIV infection presented to the Hospital Infantil de Mexico Federico Gomez on December 31, 2001 with complaints of generalized headache, transient left hemiparesis on two occasions, blurry vision, and decreased visual acuity in the left eye. Both of her parents had died of acquired immunodeficiency syndrome.

Her medical history was remarkable for repeated bouts of respiratory infections, varicella infection at 9 years, and gastroenteritis at 3, 5, and 11 years of age. She had been diagnosed with perinatally acquired HIV infection at age 1. The patient was initially treated with zidovudine, and subsequently she received zalcitabine and lamivudine. Three months before her admission, treatment had been changed to lopinavir-ritonavir (Kaletra), lamivudine, and stavudine.

On physical examination, she was malnourished and had hemianopsia of the left temporal visual field and left hemiparesia. The remainder of

From the *HIV-AIDS Immunodeficiency Clinic, [‡]Department of Epidemiology, and [†]Department of Infectious Diseases, Hospital Infantil de México Federico Gómez, México D. F., México.

Communications should be addressed to:
Dr. Cashat-Cruz; Departamento de Epidemiología; Hospital Infantil de México Federico Gómez; Dr. Márquez #162; Colonia Doctores; Delegación Cuauhtémoc; C.P. 06720 México D. F.; México.
Received August 18, 2003; accepted February 3, 2004.

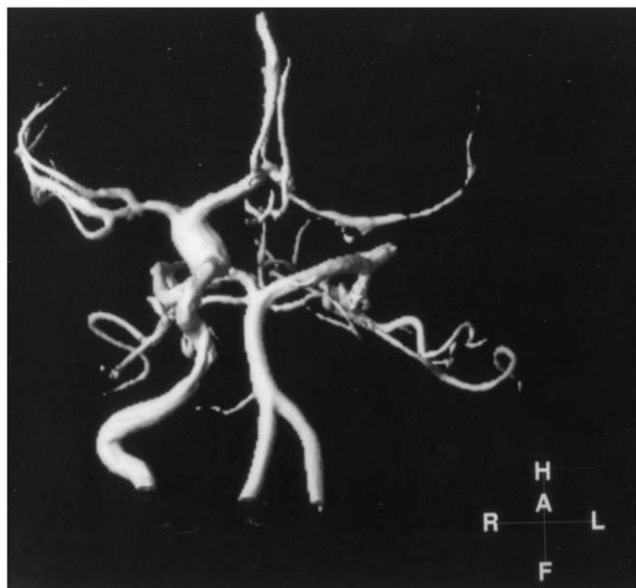


Figure 1. A three-dimensional reconstruction head magnetic resonance angiography revealing an aneurysmatic dilatation of the intracerebral portion of the right internal carotid artery that extends to the bifurcation and into the middle and anterior cerebral arteries. T_1 fast file echo; TR: 35 ms; TE: 2.6 ms; TR = 35 ms; TE = echo time 2.6 ms; FLIP = 25 degrees.

the examination was unremarkable. A computed tomographic scan of the head revealed an aneurysm of the right middle cerebral artery. A cerebral angiography and magnetic resonance imaging were subsequently performed. The head magnetic resonance imaging revealed an aneurysmatic dilatation of the intracerebral portion of the right internal carotid artery (Fig 1) and compensatory ventriculomegaly. The cerebral angiography revealed abnormalities suggestive of intracranial arteritis along with an aneurysm of the internal right carotid artery at the bifurcation of the anterior cerebral and middle cerebral arteries. There was total obstruction of the left internal carotid artery with supplemental circulation through the circle of Willis. In addition, there was a zone of stenosis of the infraclinoid portion of the right carotid artery, likely related to vasculitis or arterial dissection. The patient was managed conservatively as the aneurysm that was identified had a low risk of rupture and was likely the result of HIV vasculopathy. The patient was treated with aspirin (325 mg/day) to decrease the risk of infarction due to the vascular inflammatory response.

Six months after initiating highly active antiretroviral therapy, she had a favorable immunologic response (226 CD4+ cells, 16%) and her viral load was undetectable (<50 copies ribonucleic acid/mL). Magnetic resonance imaging performed 15 months after the diagnosis indicated complete resolution of the aneurysm (Fig 2). After 24 months of follow-up, the patient has continued to improve clinically with no subsequent ischemic events and with almost complete neurologic recovery.

Discussion

A number of neurologic abnormalities have been described in both HIV-infected children and adults. These abnormalities included acquired microcephalia, basal ganglia calcifications, HIV encephalopathy, cognitive dysfunction, a delay in psychomotor development, and HIV-associated vasculopathy with the presence of cerebral aneurysms [2,4]. At postmortem examination, 10% to 30% of pediatric HIV-infected patients present evidence of

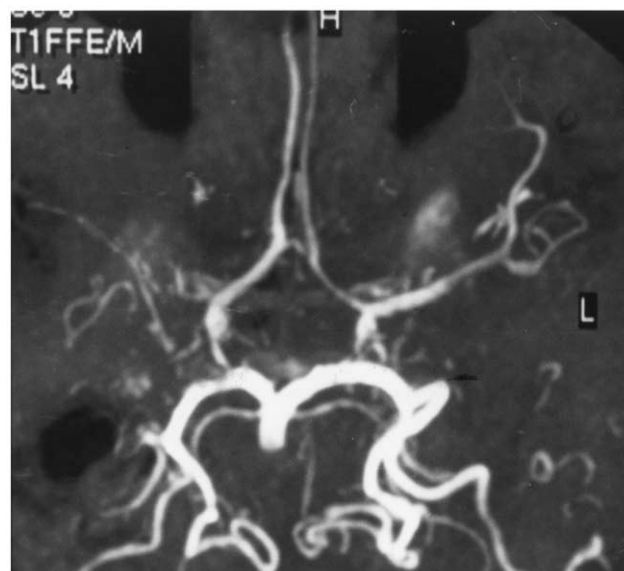


Figure 2. Subsequent head magnetic resonance angiography documents resolution of intracerebral aneurysm and vasculitis. Maximal intensity projection. T_1 fast file echo; TR: 35 ms; TE: 2.6 ms; TR = 35 ms; TE = echo time 2.6 ms; FLIP = 25 degrees.

cerebral infarction. Cerebral vasculitis may occur secondary to direct viral invasion, or aneurysms may develop as a result of HIV-induced vasculopathy [5]. Aneurysms have been reported to occur 5 to 18 years after the onset of HIV infection in both children and adults [6-9]. However, vascular abnormalities can occur in HIV-infected pediatric patients within 1 month to 2 years of diagnosis [6,10].

In a retrospective study of 426 HIV-infected children, the incidence of cerebral infarctions and cerebral aneurysms was 2.6% and 1.6%, respectively. This incidence is considerably higher than that reported in non-HIV-infected children. Multiple aneurysms were a common finding (57%), and 92% were fusiform aneurysms. Ischemic infarctions were associated to 57% of the aneurysms [11].

To date, 24 cases of cerebral aneurysms have been reported in HIV-infected children [3,6-8,10,12-14]. As in the case reported here, the location of the aneurysm has been at the basal arteries of the circle of Willis. The majority of these patients manifested symptoms related to the aneurysm, including seizures, transitory ischemic events, hemiparesis or paraparesis, aphasia, motor deficits, and even fatal intracerebral hemorrhage [3-8,13]. The major pathologic findings identified in the affected arteries are intimal hyperplasia, fibrosis of the media, endothelial hyperplasia, thinning of the media, microcalcifications, loss of muscularis, and destruction of the elastic internal layer, with the presence of infiltrates of mononuclear cells expressing HIV antigens in the endothelial surface of the affected vessels [3,7,12,13,15,16]. Similar to our patient, in most of the reported cases the patients had elevated viral loads and CD4+ cell counts below 15% [3,6-10]. An association with other opportunistic infections has been

proposed as the possible cause of these aneurysms in HIV-infected children. These agents include varicella zoster virus, herpes simplex virus, cytomegalovirus, cryptococcus, and mycobacteria [3,8,10,17].

Although the mechanisms by which HIV leads to cerebral aneurysms remain undefined, it seems that the HIV virus itself may have an effect on the intima of the vessels, resulting in arterial damage [12]. Mazzoni et al. [9] reported a patient with arteriopathy in whom the progression of disease arrested after initiation of highly active antiretroviral therapy, providing some support for this hypothesis. In the majority of pediatric cases reported in the literature, children were treated with monotherapy (before the availability of highly active antiretroviral therapy) and adverse outcomes were frequent. In our case, there was a complete resolution of the aneurysm 15 months after the initiation of highly active antiretroviral therapy, suggesting, as in the case reported by Mazzoni et al., that treatment with highly active antiretroviral therapy may have led to the resolution of the aneurysm, as well as the vasculitis.

The optimal management of these patients has not been well established given the high risk for complications, such as thromboembolic phenomena and fatal hemorrhages during surgical repair. Although 18 of the 24 patients have died, it is unknown if their deaths were the result of intracranial bleeding or of opportunistic infections.

It remains to be determined whether highly active antiretroviral therapy will decrease the incidence of HIV-induced vasculopathy; however, the present case suggests that it may have a significant impact in preventing sequelae associated with HIV vasculopathy.

The authors would like to thank Dr. Jesus Vallejo and Dr. Blanca Gonzalez for their help in the preparation of the manuscript.

References

- [1] **Simpson** DM, Tagliati M. Neurologic manifestations of HIV infection. *Ann Intern Med* 1994;121:769-85.
- [2] **Epstein** LG, Sharer LR, Oleske JM, et al. Neurologic manifestations of human immunodeficiency virus infection in children. *Pediatrics* 1986;78:678-87.
- [3] **Dubrovsky** T, Curless R, Scott G, et al. Cerebral aneurysmal arteriopathy in childhood AIDS. *Neurology* 1998;51:560-5.
- [4] **Chetty** R, Batitang S, Nair R. Large artery vasculopathy in HIV-positive patients: Another vasculitic enigma. *Hum Pathol* 2000;31:374-9.
- [5] **Carlin** TM, Chanmugam A. Stroke in children. *Emerg Med Clin North Am* 2002;20:671-85.
- [6] **Husson** RN, Saini R, Lewis LL, Butler KM, Patronas N, Pizzo PA. Cerebral artery aneurysms in children infected with human immunodeficiency virus. *J Pediatr* 1992;121:927-30.
- [7] **Carvalho Neto** AD, Bruck I, Coelho LO, et al. Cerebral artery aneurysm in a child with acquired immunodeficiency syndrome: Case report. *Arq Neuropsiquiatr* 2001;59:444-8.
- [8] **Fulmer** BB, Dillard SC, Musulman EM, Palmer CA, Oakes J. Two cases of cerebral aneurysms in HIV+ children. *Pediatr Neurosurg* 1998;28:31-4.
- [9] **Mazzoni** P, Chiriboga CA, Millar WS, Rogers A. Intracerebral aneurysms in human immunodeficiency virus infection: Case report and literature review. *Pediatr Neurol* 2000;23:252-5.
- [10] **Nunes** ML, Pinho AP, Sfoggia A. Cerebral aneurysmal dilatation in an infant with perinatally acquired HIV infection and HSV encephalitis. *Arq Neuropsiquiatr* 2001;59:116-8.
- [11] **Patsalides** AD, Wood LV, Atac GK, Sandifer E, Butman JA, Patronas NJ. Cerebrovascular disease in HIV-infected pediatric patients: Neuroimaging findings. *AJR Am J Roentgenol* 2002;179:999-1003.
- [12] **Park** YD, Belman AL, Kim TS, et al. Stroke in pediatric acquired immunodeficiency syndrome. *Ann Neurol* 1990;28:3003-11.
- [13] **Kure** K, Park YD, Kim TS, et al. Immunohistochemical localization of an HIV epitope in cerebral aneurysmal arteriopathy in pediatric acquired immunodeficiency syndrome (AIDS). *Pediatr Pathol* 1989;9:655-67.
- [14] **Visrutaratna** P, Oranratanachai K. Clinics in diagnostic imaging. HIV encephalopathy and cerebral aneurysmal arteriopathy. *Singapore Med J* 2002;43:377-80.
- [15] **Shah** SS, Zimmerman RA, Rorke LB, Vezina LG. Cerebrovascular complications of HIV in children. *Am J Neuroradiol* 1996;17:1913-7.
- [16] **Lang** C, Jacobi G, Kreuz W, et al. Rapid development of giant aneurysm at the base of the brain in an 8-year-old boy with perinatal HIV infection. *Acta Histochem Suppl* 1992;42:83-90.
- [17] **Amlie Lefond** C, Kleinschmidt-DeMasters BK, Mahalingam R, Davis LE, Gilden DH. The vasculopathy of varicella zoster virus encephalitis. *Ann Neurol* 1995;37:784-90.