

Acute Ischemic Stroke Successfully Treated Using Sequenced Intravenous and Intra-Arterial Thrombolysis and Argatroban Anticoagulation: A Case Study

Marian P. LaMonte MD, MSN,¹ M.J. Bernadette Stallmeyer MD, PhD²

¹Departments of Neurology and Surgery and ²Departments of Radiology and Neurosurgery, University of Maryland School of Medicine, Baltimore, MD

Abstract. Background: Direct thrombin inhibitors, a class of anticoagulants distinct from heparins, have not been evaluated for immediate use after thrombolytic therapy in acute ischemic stroke. We report a case of ischemic stroke and prothrombotic state treated using sequenced intravenous and intra-arterial thrombolytic therapy and argatroban anticoagulation.

Case Description: A 19-year-old man with a complicated history of recurrent life-threatening thrombosis presented at the emergency department with acute ischemic stroke. The patient received standard-dose intravenous alteplase starting 2.25 hours after symptom onset without change in his global aphasia and right hemiparesis. Five hours after symptom onset, intra-arterial reteplase was administered for treatment of a left internal carotid "T" occlusion, with successful recanalization of the left internal carotid artery, A1 and M1 segments, and right middle cerebral anterior division and with improvement in symptoms. Argatroban therapy was started after completion of intra-arterial thrombolysis, i.e., 8.5 hours after symptom onset, and was maintained for 14 days. Although the patient sustained a small left basal ganglia infarct, he improved significantly over the course of therapy and was discharged to home without bleeding or further thrombotic episodes.

Conclusions: Sequenced intravenous and intra-arterial thrombolytic therapy and argatroban anticoagulation was used successfully to safely treat a patient with ischemic stroke and comorbid prothrombotic state within 8.5 hours of symptom onset.

Key Words. acute stroke, argatroban, thrombin inhibitors, thrombolytic therapy

Introduction

Many physicians—30 to 88% of U.S. neurologists in a recent survey—see clinical needs for early anticoagulation in acute ischemic stroke [1]. Current guidelines recommend against initiating anticoagulant therapy within 24 hours of intravenous thrombolytic therapy for acute ischemic stroke [2]. This restriction is based on the regimen used during the clinical trial that established the efficacy and safety of intravenous tissue plasminogen activator (tPA) in

this setting [3]. When that trial was conducted, available parenteral anticoagulants were heparin and its derivatives. More recently, direct thrombin inhibitors, including argatroban, have become commercially available. These inhibitors, which represent a class of anticoagulants distinct from heparins, have not been evaluated for immediate use after thrombolytic therapy in ischemic stroke. We report the first case, to our knowledge, of sequenced intravenous and intra-arterial thrombolytic therapy and argatroban anticoagulation for treating ischemic stroke and prothrombotic state within 8.5 hours of symptom onset.

Case Description

A 19-year-old man presented to the emergency department 30 minutes after acute onset of aphasia and right-sided hemiparesis. His medical history was remarkable for recurrent life-threatening thrombosis. At 17 years of age, he developed right ventricular thrombosis with bilateral pulmonary arterial emboli, which was treated with heparin and surgical thrombectomy. A few days following surgery, warfarin was initiated. The first day after a therapeutic international normalized ratio (INR) was achieved, and despite continued heparin and warfarin therapy, recurrent right ventricular thrombus and extensive venous thrombosis were discovered. The patient received thrombolytic therapy and was discharged on therapeutic subcutaneous enoxaparin. Two months later, he experienced acute shortness of breath. A computerized tomographic (CT) scan revealed an old, occlusive thrombus in the right pulmonary artery. This was treated with stent placement in the right pulmonary artery, but the procedure was complicated by thromboembolization to

Address for correspondence: Marian P. LaMonte, M.D., University of Maryland School of Medicine, 22 South Greene St., Room N4W46, Baltimore, MD 21201-1595, USA. Tel.: 410-328-5801; Fax: 410-328-5899; E-mail: mlamonte@umm.edu

the left pulmonary artery. Local thrombolytic therapy improved perfusion in both lungs. The next month he received intravenous thrombolytic therapy for suspected thrombosis near the stent. During the following year, the patient experienced multiple transient episodes of lightheadedness, localized numbness and tingling, slurred speech, and chest pain. He was evaluated during each episode, and because symptoms were transient, he was maintained on the same therapy. Six months before the current presentation and after missing doses of enoxaparin, the patient experienced a transient ischemic attack of expressive aphasia, for which he received intravenous heparin. He was discharged on enoxaparin and aspirin but was noncompliant. Despite multiple intensive laboratory evaluations for congenital or acquired thrombophilias since his initial thromboses, the etiology of the coagulopathy remained unknown.

During the current presentation, a CT scan of the head revealed a dense left middle cerebral artery (LMCA), without evidence of hemorrhage or early signs of infarction. At admission, the National Institute of Health Stroke Scale score (NIHSS) was 12, INR was 1.1, and activated partial thromboplastin time (aPTT) was 31 seconds. After verification of patient eligibility for thrombolysis, a right femoral arterial sheath was placed in anticipation of performing intra-arterial thrombolysis if he failed to respond to intravenous thrombolytic therapy. Standard-dose intravenous alteplase was initiated 2.25 hours after symptom onset, without improvement of symptoms. Cerebral angiography revealed an occlusion of the distal left internal carotid artery (LICA), with extension of thrombus into the left A1 and M1 segments (Fig. 1). The clot was gently fenestrated using a microguidewire, and intra-arterial thrombolysis with reteplase (9 mg) was initiated 5 hours after symptom onset. Flow was quickly restored in the LICA and left A1 and M1 segments, but more distal LMCA branches were only partially recanalized (Fig. 2). Symptoms improved partially. Head CT performed immediately following angiography revealed a region of hyperdensity in the left caudate and lentiform nucleus (Fig. 3), thought to be caused by contrast leakage rather than hemorrhage. This conclusion was based on two observations: (1) contrast staining had been observed in the basal ganglia during angiography and (2) repeat head CT at 2-hour intervals showed rapid resolution of the hyperdensity. This rapid resolution is not consistent with hemorrhage. Because the patient's prior episodes suggested extended thrombin storm in conjunction with thrombotic events, and because his history of thrombosis despite heparinization suggested the possibility of heparin-induced thrombocytopenia (HIT) with thrombosis, anticoagulation with a direct thrombin inhibitor was begun. Intravenous

argatroban 2 mcg/kg/min was initiated without a bolus 8.5 hours after symptom onset and adjusted to achieve a goal aPTT of 1.5 times the baseline aPTT. Serial head CT scans performed starting 3 hours after angiography revealed progressive resolution of contrast staining and a small residual basal ganglia infarct. Argatroban therapy was continued for 14 days, with the goal aPTT increased to 2 times baseline starting on the fourth day, and with overlapping warfarin administration starting on the sixth day. A stable therapeutic level of oral anticoagulation (INR 3.4) was achieved without incident. The patient improved significantly during his hospitalization and was discharged to home (NIHSS 2) on warfarin and aspirin.

Discussion

We report the successful use of sequenced intravenous and intra-arterial thrombolysis and argatroban therapy started within 8.5 hours of onset of ischemic stroke in a young man. The strategy of combining intravenous and intra-arterial tPA has been associated in clinical trial with achievement of recanalization and a reasonable degree of safety [4]. The patient's complicated history of recurrent thrombosis and possibility of HIT contributed to the decision to initiate anticoagulant therapy immediately after thrombolysis.

Argatroban is a direct thrombin inhibitor that, unlike heparins, effectively inhibits both soluble and clot-bound thrombin, including thrombin in aged or alteplase-treated clots, and does not require the cofactor antithrombin for anticoagulant activity [5,6]. We selected argatroban as the anticoagulant of choice in our patient because of its positive safety profiles in HIT [7–9], ischemic stroke [9–11], and interventional procedures [12], coupled with the known risk of intracerebral hemorrhage associated with heparin, low-molecular-weight heparin, or heparinoid therapy following large cerebral infarction [2]. In controlled clinical trials, major bleeding rates with argatroban have been comparable with the rate associated with placebo in patients treated within 12 hours of ischemic stroke [10] and at least comparable with those of heparin in patients with acute myocardial infarction receiving alteplase and parenteral anticoagulation [13,14]. No intracranial hemorrhage has occurred in more than 400 patients with acute myocardial infarction given argatroban and alteplase [15] or more than 800 patients with HIT during argatroban therapy [7,8]. Among its other uses, argatroban is currently available in North America as an anticoagulant for prophylaxis or treatment of thrombosis in HIT [7,8] and in Japan for the treatment of large-artery atherosclerotic stroke [11].

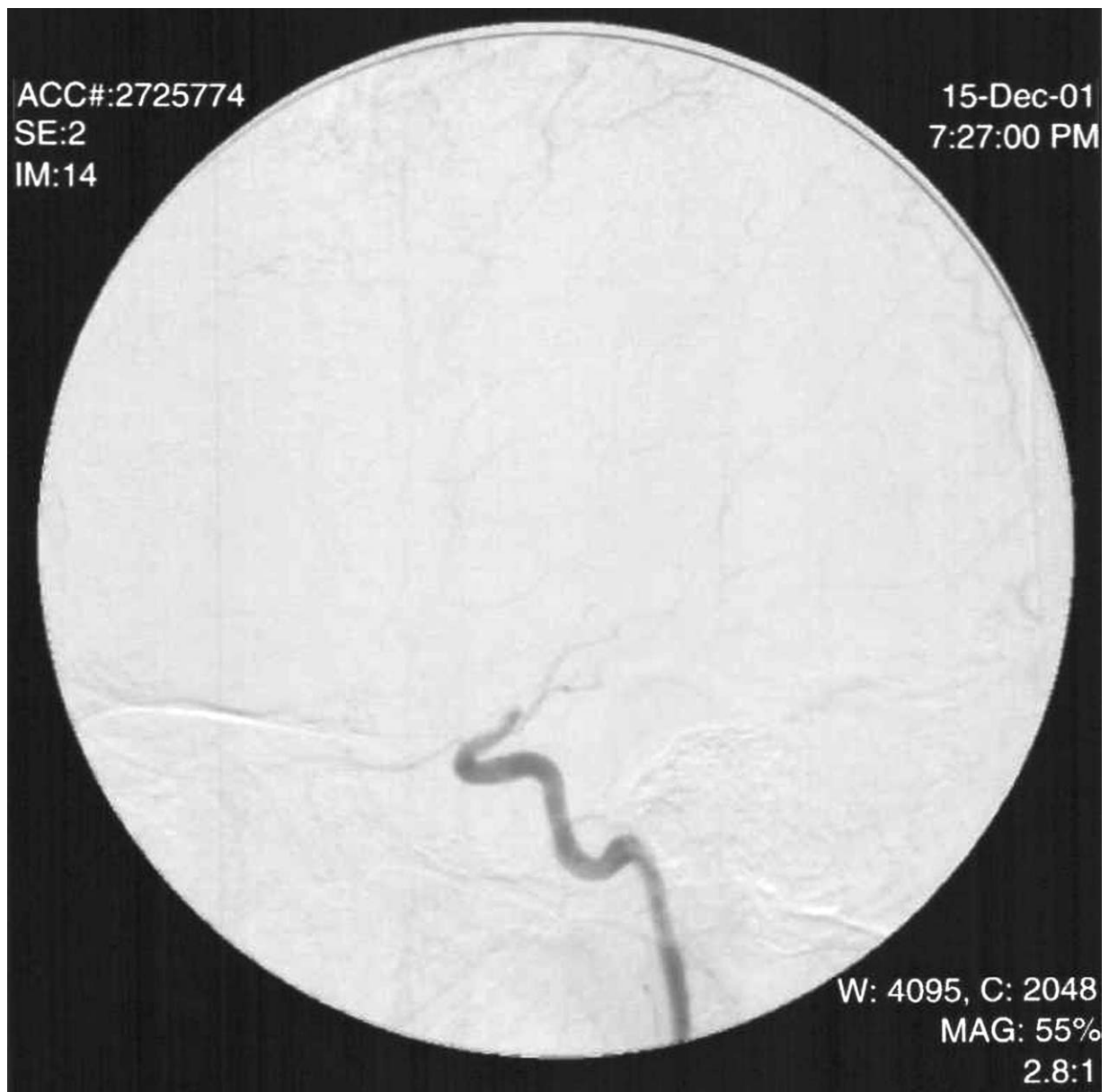

Fig. 1. Left internal carotid artery (LICA) angiogram, AP projection, demonstrating LICA “T-lesion,” with extension of thrombus into the left A1 and M1 segments.

The decision for anticoagulant therapy was also weighed carefully, given the initial CT findings after thrombolysis, wherein a small hyperdense region was noted. Because the parenchymal phase of angiography demonstrated this same finding, contrast stain extravasation rather than hemorrhage was deemed most likely, and serial CT scans (and clinical outcome) confirmed this interpretation.

Because of the patient’s past thromboses while on heparin and warfarin, the treating team could not initially rule out the possibilities of HIT or hy-

percoagulability associated with the early phase of warfarin therapy in an individual not fully anticoagulated with heparin. Following warfarin initiation, levels of the vitamin-K–dependent anticoagulant proteins C and S decline rapidly, resulting in decreased inhibition of the procoagulant factors VIIIa and VIIa, an upsurge in thrombin generation, and a transient hypercoagulable condition [16]. Until stable oral anticoagulation is achieved, patients typically receive heparin to ensure adequate anticoagulation; however, heparin must be avoided in HIT.

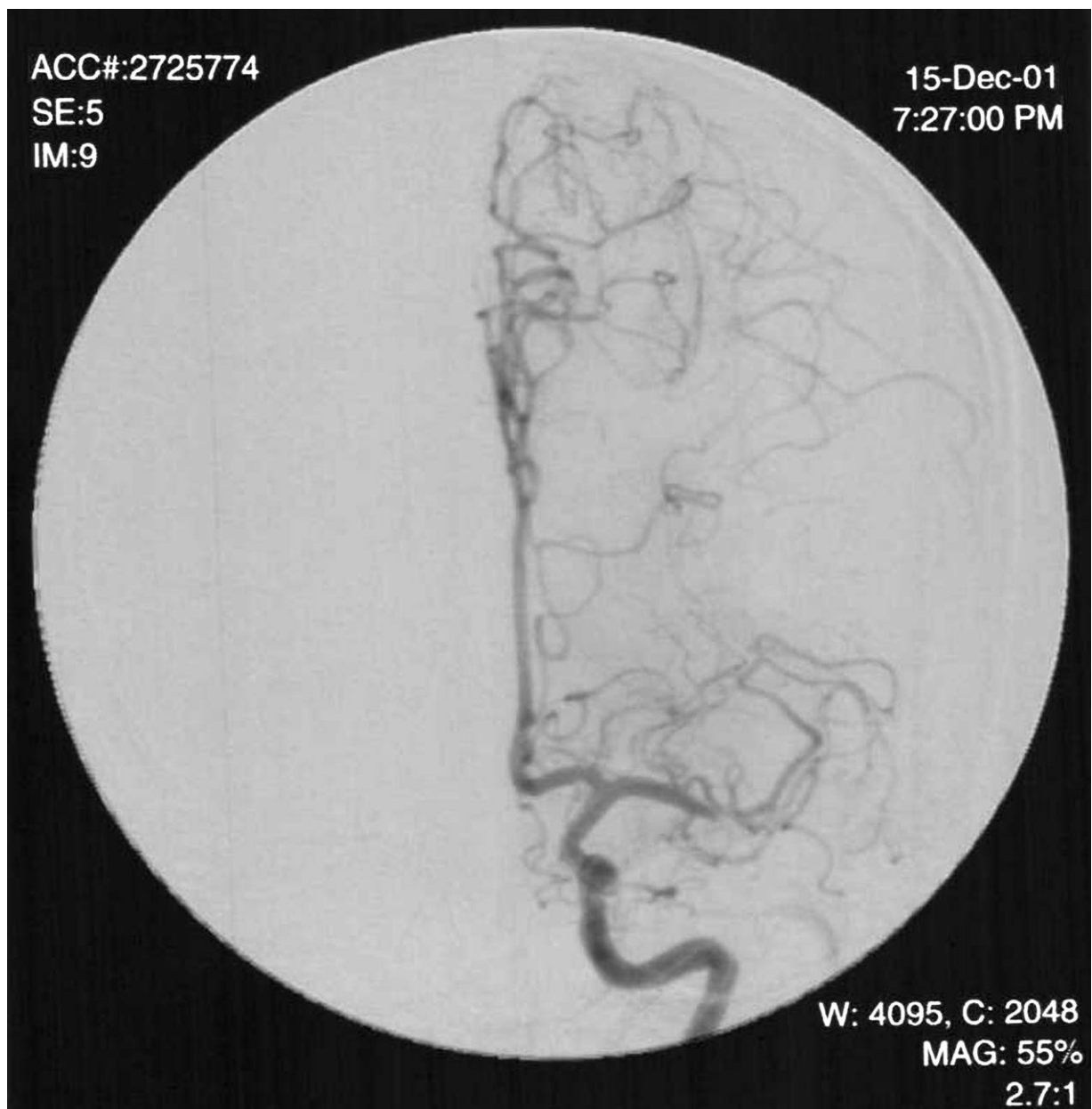


Fig. 2. Left internal carotid artery (LICA) angiogram, AP projection, demonstrating recanalization of the left anterior cerebral artery (LACA) and partial recanalization of the left middle cerebral artery (LMCA) following gentle mechanical fenestration of the clot with the microcatheter and intra-arterial reteplase treatment.

HIT is a potentially catastrophic, prothrombotic disorder triggered by heparin, wherein approximately 50% of patients managed by heparin cessation alone develop thrombosis, e.g., stroke [17]. Argatroban therapy, versus historical control, significantly improves clinical outcomes in HIT, including reducing new stroke and stroke-associated mortality, without increasing bleeding [7–9]. For our patient with acute ischemic stroke, hypercoagulability of unclear etiology, and a clinical question of HIT, argatroban

therapy initiated within 8.5 hours of stroke onset provided safe anticoagulation after intravenous and intra-arterial thrombolysis, without bleeding or further thrombosis.

A study is currently underway to evaluate the concurrent use of tPA and argatroban therapy in acute ischemic stroke. This case suggests that a study to evaluate the utility of early initiation of argatroban after thrombolytic therapy in ischemic stroke may also be warranted.

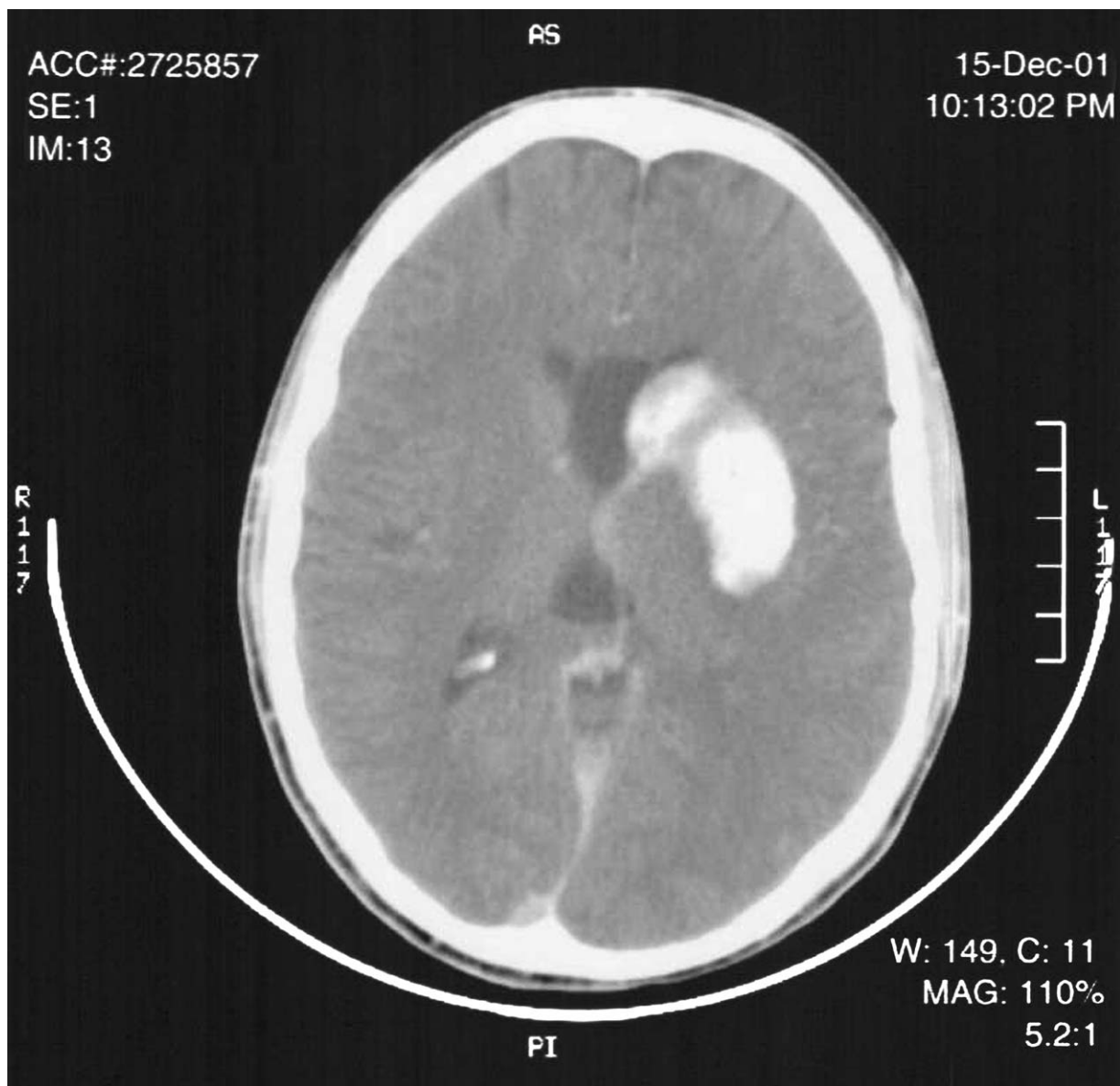


Fig. 3. Post-angiogram computerized tomographic scan showing hyperdensity representing contrast staining in left caudate and lentiform nucleus.

Acknowledgments

We thank Marcie J. Hursting, PhD, Philip M. Brown, MD, JD, and Linda Kesselring, MS, ELS, for their editorial assistance and critical review of this case report.

References

1. Al-Sadat A, Sunbulli M, Chaturvedi S. Use of intravenous heparin by North American neurologist: Do the data matter? *Stroke* 2002;33:1574–1577.
2. Adams HP, Adams RJ, Brott T, et al. Guidelines for the early management of patients with ischemic stroke: A scientific statement from the Stroke Council of the American Stroke Association. *Stroke* 2003;34:1056–1083.
3. The National Institute of Neurological Disorders, and Stroke rt-PA Stroke Study Group. Tissue plasminogen activator for acute ischemic stroke. *N Engl J Med* 1995;333:1581–1587.
4. Lewandowski CA, Frankel M, Tomsick TA, et al. Combined intravenous and intra-arterial r-TPA versus intra-arterial therapy of acute ischemic stroke: Emergency Management of Stroke (EMS) Bridging Trial. *Stroke* 1999;30:2598–2605.
5. Okamoto S, Okunomiya-Hijikata A. Synthetic selective inhibitors of thrombin. *Methods Enzymol* 1993;222:328–340.

6. Hantgan RR, Jerome WG, Hursting MJ. No effect of clot age or thrombolysis on argatroban's inhibition of thrombin. *Blood* 1998;92:2064–2074.
7. Lewis BE, Wallis DE, Berkowitz SD, et al. Argatroban anticoagulant therapy in patients with heparin-induced thrombocytopenia. *Circulation* 2001;103:1838–1843.
8. Lewis BE, Wallis DE, Leya F, Hursting MJ, Kelton JG. Argatroban anticoagulation in patients with heparin-induced thrombocytopenia. *Arch Intern Med*. 2003;163:1849–1856.
9. LaMonte MP, Brown PM, Berens KL. Reduction in stroke-associated mortality in patients with heparin-induced thrombocytopenia after treatment with the direct thrombin inhibitor argatroban [abstract]. *Stroke* 2002;33:382.
10. LaMonte MP. Results of ARGIS-1: Argatroban injection for acute ischemic stroke [abstract]. *Stroke* 2003;34:246.
11. Kobayashi W, Tazaki Y. Effect of the thrombin inhibitor argatroban in acute cerebral thrombosis. *Sem Thromb Hemost* 1997;23:531–534.
12. Lewis B, Matthai WH, Cohen M, Moses JW, Hursting MJ, Leya F, for the ARG-216/310/311 investigators. Argatroban anticoagulation during percutaneous coronary intervention in patients with heparin-induced thrombocytopenia. *Catheter Cardiovasc Interv* 2002;57:177–184.
13. Jang I-K, Brown DFM, Giugliano RP, et al. A multicenter, randomized study of argatroban versus heparin as adjunct to tissue plasminogen activator (TPA) in acute myocardial infarction: Myocardial infarction with Novastan and TPA (MINT) trial. *J Am Coll Cardiol* 1999;33:1879–1885.
14. Vermeer F, Vahanian A, Fels PW, et al. Argatroban and alteplase in patients with acute myocardial infarction: The ARGAMI study. *J Thromb Thrombolysis* 2000;10:233–240.
15. Argatroban Injection [package insert]. Philadelphia, PA: GlaxoSmithKline, April 2002.
16. Stirling Y. Warfarin-induced changes in procoagulant and anticoagulant proteins. *Blood Coagul Fibrinolysis* 1995;6:361–373.
17. Warkentin TE, Kelton JG. A 14-year study of heparin-induced thrombocytopenia. *Am J Med* 1996;101:502–507.