

# Perinatal/Neonatal Case Presentation

## Temporal Lobe Hemorrhage in the Full-Term Neonate Presenting as Apneic Seizures

Jeffrey J. Tramonte, MD

Howard P. Goodkin, MD, PhD

We describe a 1-day-old neonate born after 39 weeks of gestation with the unusual presentation of apneic seizures. He manifested apnea during the first 12 hours of life. Prolonged video electroencephalography (EEG) monitoring captured electrographic seizures in the right centro-temporal region, which correlated with the onset and duration of clinical bouts of apnea and oxygen desaturation. The longest event lasted more than 2 minutes, without development of bradycardia. The clinical seizures resolved after administration of phenobarbital with normalization of the EEG several days later. Head ultrasound disclosed an echogenic mass in the right temporal lobe, corroborated as hemorrhage on brain magnetic resonance imaging. This report emphasizes the importance of EEG in the evaluation of full-term neonates with recurrent unexplained apnea.

*Journal of Perinatology* (2004) **24**, 726–729. doi:10.1038/sj.jp.7211181

### INTRODUCTION

Apnea is the cessation of breathing that may result from obstructive, central, or mixed factors. In the newborn, apnea can result from airway obstruction, pneumonia, sepsis, gastroesophageal reflux, pulmonary disease, cardiac arrhythmias, immaturity of brainstem control mechanisms, intraventricular hemorrhage of prematurity, or subarachnoid hemorrhage. It can also be the sole manifestation of a seizure.<sup>1–4</sup>

We have recently cared for a full-term neonate with recurrent apnea that commenced during the perinatal period. Bedside polygraphic monitoring with electroencephalography (EEG) demonstrated the presence of focal electrographic seizures originating in the right centro-temporal region that were time-locked with the periods of apnea. Apnea was the sole clinical manifestation of these seizures. The seizures resolved after administration of phenobarbital. Head ultrasound and magnetic

resonance imaging (MRI) evaluation disclosed a right temporal lobe hemorrhage. Although full-term neonates rarely present with apneic seizures, this case and the scant available literature demonstrate the need to consider continuous polygraphic monitoring with EEG in the full-term neonate who presents with recurrent unexplained apnea.

### CASE REPORT

This neonate was transferred to our institution on day of life 1 for further evaluation of recurrent apnea. He weighed 3.9 kg following an uncomplicated, 39-week gestation and spontaneous vaginal delivery augmented with misoprostol and oxytocin to a 36-year-old G3P2 woman. Apgar scores were 9 and 9 at 1 and 5 minutes, respectively. Erythromycin and vitamin K were administered shortly after birth, and he was discharged from the delivery room to the newborn nursery. Within the first 6 hours of life, he was observed to have recurrent periods of apnea of 20 to 165 seconds duration. Pulse oximetry demonstrated oxygen saturations as low as 50% during the period of apnea. No change in heart rate was observed during these events. No movements suggesting focal or multifocal tonic, clonic, myoclonic, or subtle seizures were noted. No consistent eye deviation was appreciated. During these events, he received “blow-by” oxygen.

His examination at the time of transfer to our facility on day of life 1 showed a head circumference of 37.5 cm (83%). His vital signs included temperature 36.9°C, blood pressure 66/34 mmHg, mean arterial pressure 49 mmHg, heart rate 120 bpm, respirations 45 to 60/minute, and O<sub>2</sub> saturations 90 to 98% on room air. General examination was significant for the presence of a cephalhematoma. No persistent neurologic deficits were found: he roused to touch and sound. He blinked to threat, and his gaze was full. His pupils were equal in size and normally reactive to light. His suck and gag reflexes were normal and he had a symmetric startle (Moro) reflex. Muscle tone was age-appropriate, and limb movements and muscle stretch reflexes at the biceps and patella were all normal and symmetric.

Laboratory studies completed prior to transfer demonstrated: (1) WBC 20.6, Hgb 19.1, HCT 60.0, Plt 281 with a differential of 8% bands, 64% neutrophils, 18% lymphocytes, 8% monocytes, 2% eosinophils, (2) normal serum electrolytes, renal function, and acid–base balance, (3) blood and urine cultures were obtained prior to transfer and were without growth.

Upon arrival to our neonatal intensive care unit, continuous bedside polygraphic monitoring with EEG commenced. The EEG

Department of Neurology (J.J.T., H.P.G.), University of Virginia, Charlottesville, VA, USA; and Department of Pediatrics (H.P.G.), University of Virginia, Charlottesville, VA, USA.

Address correspondence and reprint requests to Howard P. Goodkin, MD, PhD, Department of Neurology and Pediatrics, University of Virginia, PO Box 800394, Charlottesville, VA 22908, USA.

demonstrated numerous electrographic seizures emanating predominantly from the right centro-temporal region characterized by sharply contoured alpha activity evolving into periodic sharp and slow wave activity followed by rhythmic delta activity (Figure 1a–c). The longest recorded electrographic seizure lasted 205 seconds. Each electrographic seizure was accompanied by the clinical manifestation of apnea and oxygen desaturation. No clinical convulsive activity was noted during direct observation by the authors and upon review of the digital video. There were no changes in heart rate. No spells of apnea and desaturation were unaccompanied by electroconvulsive changes. The patient was loaded with phenobarbital with a serum level the following day of 17.5 µg/ml, and an approximate 90% decrease in seizure frequency. After more phenobarbital was administered to reach a blood level of 30.7 µg/ml, no further apnea or desaturation spells were noted. An EEG 5 days later was normal for conceptional age. Head ultrasonography demonstrated a large complex echogenic mass in the right temporal lobe measuring  $3.0 \times 2.5 \times 2.9$  cm, most likely a hemorrhage. Cranial MRI confirmed a right temporal intraparenchymal hemorrhage with adjacent subdural hematoma in the middle cranial fossa and subarachnoid hemorrhage (Figure 2). MRA and MRV were both normal.

## DISCUSSION

This is a rare and unusual case of temporal lobe hemorrhage in a full-term newborn presenting with recurrent apneic seizures but no other clinical manifestations of seizure. There were no examination findings (e.g., hemiparesis or gaze preference) to suggest the presence of a lobar hemorrhage or other structural cause of focal brain dysfunction.

Apneic seizure is a term of some controversy as isolated apnea without other phenomena as a manifestation of seizure is rare. Published cases of neonates with apnea and ictal discharges often include additional seizure types in these neonates (e.g., clonic, tonic, hemiconvulsive) and the apnea is usually associated with other clinical changes such as staring, mouth movements, or eye movements. Giroud et al.<sup>5</sup> described four term neonates with apnea and electrographic seizures, all of whom shared additional motor movements with apnea. Watanabe et al.<sup>1</sup> described 19 term neonates with apnea and electrographic seizures, of which 11 had subtle associated clinical phenomena (e.g., eye opening, staring, eye movements, mouth movements), 12 had other seizure types, and only three were purely apneic without these aforementioned phenomena.<sup>1</sup> Monod et al.<sup>4</sup> described four term neonates with apnea and electrographic seizures, only one of whom was solely apneic without additional phenomena. Others have cited personal experience testifying to the rarity of pure respiratory ictal phenomena.<sup>6</sup>

Apneic seizures are not confined to the neonatal time period. Ramelli et al.<sup>7</sup> have documented apnea as the sole manifestation of

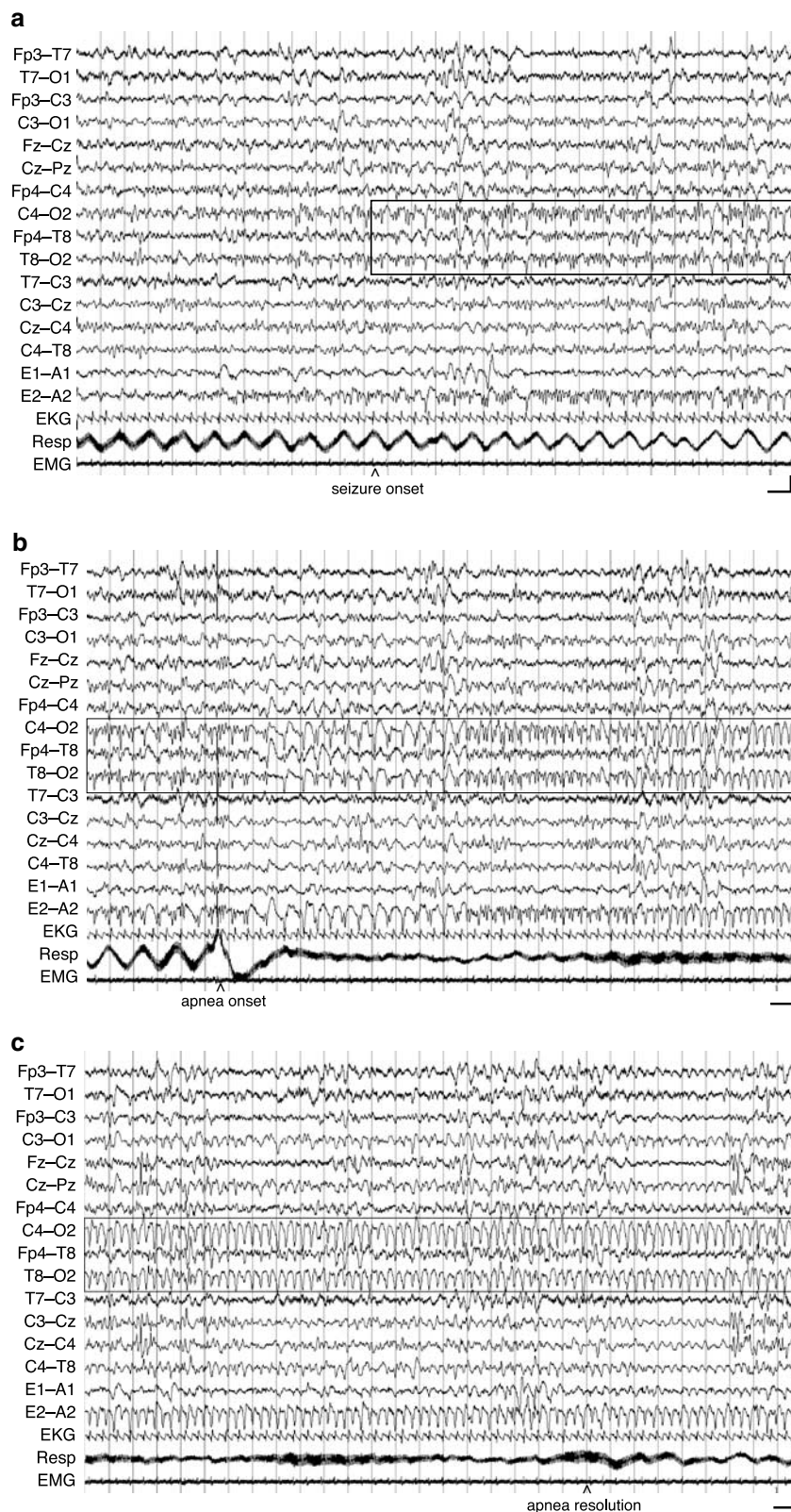
seizures in four infants of 2 to 11 months of age. Similarly, there have been case reports of infants presenting at around 2 to 3 months of age with episodes of apnea and bradycardia whose diagnosis of seizures were not established until later when captured with electroencephalography.<sup>8–10</sup>

A temporal focus of electrographic seizures has been reported in other neonates with apneic seizures. However, the etiology of central nervous system dysfunction in these newborns was usually hypoxia, meningitis, or electrolyte disturbance.<sup>1</sup> Limbic localization for apneic seizures has been suggested by Nelson et al.<sup>11</sup> who summarized observations and experimental stimulation studies implicating that seizure discharges in the limbic system produce respiratory arrest, however, the discharges need not be temporal in focus.

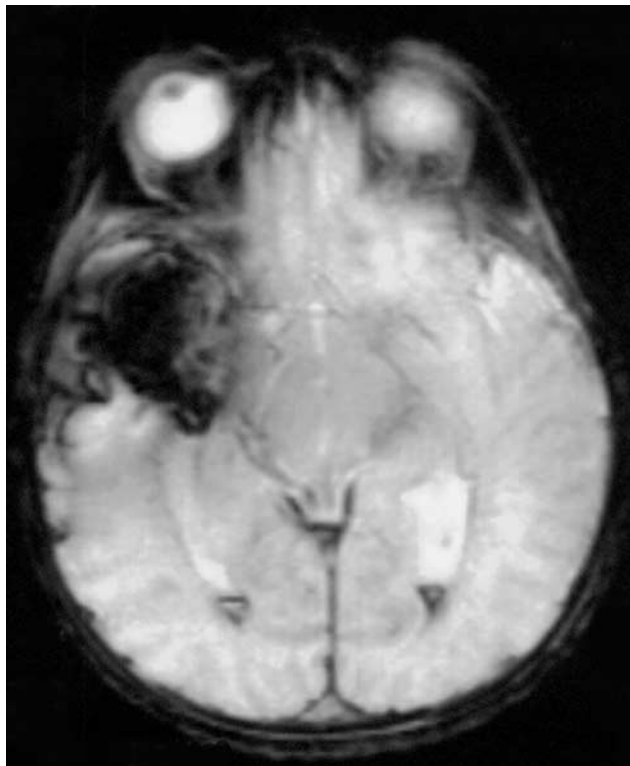The prompt detection of seizures in the neonate is paramount, as initiation of further evaluation should rapidly ensue to delineate a cause and antiepileptic medications should likely not be delayed. While electroencephalographic monitoring is the only tool available to diagnose ictal apnea, routine electroencephalographic monitoring of all neonates with apnea is not feasible. Fenichel et al.<sup>12</sup> monitored 112 episodes of apnea in 15 neonates (six premature infants and nine full term infants). Focal electrographic seizures that correlated with the periods of apnea were observed in four of these neonates, all full term. Bridgers et al.<sup>13</sup> found none of 153 apneic events in 37 neonates to be associated with focal electrographic seizures; however, they note that one full-term neonate with a 6-day history of apneic episodes was discovered to have electrographic seizures on cassette electroencephalographic recording prompting treatment with phenobarbital associated with the resolution of the apnea.<sup>13</sup> More recently, da Silva et al.<sup>14</sup> reviewed the electroencephalogram findings in 20 premature neonates with recurrent apnea; none had electrographic seizures that correlated with the periods of apnea. Thus, the full-term neonate, in contrast to the premature infant, who presents with recurrent episodes of apnea should be considered for continuous polygraphic monitoring with EEG.

As observed in this neonate, apneic seizures in the neonate are typically thought not to be associated with changes in heart rate. In the convulsive episodes captured by Fenichel et al.,<sup>12</sup> the percentage change in heart rate was never greater than 7%. While the majority of neonates with apneic seizures in the Watanabe study had no change in heart rate, one neonate is stated to have a substantial change in heart rate and Helmers et al. have described a newborn with apneic seizures accompanied by bradycardia.<sup>1,15</sup> Therefore, the presence of bradycardia correlated with the apneic event does not exclude the diagnosis of apneic seizures in the full-term newborn.

In conclusion, this case of a full-term neonate with seizures manifesting as apnea combined with reports of other newborns presenting with recurrent apnea underscores the importance of polygraphic monitoring with EEG in the full-term neonate



**Figure 1.** (a) Polygraphic tracing with EEG displaying approximate time of focal seizure onset in the right hemisphere marked by development of rhythmic sharply contoured alpha activity in the right centro-temporal region (outlined in boxed frame). Heart rate prior to seizure onset is 105 beats per minute. (b) Onset of 40-second apnea marked by a 75% reduction in amplitude of chest wall excursion (Resp). Seizure outlined in boxed frame. (c) Approximate resolution of apnea marked by return of amplitude of chest wall excursion to >50% of baseline. Heart rate during the last 20 seconds of apnea is 108. Seizure outlined in boxed frame. Calibration = vertical 100  $\mu$ V, horizontal 1 second.



**Figure 2.** Gradient echo sequence of cranial MRI demonstrating right temporal lobe hemorrhage.

presenting with recurrent apnea. Conversely, because apnea is such a common event in premature neonates and usually a consequence of associated comorbidities of prematurity or a function of an immature respiratory drive, routine electroencephalographic monitoring of isolated apneic spells is not indicated in this population.<sup>14</sup> Although apneic seizures are commonly associated with other seizure types (e.g., clonic, tonic, hemiconvulsive) or with subtle clinical phenomena (e.g., eye opening, staring, eye movements, mouth movements), the absence of such associated phenomena should not dissuade the clinician from pursuing polygraphic monitoring with EEG. Furthermore, the suspicion of apneic seizures should be heightened in any full-term neonate when other causes of apnea (e.g. gastroesophageal reflux, pulmonary disease, cardiac arrhythmias) have been excluded. Thus, in the full-term neonate, apneic spells

must be regarded as a potential manifestation of seizure and adequately evaluated.

### Acknowledgements

We thank Dr. Mark Quigg in helping to prepare the figures and Dr. Quigg and Dr. Robert Rust for their thoughtful comments.

### References

1. Watanabe K, Hara K, Miyazaki S, Hakamada S, Kuroyanagi M. Apneic seizures in the newborn. *Am J Dis Child* 1982;136:980–4.
2. Freeman JM. Neonatal seizures: diagnosis and management. *J Pediatr* 1970;77:701–8.
3. Donati F, Schaffler L, Vassella F. Prolonged epileptic apneas in a newborn: a case report with ictal EEG recording. *Neuropediatrics* 1995;26:223–5.
4. Monod N, Peirano P, Plouin P, Sternberg B, Bouille C. Seizure-induced apnea. *Ann NY Acad Sci* 1988;533:411–20.
5. Giroud M, Gouyon JB, Sandre D, Nivelon JL, Alison M. Les apnees epileptiques en periode neonatale. *Arch Fr Pediatr* 1983;40:719–22.
6. Lombroso CT. Neonatal polygraphy in full-term and premature infants: a review of normal and abnormal findings. *J Clin Neurophysiol* 1985; 2:105–55.
7. Ramelli GP, Donati F, Bianchetti M, Vassella F. Apnoeic attacks as an isolated manifestation of epileptic seizures in infants. *Eur J Paediatr Neurol* 1998;2:187–91.
8. Coulter DL. Partial seizures with apnea and bradycardia. *Arch Neurol* 1984;41:173–4.
9. Navelet Y, Wood C, Robieux I, Tardieu M. Seizures presenting as apnoea. *Arch Dis Child* 1989;64:357–9.
10. Freed GE, Martinez F. Atypical seizures as the cause of apnea in a 6-month-old child. *Clin Pediatr* 2001;40:283–5.
11. Nelson DA, Del W, Ray CD. Respiratory arrest from seizure discharges in the limbic system. *Arch Neurol* 1968;19:199–207.
12. Fenichel GM, Olson BJ, Fitzpatrick JE. Heart rate changes in convulsive and nonconvulsive neonatal apnea. *Ann Neurol* 1980;7:577–82.
13. Bridgers SL, Ment LR, Ebersole JS, Ehrenkranz RA. Cassette electroencephalographic recording of neonates with apneic episodes. *Pediatr Neurol* 1985;1:219–22.
14. da Silva O, Collado Guzman GM, Young GB. The value of standard electroencephalograms in the evaluation of the newborn with recurrent apneas. *J Perinatol* 1998;18:377–80.
15. Helmers SL, Weiss MJ, Holmes GL. Apneic seizures with bradycardia in a newborn. *J Epilepsy* 1991;4:173–80.