

Epilepsy Due to a Destructive Brain Lesion Caused by a Scorpion Sting

Leonardo Bonilha, MD, PhD; Fernando Cendes, MD, PhD; Enrico Ghizoni, MD; Ronan José Vieira, MD, PhD; Li Min Li, MD, PhD

Background: Symptomatic acute epileptic seizures may occur in up to 5% of individuals, especially children, with scorpion stings. The occurrence of a long-lasting brain lesion or the development of epilepsy after a scorpion sting has never been observed.

Objective: To describe the development of epilepsy secondary to an extensive hemispheric destructive brain lesion after a scorpion sting.

Patient: A 15-year-old with a moderate global cognitive impairment and a mild left hemiparesis, with seizures occurring approximately once monthly.

Results: The mother reported that the patient at the age of 4 years was stung by a brown scorpion, *Tityus serrulatus*. The patient soon developed local pain and paresthesias followed by diaphoresis and somnolence.

Approximately 24 hours after the sting, she began to convulse. She was then taken to a hospital where she achieved suboptimal seizure control, with daily tonic-clonic seizures and left hemiplegia during the following week. During our clinical investigation, her routine electroencephalogram showed the presence of interictal spikes and diffuse slowing in the right brain hemisphere. Magnetic resonance imaging showed a widespread destructive lesion of her right cerebral hemisphere affecting both the cortical and subcortical structures.

Conclusion: This is a rare illustration of the biological effects of the toxin of *T serrulatus* concerning its excitotoxicity and the potential to induce a brain lesion of an epileptogenic nature.

Arch Neurol. 2004;61:1294-1296

SCORPION STINGS ARE A FREQUENT cause of emergency medical consultations in tropical countries.¹ The symptoms presented by patients with scorpion stings are usually related to the neurotoxic effects of scorpion venom.² Scorpion stings are rarely fatal, but cardiopulmonary fatalities have been reported, especially when the patients are children.

Tityus serrulatus is a brown-colored scorpion encountered in the northwestern region of Brazil. It has a unique morphological feature, a saw-toothed formation in the third bead of its tail. This makes possible the straightforward visual identification of the species. The usual effects of *T serrulatus* stings are local pain and mild somatic sensation features, such as paresthesias and numbness. However, the worst effects of the *T serrulatus* toxins comprise somnolence, tremors, confusion, and arrhythmia. Acute symptomatic seizures have been reported to occur in up to 5% of all cases.¹

We report a case of a child who developed epilepsy because of a destructive brain lesion after a sting by *T serrulatus*. We review the biological effects of the scorpion toxin and discuss the neurotoxicity of the venom in the setting of the development of a brain lesion and recurrent nonprovoked seizures.

REPORT OF A CASE

A healthy 4-year-old child, living in the state of Bahia in the northwestern region of Brazil, was stung in her left middle finger by a brown scorpion. Her mother witnessed the event and later described the features of *T serrulatus*. The child soon developed local pain and paresthesias followed by diaphoresis and somnolence. Approximately 24 hours after the sting, she began to convulse. She was then taken to a hospital where she achieved suboptimal seizure control, with daily tonic-clonic seizures during the following week. During this

Author Affiliations: Neuroimaging Laboratory, Department of Neurology (Drs Bonilha, Cendes, Ghizoni, and Li) and Department of Emergency Medicine (Dr Vieira), State University of Campinas, Campinas, Brazil.

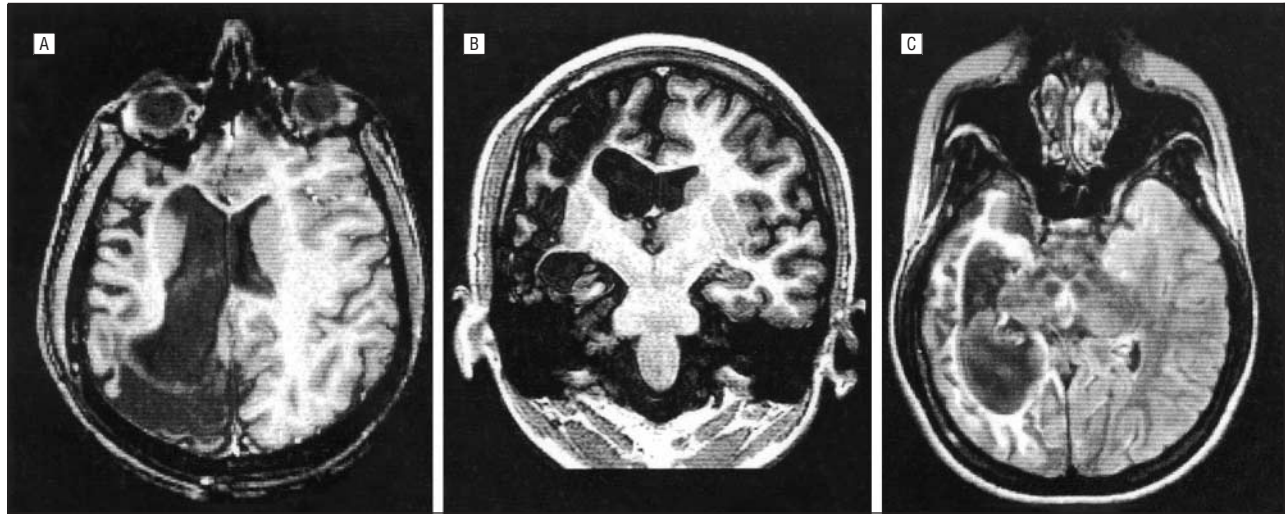


Figure. A, T1-weighted magnetic resonance imaging of the axial plane showing diffuse right cortical and subcortical destruction. B, T1-weighted magnetic resonance imaging of the coronal plane showing a cortical and subcortical atrophy of the right frontal and temporal lobes. C, Fluid-attenuated inversion recovery sequence magnetic resonance imaging of the axial plane showing *ex vacuo* lateral ventricle enlargement and widespread increased signal intensity in the subcortical portion of the right hemisphere, indicating gliosis.

period, and between the seizures, she stayed alert and conscious, with left hemiplegia. When the seizures began to abate, 1 week after the sting, she was discharged home. She continued to have almost daily tonic-clonic seizures for 2 years after the hospitalization, despite antiepileptic drugs.

She is now 15 years old, and her mother states that after the accident the patient had learning difficulties and was not able to attend elementary school. She currently has a moderate global cognitive impairment and a mild left hemiparesis, and her seizures occur approximately once monthly.

She underwent neurophysiologic and image investigation. Routine electroencephalogram showed the presence of interictal spikes and diffuse slowing in the right brain hemisphere. Magnetic resonance imaging showed a widespread destructive lesion of her right cerebral hemisphere affecting both the cortical and subcortical structures (**Figure**).

COMMENT

Scorpion venom is formed by mucopolysaccharides, hyaluronidase, phospholipase, serotonin, histamine, and protease inhibitors. The clinical manifestations of scorpion venom intoxication exclusively result from the action of α - and β -toxins.³ The α -toxin is present in the venom of *Androctonus australis Hector*, *Androctonus mauretanicus mauretanicus*, *Buthus eupeus*, *Buthus occitanus tunetanus*, *Leiurus quinquestriatus*, and *T serrulatus*, whereas the β -toxin can be found in the venom of *Centruroides sculpturatus*, *Centruroides suffusus suffusus*, and *T serrulatus*.⁴ Both α - and β -toxins are 7-kDa molecular weight polypeptides of 64 amino acids and 4 intramolecular disulfide bridges.⁵

The scorpion toxins exert their *in vivo* effects by the disturbance of ion transportation through the neuronal cell membranes both presynaptic and postsynaptic.⁶ The α -neurotoxin binds to site 3 of the sodium channel and

slows down or blocks the channel inactivation and stabilizes the channel in its open state.³ Conversely, the β -neurotoxin binds to site 4 of the sodium channel and does not change the channel inactivation, but it shifts the channel voltage dependence in the positive direction.⁷

The toxin purified from the South American scorpion *T serrulatus* shifts the voltage-dependent activation of the sodium channel, leading to repetitive firing. Actually, the so-called Tityus toxin is a mixture of a minor fraction and a major fraction named γ -toxin. The γ -toxin binds close to binding site 4 of the Na^+ channel and blocks the channel. The same effect of delay of inactivation of the Na^+ channel is produced by the major component of the toxin. There are additional effects of the Tityus venom concerning blockage of delayed rectifier K^+ channel, binding to the Ca^{+2} -activated K^+ channel of high conductance, and binding of small conductance Ca^{+2} channels.⁸ The biological effect of these actions, however, is yet to be clarified.

The clinical effects of scorpion venom intoxication consist of local reactions such as pain, edema, paresthesia, numbness, and somnolence. These reactions are considered to be a consequence of neurotransmitter release. The systemic symptomatology is mainly due to the catecholaminergic release, leading to tachycardia, increased blood pressure, restlessness, muscle cramps, and fasciculation. Serious and fatal cases, especially involving children, are the consequence of secondary complications such as shock and pulmonary edema, convulsions, brain edema, muscular paralysis, and respiratory failure.⁹

The present case may be a rare illustration of a brain lesion induced by the excitotoxic effects of the scorpion toxin. The persistent hyperactivation state generated by the scorpion toxin is possibly the cause of the widespread functional and structural lesion with ischemic features. Interestingly, the lateralization of the seizures, and the right hemispheric brain destruction, followed a similar pattern of patients with HHE syndrome (hemicon-

vulsion, hemiplegia, and epilepsy).¹⁰ Rasmussen syndrome is a possible differential diagnosis; however, we have not witnessed continuous epileptic activity in the patient's electrophysiological studies or evidence of progression in her disease.

The recurrent nonprovoked seizures in this patient suggest the development of a stable epileptogenic region in the area that was continuously activated by the scorpion toxin. Our case report suggests biological effects of the toxin of *T serrulatus* concerning its excitotoxicity and the potential to induce a brain lesion of an epileptogenic nature. This may guide further experimental applications of scorpion toxins and further assistance of patients stung by scorpions.

Accepted for Publication: November 24, 2003.

Correspondence: Li Min Li, MD, PhD, Department of Neurology, Faculty of Medicine, Campinas State University, 13083-970, Campinas, SP, Brazil (limin@fcm.unicamp.br).

Author Contributions: *Study concept and design:* Bonilha, Cendes, Ghizoni, and Li. *Acquisition of data:* Bonilha, Vieira, and Li. *Analysis and interpretation of data:* Bonilha, Cendes, Ghizoni, Vieira, and Li. *Drafting of the manuscript:* Bonilha and Li. *Critical revision of the manuscript for important intellectual content:* Bonilha, Cendes, Ghizoni, Vieira, and Li. *Statistical expertise:* Bonilha, Cendes, and Ghizoni. *Obtained funding:* Cendes, Ghizoni, Vieira, and Li. *Admin-*

istrative, technical, and material support: Cendes, Vieira, and Li. *Study supervision:* Ghizoni, Vieira, and Li.

Acknowledgment: We thank the patient for her kind cooperation.

REFERENCES

1. Freire-Maia L, Campos JA, Amaral CF. Approaches to the treatment of scorpion envenoming. *Toxicon*. 1994;32:1009-1014.
2. Arantes EC, Sampaio SV, Vieira CA, Giglio JR. What is tityustoxin? *Toxicon*. 1992; 30:786-789.
3. Ludolph AC, Spencer PS. Scorpion toxins (alpha and beta). In: Spencer PS, Schaumburg HH, eds. *Experimental and Clinical Neurotoxicity*. Oxford, England: Oxford University Press; 2000.
4. Martin-Eauclaire MF, Couraud F. Scorpion neurotoxins: effects and mechanisms. In: Chang LW, Dyer RS, eds. *Handbook of Neurotoxicology*. New York, NY: Marcel Dekker; 1994.
5. Zlotkin E, Miranda F, Rochat H. Chemistry and pharmacology of Buthinae venoms. In: Buttini S, ed. *Arthropod Venoms*. Berlin, Germany: Springer-Verlag; 1978.
6. Moss J, Colburn RW, Kopin IJ. Scorpion toxin induced catecholamine release from synaptosomes. *J Neurochem*. 1974;22:217-221.
7. Meves H, Simars JM, Watt DD. Interactions of scorpion toxins with the sodium channel. *Ann N Y Acad Sci*. 1986;479:113-132.
8. Oliveira MJ, Fontana MD, Giglio JR, Sampaio SV, Corrado AP, Prado WA. Effects of the venom of the Brazilian scorpion *Tityus serrulatus* and two of its fractions on the isolated diaphragm of the rat. *Gen Pharmacol*. 1989;20:205-210.
9. Champetier des Ribes G. Envenimation scorpionique chez l'enfant. *Ann Pediatr*. 1985;3:23-99.
10. Teixeira RA, Leone AA, Honorato DC, Damasceno BP, Guerreiro CA, Cendes F. Congenital destructive hemispheric lesions and epilepsy: clinical features and relevance of associated hippocampal atrophy. *Arq Neuropsiquiatr*. 2000;58: 990-1001.