

Coenzyme Q 10 Improves Lactic Acidosis, Strokeliike Episodes, and Epilepsy in a Patient With MELAS (Mitochondrial Myopathy, Encephalopathy, Lactic Acidosis, and Strokeliike episodes)

Angel Berbel-Garcia, PhD,* Jose Ramon Barbera-Farre, PhD,† Jesús Porta Etessam, PhD,‡ Antonio Martínez Salio, PhD,‡ Ana Cabello, MD,§ Eduardo Gutierrez-Rivas, MD,‡ and Yolanda Campos, MD¶

Abstract: Mitochondrial encephalomyopathies encompass a group of disorders that have impaired oxidative metabolism in skeletal muscles and central nervous system. Many compounds have been used in clinical trials on mitochondrial diseases, but the outcomes have been variable. It remains controversial whether treatment of mitochondrial diseases with coenzyme Q 10 is effective. This paper describes a case of mitochondrial myopathy, encephalopathy, lactic acidosis, strokelike episodes, and exercise intolerance successfully treated with coenzyme Q 10. Efficacy of this therapy in this patient is correlated to control of lactic acidosis and serum creatine kinase levels. Disappointingly, larger studies with coenzyme Q 10 failed to demonstrate a clear beneficial effect on the entire study population with regard to clinical improvement or several parameters of the oxidative metabolism. They suggest that the use of coenzyme Q in treatment of mitochondrial diseases should be confined to protocols. There is a confounding variation in phenotype and genotype, and the natural history of the disorders in individual patients is not accurately predictable. The unpredictable *a priori* efficacy of therapy suggests that a long-term trial of oral coenzyme Q may be warranted.

Key Words: coenzyme Q 10, efficacy, mitochondrial encephalomyopathies, MELAS (mitochondrial myopathy, encephalopathy, lactic acidosis, and strokelike episodes)

(*Clin Neuropharmacol* 2004;27:187–191)

Mitochondrial encephalomyopathies encompass a group of disorders that have impaired oxidative metabolism in skeletal muscles and central nervous system.¹ These condi-

tions include several syndromes such as myoclonus epilepsy with ragged-red fibers (MERFF); mitochondrial myopathy, encephalopathy, lactic acidosis, and strokelike episodes (MELAS); Kearns-Sayre syndrome; and chronic progressive external ophthalmoplegia (CPEO) syndromes.^{2–4} Many compounds have been used in clinical trials on mitochondrial diseases in an attempt to enhance respiratory chain function or to reduce the concentration of the toxic products of the disturbed metabolism, but the outcomes have been variable. Ubiquinone (Q 10) supplementation has been reported to have clinical or biochemical benefit,^{5–22} although some studies have failed to show any effect.^{23–25} Therefore, it remains controversial whether treatment of mitochondrial diseases with Q 10 is effective. We describe a case of MELAS with neurologic symptoms and exercise intolerance successfully treated with coenzyme Q 10 (CoQ).

CASE REPORT

A 22-year-old woman was examined after intermittent episodes of fatigue and dyspnea associated with mild exercise that finally became constant (grade V of Subjective Scoring of the Fatigability in Activities of Daily Living; SSFADL).¹⁰ Laboratory studies revealed metabolic acidosis with marked hyperlactatemia (5.1 mM; normal <2.0 mM) and elevated serum creatine kinase (CK) levels (800 U/L; normal <150 U/L). Clinical examination failed to reveal cardiopathy, hepatopathy, or central nervous system involvement. She did not have short stature, hearing impairment, or restriction of the extraocular movements. Her eldest brother had had dyspnea and fatigability episodes and died at 19 years; he was not studied. The rest of the family was clinically normal. Muscle biopsy revealed abundant ragged-red fibers and combined defects of the mitochondrial complexes. Genetic analysis showed the presence of a T3258C transition mutation within the tRNA^{Leu(UUR)} gene. The mutation was very abundant in muscle (96%) and less abundant in blood (57%). The patient's

From the Departments of *Neurology and †Internal Medicine, Hospital Mancha Centro, Alcazar de San Juan, Ciudad Real; ‡Department of Neurology, §Department of Pathology, and ¶Investigation Centre, Hospital Doce de Octubre, Madrid, Spain.

Reprints: Angel Berbel Garcia, PhD, Department of Neurology, Hospital Mancha Centro, Avenida Constitucion, 3 Alcazar de San Juan, Ciudad Real 13600, Spain (e-mail: aberbel@yahoo.com).

Copyright © 2004 by Lippincott Williams & Wilkins

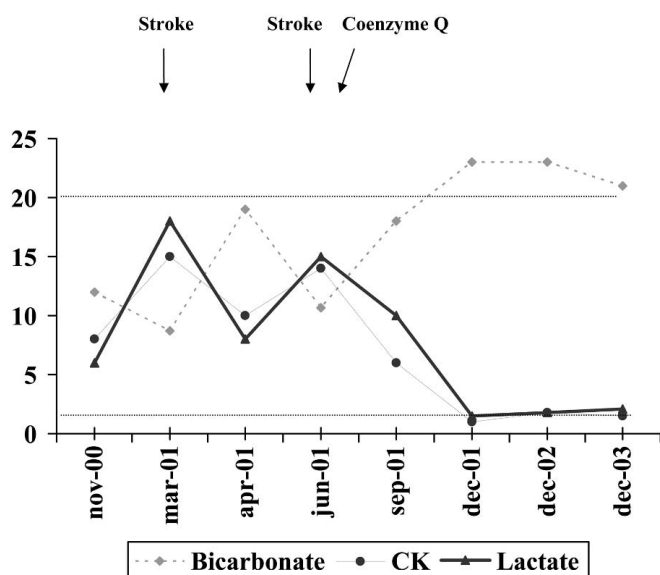


FIGURE 1. Clinical and metabolic changes. Basal serum levels of lactate (mM), CK (U/L × 100) and bicarbonate (mM). Serum concentrations of CK and lactate increased and bicarbonate decreased during strokelike episodes (March 2001 and June 2001). Once CoQ therapy was started (July 2001), serum concentrations of CK, lactate, and bicarbonate improved (sustained for 30 months, December 2003). Horizontal bars depict normal serum values of bicarbonate (superior), CK, and lactate (inferior).

mother and 2 asymptomatic brothers had the mutation in blood but the mutation was less abundant than in the patient (19, 30, and 48%, respectively); muscle biopsy was not performed. For more details of histochemistry and molecular genetic studies see Campos et al.²⁶ A combined therapy of bicarbonate at a dosage of 2 gr/d (Bicarbonato; Novartis, Barcelona, Spain), carnitine 3 gr/d (Carnicor; Sigma Tau, Alcalá de Henares, Spain), and multiple vitamins (vitamin B₁ 45 mg/d, vitamin B₂ 45 mg/d, nicotinamide 150 mg/d, pyridoxine 30 mg/d, biotin

450 µg/d, cyanocobalamin 30 µg/d, ascorbic acid 600 mg/d; Becozyme C Forte; Roche Farma, Madrid, Spain) was begun. Despite this therapy, mild exercise intolerance, lactic acidosis, and elevated serum creatine kinase (CK) levels remained. Six months later the patient presented with headache, right temporal hemianopsia, and generalized tonic-clonic seizures that disappeared in a week. Lamotrigine therapy, 100 mg BID (Lamictal, GSK, Tres Cantos, Spain) was started. Three months later, she had another transient episode of headache followed by left temporal hemianopsia. Magnetic resonance of the brain revealed a reversible strokelike lesion in the right occipital cortex not corresponding to the territory of larger arteries. Both episodes were related to an increase in lactic acidosis and CK levels (Fig. 1).

RESULTS

Finally therapy with CoQ 300 mg/d was started (Decorenone 50, Italfarmaco SPA, Milan, Italy). Progressive improvement of exercise intolerance (grade II on SSFADL),¹⁰ metabolic acidosis, and serum CK levels was documented. New strokelike episodes or seizures did not appear. The patient has been asymptomatic for 30 months. For more details in the evolution of clinical and metabolic findings, see Figure 1 and Table 1.

DISCUSSION

Coenzyme Q 10 plays a pivotal role in the mitochondrial respiratory chain. It distributes the electrons between the various dehydrogenases and the cytochrome segments of the respiratory chain. Based on our present understanding of the role of quinones in the mitochondria, we should distinguish attempts aiming at restoring electron flow, providing electrons to the chain, or increasing mitochondrial antioxidant defenses.

Therapeutic studies of mitochondrial diseases are difficult to perform. It is hard to find a sufficient number of patients to give adequate statistical power to a study. Although appropriate treatment has not been established, therapeutic trials

TABLE 1. Metabolic Changes: Basal Serum Levels of Lactate (mM), Creatine Kinase (CK), pH, and Bicarbonate (mM)

	11-00	03-01	04-01	06-01	09-01	12-01	12-02	12-03
pH	7.23	7.16	7.27	7.23	7.31	7.39	7.42	7.45
Bicarbonate	12	8.7	19	10	18	23	23	21
CK	800	1500	1000	1400	600	100	180	150
Lactate	6	18	8	15	10	1.5	1.8	2.1
Symptoms	D/EI	Stroke	D/EI	Stroke	EI	Oligo	Oligo	Oligo

Periods without neurologic symptoms previous to coenzyme Q administration show intermediate metabolic alterations (from November 2000 to March 2001 and from April 2001 to June 2001). Serum concentrations of CK and lactate increased and pH and bicarbonate decreased during strokelike episodes (March 2001 and June 2001). Once coenzyme Q therapy was started (July 2001), serum concentrations of CK, lactate, pH, and bicarbonate improved (sustained for 30 months, December 2003).

D; dyspnea; EI, exercise intolerance; oligo, oligosymptomatic.

TABLE 2. Trials in Coenzyme Q 10 Therapy for Mitochondrial Diseases

Trial	Patients	Dosage CoQ/ Other Drugs	Time	Biochemical Efficacy	Clinical Improvement
Remes et al ⁵	Encephalopathy 7 patients (A3243G)	3 mg/kg/d + nicotinamide 50 mg/kg/d	6 mo	Serum L and P improvement	No improvement
Barbiroli et al ⁶	4 CPEO 2 LON (11778)	150 mg/d	6 mo	Muscle, brain MR-S improvement	No improvement
Shinkai et al ⁷	1 MELAS (A3243G)	70 mg/d		CSF L and P decreased	Psychiatric signs
Abe et al ⁸	2 MELAS (A3243G)	200 mg/d		Noninvasive oximetry improvement	
Goda et al ⁹	1 MELAS	300 mg/d	1 y	Serum L and P improvement	Transient blindness disappeared
Chen et al ¹⁰	4 MERFF (8344) 3 MELAS (3243) 1 CPEO	160 mg/d	3 mo	Exercise lactate test improved	Weakness
Abe et al ¹¹	1 MELAS	High doses		CSF L and P decreased	Weakness, seizures
Yamamoto et al ¹²	1 MELAS	90 mg/d	1 y		Weakness
Berio and Piazzzi ¹³	1 Kearns-Sayre	30 mg/d, controlled carbohydrate intake	6 mo	Serum L improved	Ophthalmoparesis
Calatayud et al ¹⁴	1 Kearns-Sayre	150	3 y	Serum L and P and VEP improved	Ophthalmoparesis
Ihara et al ¹⁵	2 MELAS	210 mg/d and idebenone 90 mg/d	3 mo	EEG Serum L/P improved	Weakness, WAIS
Desnuelle et al ¹⁶	2 Kearns-Sayre	150 mg/d	2 y	Serum L/P improved	Ophthalmoparesis
Bresolin et al ¹⁷	7 CPEO	120 mg/d	1 y	Serum L and P	Weakness
Ogasahara et al ¹⁸	5 Kearns-Sayre	120–50 mg/d	3–4 mo	CSF L and P, ECG defects, improved	Weakness, ophthalmoparesis
Ogasahara et al ¹⁹	1 Kearns-Sayre	120 mg/d	3 mo	Serum L/P, conduction ECG bocks improved	Ophthalmoparesis
Nishikawa et al ²⁰	1 COX deficiency	High doses	2 y	MR-S, SEP improved	No improvement
Maldergem et al ²¹	2 Leigh disease	300 mg/d			Weakness, growth
Chan et al ²²	9 Kearns-Sayre	150 mg/d	6 mo	Basal and alter exercise Serum L/P improved	No improvement
Matthews et al ²³	4 MERFF 7 Myopathy	300 mg/d and multiple vitamins	2 mo	L and P, MR-S, exercise testing, unchanged	No improvement
Bresolin et al ²⁴	44 patients	2 mg/kg/d	6 mo	25% postexercise lactate levels decreased	No improvement
Zierz et al ²⁵	2 CPEO		1 y	Serum L, mitochondrial activity, unchanged	

Reports in coenzyme Q 10 therapy and its clinical or biochemical efficacy.

In parentheses: mitochondrial DNA mutations.

COX, cytochrome-c-oxidase; CPEO, chronic progressive external ophthalmoplegia; CSF, cerebrospinal fluid; ECG, electrocardiogram; EEG, electroencephalogram; L, lactate; LON, Leber optic neuropathy; MELAS, mitochondrial myopathy, encephalopathy, lactic acidosis, stroke; MERFF, myoclonus, epilepsy, red-ragged fibers; MR-S, magnetic resonance-spectroscopy; P, pyruvate; SEP, somatosensory evoked potentials; VEP, visual evoked potentials; WAIS, Wechsler Adult Intelligence Scale.

with Q 10 have been reported to be beneficial clinically or biochemically in several studies.^{5–22} Conversely some studies have failed to show any effect.^{23–25} Moreover there is a confounding variation in phenotype and genotype, and the natural history of the disorders in individual patients is not accurately

predictable. A direct comparison of the effect of CoQ in these studies is difficult because of different methods with different metabolic parameters to evaluate response; the lack of quantitative assessment or scores; the inclusion of different syndromes with variable genetic backgrounds; the variable sever-

ity of symptoms; time of trial; and dosage of CoQ and combination of several drugs (Table 2).

Disappointingly, larger studies with CoQ failed to demonstrate a clear beneficial effect on the entire study population with regard to clinical improvement or several parameters of the oxidative metabolism.^{23–25} Authors postulated that variability in the natural history of the disorders was the responsible for the initial lactate changes and that treatment with CoQ did not actually improve oxidative functions.²³ They concluded that the use of CoQ in treatment of mitochondrial diseases should be confined to protocols designed to assess possible benefits.²³

Conversely, others studies suggested that a trial of oral CoQ 10 may be warranted but should last much longer than 6 months and test higher doses.^{5,9,10,11,17} Except for those with CPEO, most of these patients have showed only mild, short-term subjective clinical improvement. Moreover, the principal endpoint was biochemical or neurophysiologic efficacy.

Our patient showed a dramatic improvement of exercise intolerance and neurologic symptoms once CoQ therapy was started. Clinical and biochemical effects last for 30 months. Several hypotheses have been postulated to explain the etiology of the strokelike episodes and an individual cellular dysfunction related to the abnormality in the respiratory chain of the mitochondria seems to be the most plausible.¹⁵

Fluctuations of neurologic symptoms were correlated to increase of systemic lactic acidosis; strokelike episodes and seizures disappeared with control of lactic acidosis. Unfortunately cerebrospinal fluid, neurophysiologic, or magnetic resonance spectroscopy findings are not available to prove that neurologic symptoms could be attributed to systemic metabolic changes and are not due to changes in brain mitochondrial metabolism.

Exogenous CoQ is known not to be able to pass the blood-brain barrier (BBB),¹⁵ but some trials have proved clinical, biochemical, or physiological efficacy in the central nervous system.^{5,11,12,18,20} A broken BBB¹¹ has been proposed to explain a relatively freely pass into the brain tissue. In cases of nervous central system dysfunction, concomitant therapy with idebenone is recommended.^{15,27,28} Efficacy of this therapy in our patient could be attributed to control of lactic acidosis, because out of the strokelike episodes a broken BBB is not demonstrable. The ultimate mechanism of CoQ in our patient is unknown.

In conclusion, appropriate treatment of mitochondrial encephalomyopathies has not been established. Larger trials conclude that the use of CoQ in treatment of mitochondrial diseases should be confined to protocols. Nevertheless our patient shows a long-term efficacy of therapy with CoQ. Although CoQ is not able to pass the BBB, systemic effects were enough to control neurologic symptoms. As shown in our patient's family, mitochondrial encephalomyopathies are complicated by the variable severity of symptoms depending on

proportion of mutations in different tissues, suggesting a steep threshold for phenotypic expression. The degree of heteroplasmy could be related to the response to the treatment. The unpredictable *a priori* efficacy of therapy suggests that a long-term trial of oral CoQ may be warranted.

REFERENCES

1. Di Mauro S, Bonilla E, Zeviani M, et al. Mitochondrial myopathies. *Ann Neurol*. 1985;17:521–538.
2. Fukuhara N, Tokiguchi S, Shirakawa S, et al. Myoclonus epilepsy associated with red-ragged fibers (mitochondrial abnormalities): disease or syndrome? Light and electron-microscopic studies of two cases and review of the literature. *J Neurol Sci*. 1980;47:117–133.
3. Pavlakis SG, Phillips PC, Di Mauro S, et al. Mitochondrial myopathy, encephalopathy, lactic acidosis and stroke-like episodes: a distinctive clinical syndrome associated with red-ragged fibers. *Ann Neurol*. 1984; 481–488.
4. Hyman BK, Patten BM, Dosdon RF, et al. Mitochondrial abnormalities in progressive external ophthalmoplegia. *Am J Ophthalmol*. 1977;83:362–371.
5. Remes AM, Liimatta EV, Winqvist S, et al. Ubiquinone and nicotinamide treatment of patients with the 3243A->G mtDNA mutation. *Neurology*. 2002;59:1275–1277.
6. Barbiroli B, Frassinetti C, Martinelli P, et al. Q10 improves mitochondrial respiration in patients with mitochondrial cytopathies: an in vivo study on brain and skeletal muscle by phosphorous magnetic resonance spectroscopy. *Cell Mol Biol(Noisy-le-grand)* 1997;43:741–749.
7. Shinkai T, Nakashima M, Ohmori O, et al. Coenzyme Q10 improves psychiatric symptoms in adult-onset mitochondrial myopathy, encephalopathy, lactic acidosis and stroke-like episodes: a case report. *Aust N Z J Psychiatry*. 2000;34:1034–1035.
8. Abe K, Matsuo Y, Kadekawa J, et al. Effect of coenzyme Q10 in patients with mitochondrial, myopathy, encephalopathy, lactic acidosis, and stroke-like episodes (MELAS): evaluation by noninvasive tissue oximetry. *J Neurol Sci*. 1999;162:65–68.
9. Goda S, Hamada T, Ishimoto S, et al. Clinical improvement after administration of coenzyme Q10 in a patient with mitochondrial encephalomyopathy. *J Neurol*. 1987;234:62–63.
10. Chen RS, Huang CC, Chu NS, et al. Coenzyme Q10 treatment in mitochondrial encephalomyopathy: short-term, double-blind, crossover study. *Eur Neurol*. 1997;37:212–218.
11. Abe K, Fujimura H, Nishikawa Y, et al. Marked reduction in CSF lactate and pyruvate levels after CoQ therapy in a patient with mitochondrial myopathy, encephalopathy, lactic acidosis and stroke-like episodes (MELAS). *Acta Neurol Scand*. 1991;83:356–359.
12. Yamamoto M, Sato T, Anno M, et al. Mitochondrial myopathy, encephalopathy, lactic acidosis, and strokelike episodes with recurrent abdominal symptoms and coenzyme Q10 administration. *J Neurol Neurosurg Psychiatry*. 1987;50:1475–1481.
13. Berio A, Piazzini A. Improvement of Kearns-Sayre syndrome with controlled carbohydrate intake and coenzyme Q10 therapy. *Ophthalmologica*. 1994;208:342–343.
14. Calatayud MT, Diaz-Castroverde AG, Solar M, et al. Treatment with ubiquinone in Kearns-Sayre syndrome: improvement in ocular motility and visual evoked potentials. *Neurologia*. 1992;7:266–269.
15. Ihara Y, Namba R, Kuroda S, et al. Mitochondrial encephalomyopathy (MELAS): pathological study and successful therapy with coenzyme Q10 and idebenone. *J Neurol Sci*. 1989;90:263–271.
16. Desnuelle C, Pellissier JF, Serratrice G, et al. Kearns-Sayre syndrome: mitochondrial encephalomyopathy caused by deficiency of the respiratory chain. *Rev Neurol (Paris)*. 1989;145:842–850.
17. Bresolin N, Bet L, Binda A, et al. Clinical and biochemical correlations in mitochondrial myopathy treated with coenzyme Q10. *Neurology*. 1988; 38:892–899.
18. Ogasahara S, Nishikawa Y, Yorifuji S, et al. Treatment of Kearns-Sayre syndrome with coenzyme Q10. *Neurology*. 1986;36:45–53.
19. Ogasahara S, Yorifuji S, Nishikawa Y, et al. Improvement of abnormal

- pyruvate metabolism and cardiac conduction defect with coenzyme Q10 in Kearns-Sayre syndrome. *Neurology*. 1985;35:372-377.
20. Nishikawa Y, Takahashi M, Yorifuji S, et al. Long-term coenzyme Q10 therapy for a mitochondrial encephalomyopathy with cytochrome c oxidase deficiency: a 3D NMR study. *Neurology*. 1989;39:399-403.
 21. Maldergem LV, Trijbels F, Di Mauro S, et al. Coenzyme Q-responsive Leigh's encephalopathy in two sisters. *Ann Neurol*. 2002;52:750-754.
 22. Chan A, Reichmann H, Kögel A, et al. Metabolic changes in patients with mitochondrial myopathies and effects of coenzyme Q-10 Therapy. *J Neurol*. 1998;245:681-685.
 23. Matthews PM, Ford B, Dandurand RJ, et al. Coenzyme Q10 with multiple vitamins is generally ineffective in treatment of mitochondrial disease. *Neurology*. 1993;43:884-890.
 24. Bresolin N, Doriguzzi C, Ponzetto C. Ubidecarenone in the treatment of mitochondrial myopathies: a multi-center double-blind trial. *J Neurol Sci*. 1990;100:77-78.
 25. Zierz S, von Wersebe O, Bleistein J, et al. Exogenous coenzyme Q fails to increase CoQ in skeletal muscle of two patients with mitochondrial cytopathies. *J Neurol Sci*. 1990;95:283-290.
 26. Campos Y, Garcia A, del Hoyo P, et al. Two pathogenic mutations in the mitochondrial DNA tRNA Leu (UUR) gene (T3258C and A3280G) resulting in variable clinical phenotypes. *Neuromuscul Disord*. 2003;13:416-420.
 27. Geromel V, Darin N, Chretien D, et al. Coenzyme Q10 and idebenone in the therapy of respiratory chain diseases: rationale and comparative benefits. *Mol Genet Metab*. 2002;77:21-30.
 28. Castro-Gago M, Novo-Rodríguez MI, Pintosmartínez E, et al. Mitochondrial myopathies. *Rev Neurol*. 2000;31:263-282.