

Lateral Sinus Thrombosis Associated With Zoster Sine Herpete

James Chan, MD, Richard T. Bergstrom, MD, Donald C. Lanza, MD, and John G. Oas, MD

Herpes zoster results from reactivation of the varicella zoster virus (VZV). Zoster sine herpete (ZSH) is an uncommon manifestation of VZV infection and presents with similar symptoms but without the vesicular rash. We describe an unusual case of lateral sinus thrombosis (LST) that developed during the clinical course of ZSH in the C2 distribution. A 55-year-old woman presented with a 3-day history of left temporal and postauricular pain, nausea, vomiting, and mild photophobia. She denied otalgia, otorrhea, and hearing loss. Examination revealed hyperesthesia in the left C2 nerve root distribution without evidence of herpetic rash. A computed tomography scan showed minimal fluid in the left mastoid cavity (not mastoiditis) and thrombus within the left lateral and sigmoid dural sinus. Magnetic resonance imaging and magnetic resonance angiogram confirmed these findings. Laboratory studies revealed elevated neurotrophic immunoglobulin G levels to VZV. Hypercoagulable studies were normal. She was subsequently treated with Neurontin, acyclovir, and anticoagulation. Her symptoms improved, and she was discharged 3 days later. LST is generally a complication of middle ear infection. Nonseptic LST, however, may result from dehydration, oral contraceptive use, coagulopathy, or thyroid disease. This unusual case raises the suspicion that thrombosis resulted from VZV associated thrombophlebitis in the ipsilateral cerebral venous sinuses along the second cervical nerve root distribution. A high index of suspicion is necessary in such cases so that a different treatment course can be identified and antiviral medication initiated promptly.

(Am J Otolaryngol 2004;25:357-360. © 2004 Elsevier Inc. All rights reserved.)

Zoster sine herpete (ZSH) is a recognized clinical variant of herpes zoster and presents with painful neuralgia, without vesicular lesions, in a dermatomal distribution. Herpes zoster infections involving the cerebral vasculature have been described and confirmed by postmortem examinations.¹ Anatomic and histologic studies show neuronal innervation of cerebral vasculature by cervical nerves.^{2,3} Furthermore, pontine infarction as a result of reactivation of the zoster virus within brainstem vasculature has been described.^{4,5} Our aim is to report an unusual case of lateral sinus thrombosis associated with cervical

ZSH and provide a pertinent review of the literature to support this diagnosis. Recognizing this rare entity can lead to initiation of appropriate therapy in a timely manner.

CASE REPORT

A 55-year-old woman presented with a 3-day history of left temporal and postauricular pain, nausea, vomiting, and mild photophobia. She denied otalgia, otorrhea, and hearing loss. Examination revealed hyperesthesia in the left C2 nerve root distribution without evidence of herpetic rash. A computed tomography (CT) scan showed minimal fluid in the left mastoid cavity (not mastoiditis) and thrombus within the left lateral and sigmoid dural sinus (Figs 1 and 2A and B). Magnetic resonance imaging (MRI) and magnetic resonance angiogram confirmed these findings (Figs 3A and B). Laboratory studies revealed elevated neurotrophic immunoglobulin G levels to varicella zoster virus (VZV). Hypercoagulable studies were normal. She was subsequently treated with Neurontin,

From the Department of Otolaryngology and Communicative Disorders, The Cleveland Clinic Foundation, Cleveland, OH.

Presented at the American Academy of Otolaryngology-Head and Neck Surgery Annual Meeting, September 21-24, 2003, Orlando, FL.

Address correspondence to: John G. Oas, MD, The Cleveland Clinic Foundation, A71, 9500 Euclid Avenue, Cleveland, OH 44195. E-mail: oasj@ccf.org.

© 2004 Elsevier Inc. All rights reserved.

0196-0709/\$ - see front matter

doi:10.1016/j.amjoto.2004.03.007

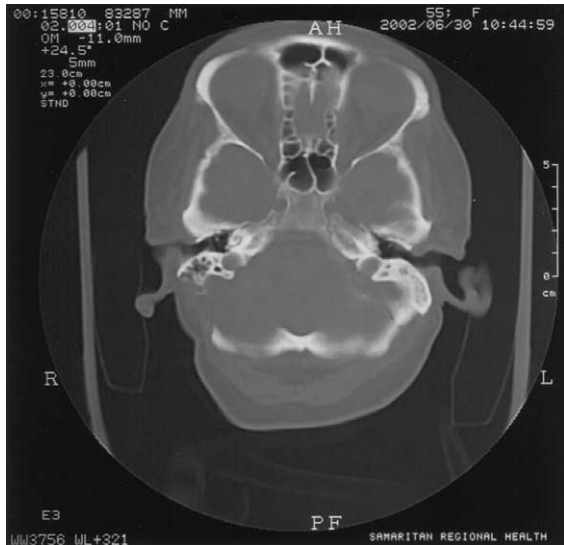

Fig 1. Axial CT scan with contrast showing minimal fluid in the left mastoid cavity.

acyclovir, and anticoagulation. Her symptoms improved, and she was discharged 3 days later.

DISCUSSION

The present case is unusual in that the patient developed idiopathic lateral sinus thrombosis with unilateral C2 dermatomal hypesthesia and dyesthesia ipsilateral to the lateral sinus thrombosis. However, cutaneous herpetic lesions were absent. Serologic studies confirmed reactivation of VZV. After thorough evaluation for other causes, the constellation of findings suggests that the lateral sinus thrombosis is associated with ZSH.

ZSH

Herpes zoster (shingles) is characterized by cutaneous or mucosal herpetic lesions distributed in a unilateral segmental dermatome. Painful neuralgia is typically present. It is thought to be the result of reactivation of VZV within the dorsal root ganglia. A clinical variant is ZSH, which is also caused by reactivation of VZV leading to radicular pain but without the accompanying rash. A number of clinical studies support the existence of this syndrome.⁶⁻⁸

Cerebral Vascular Infarction Associated With Herpes Zoster

Several authors have suggested that cervical herpes zoster can lead to cerebral vascular infarction. Patrick et al⁴ reported a patient with cervical herpes zoster infection followed by pontine infarction. They proposed a mechanism whereby varicella zoster was reactivated within the dorsal root ganglia along cervical nerve pathways to the vertebrobasilar system, which led to angiitis and infarction

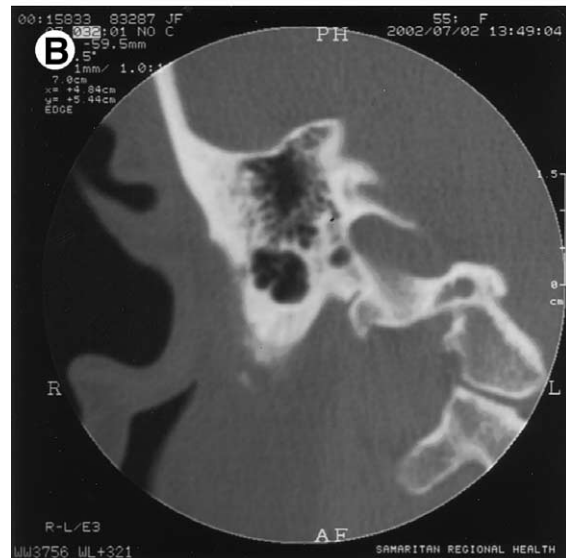
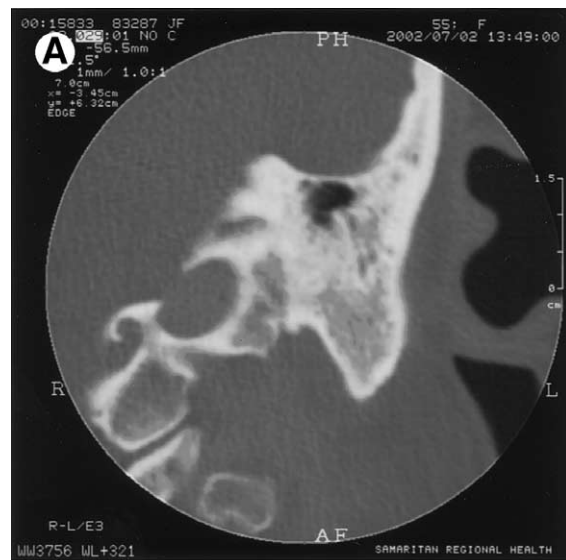
Fig 2. Coronal CT scan showing minimal mucosal thickening and opacification of air cells in the (A) left mastoid as compared with the (B) right.

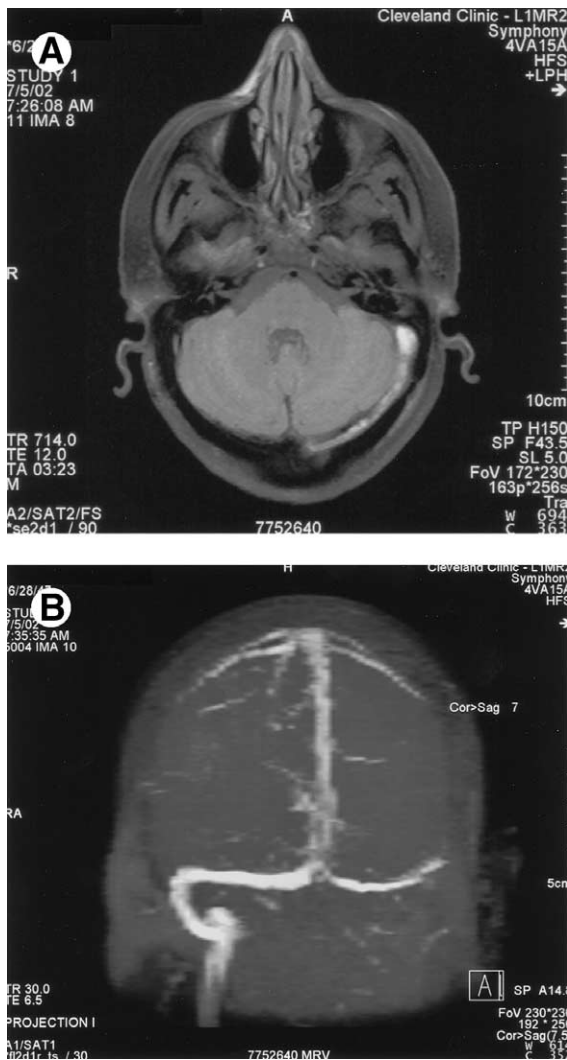


Fig 3. (A) Coronal MRI with and without gadolinium and (B) MRA showing occlusion of the lateral sinus with thrombus formation.

of the posterior circulation. Willeit and Schmutzard⁵ described a patient with cervical herpes zoster and delayed brainstem infarction and suggested that reactivation of VZV induced cerebral arteritis.⁵

Pathological Evidence of Herpes Zoster

Pathological studies have shown large-vessel vasculopathy after herpes zoster infection. Eidelberg et al¹ presented the postmortem examination and brain biopsy of 2 patients with thrombotic occlusions after segmental herpes zoster infection. Varicella zoster viral antigens were also detected by immunoperoxidase

staining within the media of the cerebral arteries. Their results provide supporting evidence that the vasculopathy after shingles results from varicella zoster reactivation within the cerebral artery leading to in situ thrombosis.¹

Anatomic Support of Neural Innervation of Dural Sinuses

Detailed immunohistochemical studies provide evidence that dural sinuses are innervated by nerve fibers. Barrett et al² used a highly specific fluorescence microscopic technique to show the localization of neurotransmitters in nerve cell bodies and their terminals within cerebral blood vessels. Investigators have also shown that the upper cervical nerve roots invest the vertebrobasilar system. Anatomic and histologic studies in cats, by Saito and Moskowitz,³ show that cervical nerves innervate the vasculature of the circle of Willis. It is therefore possible that the relationship between the cutaneous symptoms and the dural sinus thromboses is a result of retrograde viral migration from the dorsal root ganglia via cervical nerve roots.

Lateral Sinus Thrombosis Associated With ZSH

Otolaryngologists are often involved in the care of patients with lateral sinus thrombosis (LST). It is usually the result of a complication of otitis media and mastoiditis. This case shows the importance of a thorough physical examination. Although the MRI study revealed fluid in the mastoids, our clinical examination was inconsistent with mastoiditis. Serological data provided further evidence of reactivation of the varicella virus. Based on the constellation of symptoms and findings, we hypothesize that ZSH is the etiology of the LST in our patient. Recognition of this condition can lead to implementation of appropriate therapy in a timely fashion, including the use of antiviral medication and anticoagulation.

CONCLUSION

LST is generally a complication of middle ear infection. Nonseptic LST, however, may

result from dehydration, oral contraceptive use, coagulopathy, or thyroid disease. This unusual case raises the suspicion that thrombosis resulted from VZV-associated thrombophlebitis in the ipsilateral cerebral venous sinuses along the second cervical nerve root distribution. A high index of suspicion is necessary in such cases so that a different treatment course can be identified and antiviral medication initiated promptly.

REFERENCES

1. Eidelberg D, Sortel A, Horoupian DS, et al: Thrombotic cerebral vasculopathy associated with herpes zoster. *Ann Neurol* 19:7-14, 1986
2. Barrett RE, Fraser RAR, Stein BM: A fluorescence histochemical survey of monoaminergic innervation of cerebral blood vessels in primate and humans. *Trans Am Neurol Assoc* 96:39-45, 1971
3. Saito K, Moskowitz MA: Contributions from the upper cervical dorsal roots and trigeminal ganglia to the feline circle of Willis. *Stroke* 20:524-526, 1989
4. Patrick JT, Russell E, Meyer J, et al: Cervical (C2) herpes zoster infection followed by pontine infarction. *J Neuroimaging* 5:192-193, 1995
5. Willeit J, Schmutzhard E: Cervical herpes zoster and delayed brainstem infarction. *Clin Neurol Neurosurg* 93:245-247, 1991
6. Fox RJ, Galetta SL, Mahalingam R, et al: Acute, chronic, and recurrent varicella zoster virus neuropathy without zoster rash. *Neurology* 57:351-354, 2001
7. Gildeen DH, Dueland AN, Devlin ME, et al: Varicella-zoster virus reactivation without rash. *J Infect Dis* 166:S30-34, 1996 (suppl 1)
8. Gildeen DH, Wright RR, Schneck SA, et al: Zoster sine herpete, a clinical variant. *Ann Neurol* 35:530-533, 1994