

Case Report

Successful resection of a left insular cavernous angioma using neuronavigation and intraoperative language mapping

H. Duffau¹ and D. Fontaine²

¹ Department of Neurosurgery, Hôpital de la Salpêtrière, Paris, France

² Department of Neurosurgery, Hôpital Pasteur, Nice, France

Received February 10, 2004; accepted July 14, 2004; published online August 30, 2004

© Springer-Verlag 2004

Summary

Despite recent literature advocating the surgical removal of symptomatic Cavernous Angiomas (CA), even in critical brain areas, very few observations of insular CA surgery have been described, particularly in the left hemisphere. We report the case of a successful resection of a CA located in the dominant insula, using both neuronavigation and intra-operative functional mapping.

This 33-year-old right-handed man harbored a left insular CA, revealed by generalized seizures following a bleed confirmed on MRI. The preoperative examination was normal.

A stereotactic-guided surgery was performed under local anesthesia, with intra-operative functional mapping using direct cortico-subcortical electrical stimulation in the awake patient – allowing the surgeon to achieve total resection of both CA and pericavernomatous gliosis, as shown on repeated postoperative MRIs. There was no postsurgical deficit, nor any seizure without treatment (follow-up: 4.5 years). The diagnosis of CA was confirmed by histological examination.

Taking account of the risk of morbidity due to the natural history of CA, particularly in eloquent brain regions, we suggest to routinely consider the possibility of a surgical treatment in cases of symptomatic (left dominant) insular CA, using combined intra-operative anatomical and physiological localization methods.

Keywords: Cavernous angioma; direct electrical stimulations; functional brain mapping; image-guided surgery; insula; language.

Introduction

Very few authors have reported the surgical resection of an insular CA, since to our knowledge, only 23 cases were found in the literature [3, 5, 7, 8, 16, 18, 19]. Among them, only 5 CA involved the left insula, with a post-operative aphasia and hemiplegia in one case, and residual seizures in the other [3].

Here, we report the case of a CA located in the left dominant insula, presenting with seizures due to a bleed,

and we describe the combination of the use of neuronavigation and intra-operative functional mapping in the awake patient – allowing a complete resection without any postoperative deficit nor any seizures with 4.5 years of follow-up to be achieved.

Case report

History

A 33-year-old right-handed (+90 at the Edinburg task) man without any disease presented with a generalized seizure in October 1999, with loss of consciousness and a head injury. After two days of confusion, the patient recovered to a normal neurological status. At that time, the Minimal Mental Status (MMS) was 30/30.

The initial CT scan showed a right subarachnoid hemorrhage, due to the head injury, and also a small left insular hematoma, leading to an MRI. A lesion measuring around 7 mm of diameter was confirmed within the left anterior insular lobe, with MRI characteristics consistent with the diagnosis of *CA which recently bled* – i.e. Type I in the classification of Zabramski, with hyperintensity on T1-, T2, and also FLAIR-weighted images (Fig. 1). It is to be noted that the angio-MRI was normal.

Taking into account the risk of rebleeding, and with the aim to minimize the risk of new seizures, surgical resection was proposed to the patient. Due to the location of the CA within the left insula, e.g. in a region known to play a major role in language [11], it was decided to conduct the surgery under local anesthesia with intra-operative functional mapping.

Surgical procedure

Surgery was conducted under local anesthesia in a lateral position, using a method previously described by the authors [12]. Briefly, after the fashioning of a fronto-pterional boneflap and the dura mater opening, a first electrical language mapping was performed at the level of the frontal operculum (Broca's area) in order to define the optimal parameters of stimulations. We used a 5 mm spaced-tips bipolar probe delivering a biphasic current (pulse frequency of 60 Hz, single pulse duration of 1 ms,

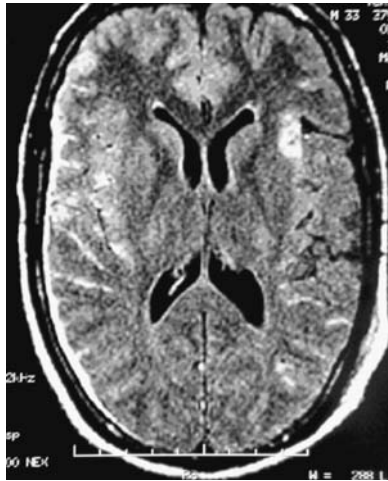

Fig. 1. Preoperative FLAIR-weighted MRI, showing a right sub-arachnoid hemorrhage due to the head injury (during the generalized seizure), and a small left anterior insular hematoma, consistent with the diagnosis of a CA which recently bled

Ojemann Cortical Stimulator, Radionics, Inc., Burlington, MA), allowing speech arrest during a counting task with an intensity of 5 mA.

Then, the Sylvian fissure was opened under the operating microscope, following an approach defined on the pre-operative 3D MRI, and integrated into the intra-operative neurosurgical stereotactic database (Surgiscope stereotactic image-guided system, Elekta). The CA was *not visible* at the level of the insular surface. Consequently, stimulations were again performed, with functional mapping of the insular cortex during naming tasks: a language site eliciting anomia during stimulation was identified, located 1 cm behind and above the entry point shown by the neuronavigation. There was no speech disturbance induced by stimulation at this entry point, and a corticotomy was performed at this level (between the Sylvian branches), allowing the surgeon to find and then remove the CA. To attempt to remove the pericavernomatous gliosis, because the boundaries were unclear between this gliosis and the normal

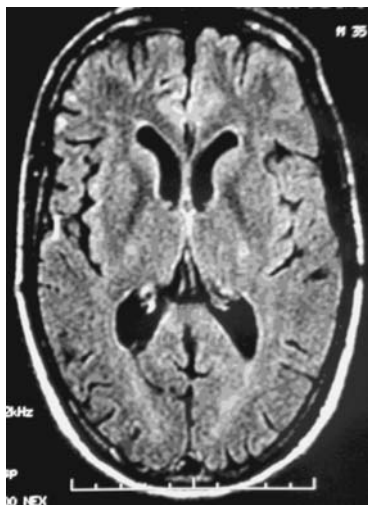


Fig. 2. Postoperative FLAIR-weighted MRI, performed 2 years after the surgery, showing a total resection of the lesion. The patient had a normal examination and returned to a normal life. The diagnosis of CA was confirmed on histological examination

neural tissue, direct subcortical electrical stimulation was used in the patient who continued to perform naming tasks: a deep stimulation generated a disruption of naming, and thus determined the limit of the surgical removal *using functional boundaries*.

Postoperative course

The postoperative course was uneventful. There was no deficit, even transitorily, particularly concerning language. The MMS was 30/30.

Histological examination clearly confirmed the diagnosis of CA.

The patient returned home 5 days after surgery, and to a normal socioprofessional life 1 month later (physiotherapist). The anti-epileptic drugs were stopped at the third month, without any seizure during a 4.5 year of follow-up. The delayed postoperative MRIs at one and 2 years confirmed the complete resection of the CA (Fig. 2).

Discussion

In the present report, we applied the combined methodologies of neuronavigation and intra-operative electrical language mapping to the resection of a CA located in the dominant insula.

Computer-assisted stereotactic techniques, allowing the surgeon to determine the exact location of the CA intra-operatively, with minimal manipulation of healthy cerebral tissue, were previously described as increasing the safety and accuracy of microsurgical exposure of lesions located in deep and/or eloquent regions [4, 20]. In our case, the image-guided system showed where the insular corticotomy should be performed, since the CA did not reach the surface (despite a pre-operative MRI which seemed to indicate this). The problem of brain shift was solved by the fact that the patient was in a lateral position, with an horizontal head: in case of a loss of cerebrospinal fluid during the opening of the Sylvian fissure, the brain goes down only in one direction – thus with stereotactic guidance still reliable.

In addition, intra-operative electrical stimulations, a precise and reliable method of real-time functional mapping as demonstrated for tumor surgery [2, 12], and already used during surgery of CA located in non-insular cortico-subcortical supra- and infra-tentorial eloquent regions [10, 14, 17], allowed us to identify the insular sites essential for language:

- before the corticotomy, we checked if the entry point determined by the neuronavigation was a functional site or not. Thus, if we would have encountered a speech sensitive area as the predetermined «optimal point of entry», we would have modified this entry point on the basis of the results of the functional mapping – i.e. we would have performed a corticotomy at the level where stimulations would have elicited no language disturbances;

– then at the end of the CA resection, to attempt to remove the pericavernomatous hemosiderin gliotic rim according to functional boundaries. Indeed, this gliosis is known first to contain potential associated telangiectasias or microscopic satellite cavernomatous lesions carrying a risk of rebleeding [1, 9]. The removal of the surrounding yellow-stained brain tissue containing hemosiderin and therefore iron, seems to improve the control of seizures [4]. Moreover, in the particular case of insular lesions, frequently associated with intractable seizures, the most complete resection possible is mandatory to decrease the risk of chronic residual epilepsy [13].

It is to be noted that there was no pain induced in this patient. Indeed, we avoided touching the insular branches of the middle cerebral artery during cortical stimulations. Then, we performed a subpial resection, i.e. without direct contact with these vessels.

Due to the implementation of these methodologies of anatomical and physiological localization, we performed a complete removal of the CA plus its gliotic rim, as demonstrated on repeated MRIs, without any postoperative worsening, nor any seizures despite the early stopping of anti-epileptic treatment. The patient returned to a normal socioprofessional life, with a 4.5 year seizure free of follow-up.

Conclusion

In conclusion, although surgical treatment of symptomatic CA still remains controversial when the lesion is located in critical brain structures, the risk of morbidity due to the natural history of this malformation is nevertheless higher precisely because the CA is situated in eloquent and/or deep regions [15]. Thus, «preventive» surgery appears particularly justified in these cases, since an optimal efficacy can be achieved [6]. On the other hand, if surgical resection is decided, it seems currently advisable to use both intraoperative neuronavigation and electrophysiological mapping, in order to increase the ratio Benefit/Risk – i.e. to maximize the quality of CA removal while minimizing the risk of neurological sequelae. Consequently, in the specific cases of *symptomatic (left dominant) insular CA*, taking account of the recent better understanding of the pathophysiology of this «fifth lobe», we advocate careful consideration of the possibility of an extensive surgical resection using *combined* modern technologies, particularly in young patients.

References

- Awad IA, Robinson JR Jr, Mohanty S, Estes ML (1993) Mixed vascular malformations of the brain: clinical and pathogenic considerations. *Neurosurgery* 33: 179–188
- Berger MS (1995) Functional mapping-guided resection of low-grade gliomas. *Clin Neurosurg* 42: 437–452
- Bertalanffy H, Gilsbach JM, Eggert HR, Seeger W (1991) Microsurgery of deep-seated cavernous angiomas: report of 26 cases. *Acta Neurochir (Wien)* 108: 91–99
- Boecher-Scharwz HG, Grunert P, Guenther M, Kessel G, Mueller-Forell W (1996) Stereotactically guided cavernous malformation surgery. *Minim Invasive Neurosurg* 39: 50–55
- Casazza M, Broggi G, Franzini A, Avanzini G, Spreafico R, Bracchi M, Valentini MC (1996) Supratentorial cavernous angiomas and epileptic seizures: preoperative course and postoperative outcome. *Neurosurgery* 39: 26–32
- Chang HS, Hongo K, Nakagawa H, Tsuge T (2001) Surgical decision-making on cerebral cavernous malformations. *J Clin Neurosci* 8: 416–420
- Chaskis C, Brotchi J (1998) The surgical management of cerebral cavernous angioma. *Neurol Res* 20: 597–606
- Cukiert A, Forster C, Andrioli MS, Frayman L (1998) Insular epilepsy. Similarities to temporal lobe epilepsy. Case report. *Arq Neuropsiquiatr* 56: 126–128
- Duffau H, Capelle L, Sichez JP, Faillot T, Van Effenterre R, Bitar A, Arthuis F, Fohanno D (1997) Early rebleeding from intracranial cavernous angiomas: report of 6 cases and a review of the literature. *Acta Neurochir (Wien)* 139: 914–922
- Duffau H (2000) Intraoperative direct subcortical stimulation for identification of the internal capsule, combined with an image-guided stereotactic system during surgery for basal ganglia lesions. *Surg Neurol* 53: 250–254
- Duffau H, Capelle L, Lopes M, Faillot T, Sichez JP, Fohanno D (2000) The insular lobe: physiopathological and surgical considerations. *Neurosurgery* 47: 801–811
- Duffau H, Capelle L, Sichez N, Denvil D, Lopes M, Sichez JP, Bitar A, Fohanno D (2002) Intraoperative mapping of the subcortical language pathways using direct stimulations. An anatomofunctional study. *Brain* 125: 199–214
- Duffau H, Capelle L, Lopes M, Bitar A, Sichez JP, Van Effenterre R (2002) Medically intractable epilepsy from insular low-grade gliomas: improvement after an extended lesionectomy. *Acta Neurochir (Wien)* 144: 563–573
- Eisner W, Butscher J, Bale R, Sweeney R, Koppelstatter F, Golaszewski S, Kolbitsch C, Twerdy K (2002) Use of neuro-navigation and electrophysiology in surgery of subcortically located lesions in the sensorimotor strip. *J Neurol Neurosurg Psychiatry* 72: 378–381
- Porter PJ, Willinsky RA, Harper W, Wallace MC (1997) Cerebral cavernous malformations: natural history and prognosis after clinical deterioration with or without hemorrhage. *J Neurosurg* 87: 190–197
- Schmitt JJ, Ebner A (2000) The anatomic substrate of the epigastric aura – a case report. *Nervenarzt* 71: 485–488
- Steinberg GK, Chang SD, Gewirtz RJ, Lopez JR (2000) Microsurgical resection of brainstem, thalamic, and basal ganglia angiographically occult vascular malformations. *Neurosurgery* 46: 260–270
- Tirakotai W, Sure U, Benes L, Kruschek B, Siegfried B, Bertalanffy H (2003) Image-guided transsylvian, transinsular approach for insular cavernous angiomas. *Neurosurgery* 53: 1299–1305
- Woydt M, Krone A, Soerensen N, Roosen K (2001) Ultrasound-guided neuronavigation of deep-seated cavernous haemangiomas:

clinical results and navigation techniques. *Br J Neurosurg* 15: 485–495

20. Zamorano L, Matter A, Saenz A, Buciu R, Diaz F (1997) Interactive image-guided resection of cerebral cavernous malformations. *Comput Aided Surg* 2: 327–332

Comments

The authors describe a 33 year old patient who presented with seizures and was found to have a left insular cavernous malformation. They elected to proceed with surgical resection of the lesion under stereotactic guidance with speech area mapping with the patient awake. This technique has been used by a number of authors to resect a variety of tumours and malformations in the insular region.

C. S. Ogilvy
Massachusetts

The authors are to be congratulated on their excellent description of an interesting patient with a left insular cavernoma presenting with seizures. They rightly stress the need for optimal adjunct to high-level microsurgical procedures, and they achieve an excellent result.

H. M. Mehdorn
Kiel

The authors report the surgical removal of a small cavernous angioma located in the anterior portion of the left (dominant) insula in a 33 year-old patient using both neuronavigation and awake surgery with language monitoring. The lesion was totally removed including the surrounding

haemosiderin stained gliosis and the patient experienced no additional morbidity. The authors recommend to consider the combined use of intraoperative anatomical (neuronavigational) and physiological (functional brain mapping) localization methods in the specific cases of symptomatic left dominant insular cavernomas. By emphasizing the importance of modern neurosurgical localization methods, the authors provide an important contribution to the pertinent literature. I congratulate the authors for this good outcome, but I wish to add a few more points. Even though this lesion was not visible on the surface of the insula, its subpial location in the anterior part of the insula was clearly demonstrated on preoperative MRI. A straight-line approach through the anterior sylvian fissure leads exactly to the target point, allowing for almost no alternative choice. In my experience, the site of insular incision is greatly influenced by the local anatomical situation in addition to the exact location of the cavernoma. Particularly the vascular pattern, for instance of deep sylvian veins, plays an important role. Practically, the number of entry points into the insula is very limited in each specific case, leaving the surgeon with very few alternative choices, which in turn may reduce the value of the insular cortical mapping. In the cases I have treated surgically so far, including several left-sided subinsular cavernomas, I always kept the incision to a minimum even in larger lesions than the present one. As we have previously described (Ref. [18] of this case report), our surgical approach was different in lesions located within the posterior insula.

H. Bertalanffy
Marburg

Correspondence: Hugues Duffau, Service de Neurochirurgie, Hôpital de la Salpêtrière, 47-83 Bd de l'hôpital, 75651 Paris, Cedex 13, France. e-mail: hugues.duffau@psl.ap-hop-paris.fr