



ELSEVIER

Brain & Development 26 (2004) 481–483

**BRAIN &
DEVELOPMENT**

Official Journal of
the Japanese Society
of Child Neurology

www.elsevier.com/locate/braindev

Case report

Beneficial effect of L-arginine for stroke-like episode in MELAS

Masaya Kubota^{a,*}, Yoichi Sakakihara^a, Masato Mori^b, Takanori Yamagata^b,
Mariko Momoi-Yoshida^b

^aDepartment of Pediatrics, University of Tokyo, 7-3-1, Hongo, Bunkyo-ku, Tokyo 113-8655, Japan

^bDepartment of Pediatrics, Jichi Medical School, 3311-1, Yakushiji, Minamikawachi-chou, Kawachi-gun, Tochigi 329-0498, Japan

Received 2 September 2003; received in revised form 5 January 2004; accepted 24 January 2004

Abstract

We here reported the clinical course and therapeutic details of a 16-year-old girl with mitochondrial myopathy, encephalopathy, lactic acidosis, and stroke-like episodes (MELAS) who had had five stroke-like episodes (two episodes were clinically mild, while the three subsequent episodes were severe). Among the three episodes, the symptoms improved earliest and magnetic resonance spectroscopy abnormality was minimal when given L-arginine in addition to prednisolone, glycerol and edalavone. L-arginine administration during the acute phase of MELAS might be a potential therapy to reduce brain damage due to mitochondrial dysfunction.

© 2004 Elsevier B.V. All rights reserved.

Keywords: Mitochondrial myopathy, encephalopathy, lactic acidosis, and stroke-like episodes; L-arginine; Magnetic resonance spectroscopy; Stroke-like episodes

1. Introduction

Although MELAS (mitochondrial myopathy, encephalopathy, lactic acidosis, and stroke-like episodes) is a systemic disorder of mitochondrial dysfunction caused by mitochondrial DNA mutation, the pathogenesis of stroke-like episodes is not yet clear. It is regarded that stroke-like episodes are not simple infarcts but the results of transient oxidative-phosphorylation failure within the brain. Although prophylactic or supportive therapies for each symptom were reported to be partially effective [1–4], the disease is basically progressive. Once stroke-like episodes have begun to occur frequently, the general status of the patient tends to deteriorate progressively. Recently, Koga et al. [5] reported that L-arginine therapy improved microcirculation of the brain and thus reduced tissue injury from ischemia during the acute phase of stroke-like episodes in MELAS. L-arginine is a potent donor of nitric oxide, which may reduce ischemic damage in the acute phase of focal brain ischemia. We here reported the clinical course and therapeutic details of a 16-year-old girl with MELAS who had had five stroke-like episodes and discuss

the efficacy of L-arginine therapy as demonstrated by MRS (proton magnetic resonance spectroscopy).

2. Case report

The diagnosis of MELAS was confirmed by muscle biopsy findings including ragged red fibers and gene analysis (point mutation of A3243G in the mitochondrial tRNA^{Leu}(UUR) gene), at the age of 8 years when the patient developed limb weakness and easy fatigability. Starting at 9 years of age, dichloroacetate (DCA) and vitamin B1 administration lowered the elevated levels of lactate and pyruvate in the serum and CSF and ameliorated abdominal pain, headache, and improved school performance and fatigability.

At the *first* stroke-like episode when she was 14 years old, she demonstrated generalized tonic clonic seizure lasting 10 min and severe headache. These symptoms immediately subsided after diazepam administration. At the age of 15 years, she complained of severe headache and teichopsia associated with left-sided seizure originating from the eyelid (the *second* episode). Diazepam and acetoaminophen therapy improved these symptoms. The *third* episode occurred 7 days after the second episode,

* Corresponding author. Tel.: +81-3-3815-5411x33454; fax: +81-3-3816-4108.

E-mail address: mkmegped@opal.plala.or.jp (M. Kubota).

i.e. the patient complained of teichopsia again and this was accompanied by visual hallucination and left-sided blindness. In addition, nausea and headache developed. T2-weighted brain MRI demonstrated abnormal high intensity in the right occipito-temporal area. Seven days after the onset of the third episode, prednisolone and glycerol administration were started but it took 4 days to stop the visual symptoms and headache. Delayed effectiveness of the main therapy during this episode resulted in irreversible atrophic changes in the right occipito-temporal area. The patient was discharged after 25 days of hospitalization. Three months later, she was readmitted to our hospital because of the *fourth* episode which began with eyelid myoclonic seizure. The seizure was partially suppressed with diazepam, but severe headache, aphasia and the right-sided blindness also developed in addition to the partial seizure. Combined therapy with prednisolone, glycerol and edalavone started immediately. T2-weighted brain MRI showed abnormal high intensity at the left occipito-temporal area (Fig. 1c). Simultaneously recorded proton MRS disclosed extremely elevated lactate and reduced *N*-acetylaspartate (NAA) in the affected area (Fig. 1a). Three days after onset, she was able to speak fluently, but visual symptoms such as teichopsia and right-sided blindness persisted even on the 6th day of hospitalization. By the 8th day of hospitalization, her general condition had recovered except for mild teichopsia.

One month later, the *fifth* episode began with right-sided hemiconvulsion which was not controlled with diazepam. Seizures occurred every 2–3 min with about 1-min duration, and occasionally progressed to secondary generalized seizure. Consciousness disturbance during the interictal phase was evident and right-sided hemiparesis

and sensory loss persisted. The seizure frequency was slightly decreased with midazolam. The same therapy as given for the fourth episode, i.e. prednisolone, glycerol and edalavone administration was started immediately. In addition, L-arginine (15 g (0.5 g/kg weight)) was administered intravenously starting 5 h after onset. Brain MRI (FLAIR, fluid attenuated inversion recovery) showed abnormal high intensity at the left parietal area, which did not overlap the area affected during the fourth episode (Fig. 1d). One hour after L-arginine infusion, the seizure disappeared and consciousness gradually recovered. There was no adverse effect recognized. Within 24 h after L-arginine infusion, consciousness disturbance and right-sided sensori-motor problems disappeared. Compared with the fourth episode, proton MRS showed that the lactate signal was low and NAA signal seemed normal in the affected area (Fig. 1b).

3. Discussion

The first two stroke-like episodes were clinically mild, while the three subsequent episodes were severe. Durations of hospitalization of the last three episodes were 25, 8 and 4 days for the third, fourth and fifth episodes, respectively. Although the severity of disability was almost the same among these three episodes, the symptoms improved earliest after the fifth episode compared to the other two episodes. Steroid and glycerol were used for all three episodes and edalavone for the last two episodes during the acute phase, while L-arginine was additionally administered only for the fifth episodes. Although the exact mechanism of L-arginine activity

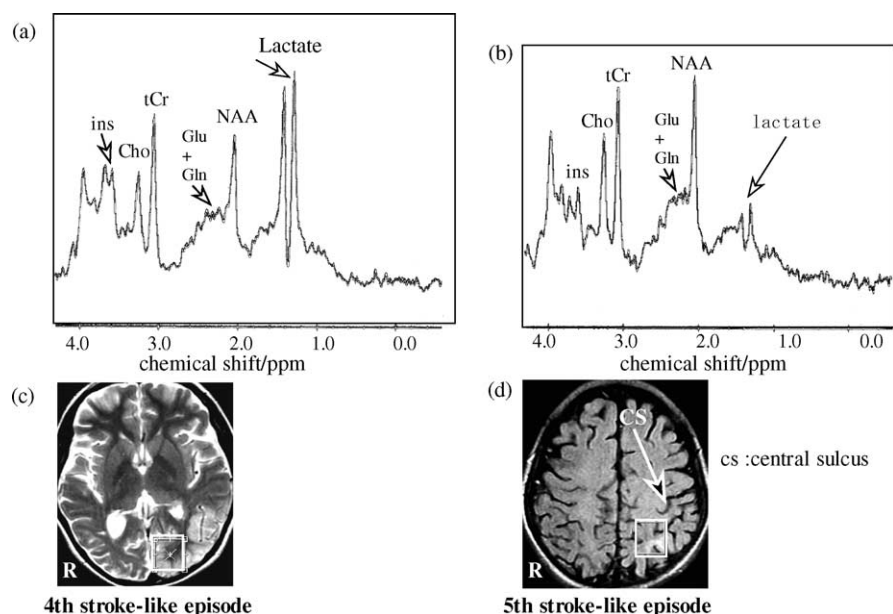


Fig. 1. Proton magnetic resonance spectroscopy (a,b) and brain magnetic resonance images (c,d) during fourth and fifth stroke-like episodes, respectively. As compared images during the fifth episode, the lactate level was extremely high and *N*-acetylaspartate (NAA) level was low during fourth episode. Boxes indicate volumes of interest for spectroscopy. M-ins, myo-inositol; Cho, Choline compound; tCr, creatine/phosphocreatine; Glu + Gln, glutamate/glutamine.

during the on-going stroke-like episode is not known, it seems to have had some beneficial effect.

Proton MRS has been shown to be a useful tool which may be of help in the diagnosis and treatment of a large number of disorders affecting the pediatric brain [6]. There have been many reports demonstrating that proton MRS might help to monitor therapeutic efficacy in mitochondrial disorders [7–10]. On proton MRS, acute cortical lesions in mitochondrial disorders were characterized by severely elevated lactate levels and reduced concentrations of NAA, glutamate, and myo-inositol. As shown in Fig. 1, MRS during the fourth episode demonstrated strongly elevated lactate and reduced NAA, in the left occipito-temporal cortex, whereas during the fifth episode, lactate signal was not as high and NAA signal was normal in the left parietal cortex. Lactate is a product of anaerobic glycolysis and has a doublet peak structure centered at 1.33 ppm. This compound is usually not present at MRS-detectable concentration (<0.7 mM) in the normal brain. Lactate elevation is considered to reflect the mitochondrial energy failure, which is the main pathology in MELAS. A relative decrease in NAA may reflect decreased neuronal viability, neuronal function, or neuronal loss.

As suggested by Koga et al. [5], vasodilation induced by L-arginine as a potent donor of nitric oxide might improve vasogenic energy failure causing the lactate elevation.

Taking the clinical course and MRS findings together, L-arginine administration during the acute phase of MELAS might be a potential therapy to reduce brain damage due to mitochondrial energy failure, although more extensive

study in a larger population is needed to draw a definite conclusion.

References

- [1] Goda S, Hamada T, Ishimoto S, Kobayashi T, Goto I, Kuroiwa Y. Clinical improvement after administration of coenzyme Q10 in a patient with mitochondrial encephalomyopathy. *J Neurol* 1987;234: 62–3.
- [2] Tanaka J, Nagai T, Arai H, Inui K, Yamanouchi H, Goto Y, et al. Treatment of mitochondrial encephalomyopathy with a combination of cytochrome C and vitamins B1 and B2. *Brain Dev* 1997;19:262–7.
- [3] Kuroda Y, Ito M, Naito E, Yokota I, Matsuda J, Saijo T, et al. Concomitant administration of sodium dichloroacetate and vitamin B1 for lactic acidemia in children with MELAS syndrome. *J Pediatr* 1997;131:450–2.
- [4] Saitoh S, Momoi MY, Yamagata T, Mori Y, Imai M. Effects of dichloroacetate in three patients with MELAS. *Neurology* 1998;50: 531–4.
- [5] Koga Y, Ishibashi M, Ueki I, Yatsuga S, Fukiyama R, Akita Y, et al. Effects of L-arginine on the acute phase of strokes in three patients with MELAS. *Neurology* 2002;58:827–8.
- [6] Moore GJ. Proton magnetic resonance spectroscopy in pediatric neuroradiology. *Pediatr Radiol* 1998;28:805–14.
- [7] Castillo M, Kwock L, Green C. MELAS syndrome: imaging and proton MR spectroscopic findings. *Am J Neuroradiol* 1995;16:233–9.
- [8] Pavlakis SG, Kingsley PB, Kaplan GP, Stacpoole PW, O'Shea M, Lustbader D. Magnetic resonance spectroscopy: use in monitoring MELAS treatment. *Arch Neurol* 1998;55:849–52.
- [9] Wilichowski E, Pouwels PJ, Frahm J, Hanefeld F. Quantitative proton magnetic resonance spectroscopy of cerebral metabolic disturbances in patients with MELAS. *Neuropediatrics* 1999;30:256–63.
- [10] Moller HE, Wiedermann D, Kurlemann G, Hilbich T, Schuierer G. Application of NMR spectroscopy to monitoring MELAS treatment: a case report. *Muscle Nerve* 2002;25:593–600.