

## Case Report

# Human Kluver-Bucy syndrome following acute subdural haematoma

Y. Yoneoka<sup>1,2</sup>, N. Takeda<sup>1,2</sup>, A. Inoue<sup>1</sup>, Y. Ibuchi<sup>1</sup>, T. Kumagai<sup>1</sup>, T. Sugai<sup>1</sup>,  
K.-I. Takeda<sup>1</sup>, and K. Ueda<sup>1</sup>

<sup>1</sup> Department of Neurosurgery, Yamagata Prefecture Central Hospital, Yamagata, Japan

<sup>2</sup> Department of Emergency Medicine, Yamagata Prefecture Central Hospital, Yamagata, Japan

Published online September 13, 2004

© Springer-Verlag 2004

## Summary

We present a rare case of complete human Kluver-Bucy syndrome (KBS) following recovery from transtentorial herniation caused by acute subdural haematoma (ASDH). A 17-year-old right-handed high school boy got into stupor within five minutes after 3-rounds of sparring at boxing. Emergency computed tomographic (CT) scan showed right cerebral hemispheric ASDH, which was evacuated following intentional decompressive craniectomy. After recovery of consciousness, he developed emotional changes (placidity with loss of normal fear and anger), psychic blindness, aberrant sexual behaviour, excessive oral tendencies, increased appetite, and hypermetamorphosis in order of mention, which were observed with waxing and waning from 17th to 28th hospital day. Peri-operative CT scanning and magnetic resonance imaging showed lesions of the right temporal lobe and right-dominant orbitofrontal regions including bilateral rectal and medial orbital gyri, and the intact left temporal lobe. Two pathogeneses can be thought of and the whole picture of KBS following ASDH can arise even though one (left in this case) temporal lobe is preserved, 1) in which associated orbitofrontal lesions of the frontal lobes may correlate with occurrence of KBS, or 2) cerebral blood hypoperfusion of both temporal lobes due to increased intracranial pressure and/or compression of both posterior cerebral arteries at the edge of the tentorium cerebelli occurs.

**Keywords:** Kluver-Bucy syndrome; acute subdural hematoma; temporal lobe; orbitofrontal region; posterior cerebral artery.

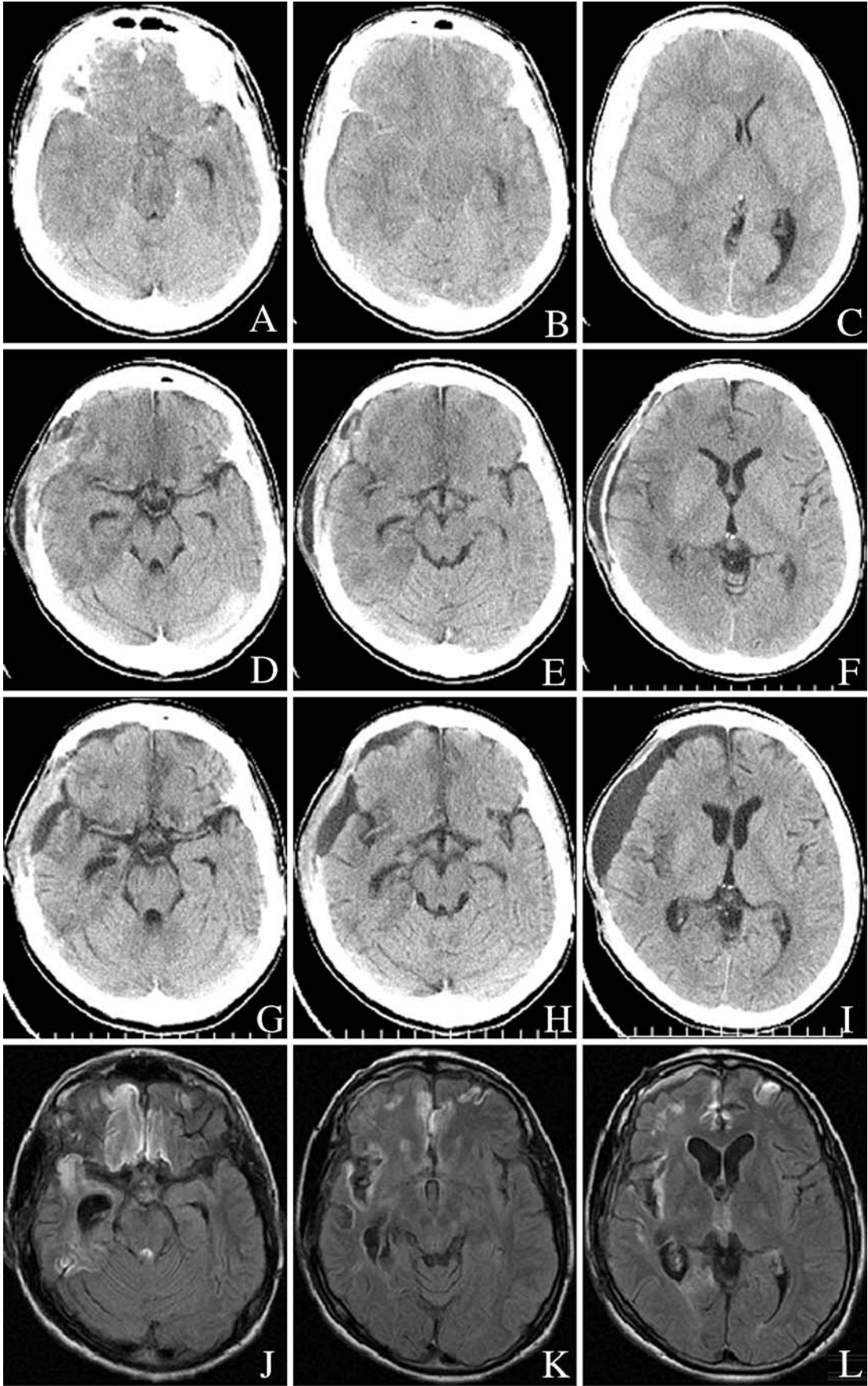
## Introduction

Since Kluver and Bucy first described the syndrome including tendencies to examine all objects orally, loss of anger and fear responses, increased sexual activity and “psychic blindness” following bilateral temporal lobectomy in rhesus monkeys [14, 15], the clinical presentation and anatomical correlation with a human Kluver-Bucy syndrome (KBS) has been discussed [3, 4, 7, 10, 11, 13, 16, 18, 20, 21, 24]. Among them, unilateral

temporal lobe lesions [4, 11, 22] have been noted to produce the KBS although KBS has been classically associated with bitemporal lesions. Interestingly, all the three cases of unitemporal-lesion-induced KBS affected the left temporal lobe [4, 11, 22]. We report an extremely rare case of complete human KBS following recovery from right-sided transtentorial herniation caused by acute subdural haematoma (ASDH). Our case presented with emotional changes (placidity with loss of normal fear and anger), psychic blindness, aberrant sexual behaviour, excessive oral tendencies, increased appetite, and hypermetamorphosis (in order of mention) without aphasia, amnesia, finger agnosia, or right-left disorientation, which were self-limited and observed with waxing and waning after regression of cerebral oedema in the right temporal and right-dominant orbitofrontal regions. In this article, we discuss the pathogenesis of transient human KBS following right-sided ASDH.

## Case report

A 17-year-old right-handed high school boy lapsed into stupor within five minutes after 3-rounds of sparring at boxing. He had a past one-week hospitalization history of minor traumatic subarachnoid haemorrhage without cerebral contusion complicated only by headache after a boxing competition four months prior to admission, which was self-limited and never affected his good level of academic achievement nor his popularity as a boxer in high school. On arrival (Day0), he was in coma with decerebrate rigidity and a dilated right pupil, indicating right-sided uncal herniation. An emergency computed tomographic (CT) scan showed right cerebral hemispheric ASDH with midline shift to the left, which was successfully evacuated after intentional decom-



pressive craniectomy. Micro-operative observation to investigate the origin of the subdural bleeding confirmed rupture of the right olfactory bulb and its vasculature. Further cerebral contusion was not observed. Bleeding from the frontal base was controlled by bipolar coagulation and gentle pressure. Postoperative examinations showed mild left-sided hemiparesis (until discharge), stupor (for seven days), and conjugate deviation of eyes to the right (for eight days). Postoperative CT scans showed transient oedema of the right temporal and basal frontal lobes (bilateral rectal and medial orbital gyri) until 11th postoperative day (POD11) but the intact left temporal lobe remained intact. Following recovery of consciousness, he developed emotional changes (placidity with loss of normal fear and anger), psychic blindness (loss of recognition of people, even his parents, e.g. calling his mother “fairy”), aberrant sexual behaviour (mainly abnormal sexual desire and verbalization), excessive oral tendencies (a strong tendency to examine all objects orally, putting objects in mouth, licking, biting, chewing, touching with lips), increased appetite (to spend the whole time blind eating), and hypermetamorphosis (strong tendency to react to every visual stimulus, to touch everything in sight, and to attend to every visual stimulus with grasping, hugging movements) in that order, which showed some overlapping and were observed with waxing and waning from POD16 to POD27. Orientation and memory function were preserved during the affected period. Examinations detected no aphasia, amnesia, acalculia, finger agnosia, or right-left confusion, indicating intact left temporoparietal lobes. He could sing as well as he sang before admission. Electroencephalogram (EEG) failed to detect seizure activity. He left our hospital on foot with mild clumsiness of the right extremities and returned to the high school he went to before admission. Follow-up magnetic resonance (MR) imaging on POD89 revealed mainly the right atrophic anterior temporal lobe, damage of the basal frontal lobes (bilaterally rectal and medial orbital gyri), and the intact left temporal lobe. He led a meaningful school life and proceeded to a local college 14 months after discharge in spite of a worse school record than he had prior to the present episode.

## Discussion

To the best of our knowledge, this is the first report of transient complete human Kluver-Bucy syndrome (KBS) following a unilateral acute subdural haematoma: an extra-neuro-axial lesion. A combination of at least 3 or more of the symptoms and signs is typically suggestive of the Kluver-Bucy Syndrome [12]. Our patient presented the six major components of KBS as exposed by Rossitch [21]: (1) Placidity, (2) Psychic blindness, (3) Hypersexuality, (4) Increased oral activity, (5) Increased appetite, (6) Hypermetamorphosis. Amnesia or aphasia, however, was not observed in our case. In humans, KBS is generally incomplete [6, 19, 23, 24]. Complete KBS as found in this case is less frequent [4, 11, 18, 20].

Several reports about KBS without bitemporal lesions are available [2, 11, 17, 20, 22]. These have not completely ruled out the possibility of transient or permanent bitemporal dysfunction caused by haemodynamic [17], epileptic [2, 11], traumatic [22] events.

Formisano *et al.* describes Kluver-Bucy syndrome as a syndrome associated with favourable prognosis in the outcome of traumatic disturbances of consciousness in survivors of head trauma [8]. The dynamics in the development of a KBS show a delineation between a pre-stage, full-stage, and remission stage [10]. These stages only occur in posttraumatic cases and have not been seen in KBS of other etiology [1]. In our case, as described in the literature [1, 8, 10], KBS was observed with waxing and waning after remission of oedema of the right temporal and bifrontobasal regions (bilateral rectal and medial orbital gyri), which culminated in full recovery.

KBS has first been described as a result of total bilateral temporal lobectomy in rhesus monkeys [15]. On the other hand, KBS has already been reported in the literature as atypical post-traumatic remission phase [9]. This syndrome, consisting in the increase of oral automatisms and of sexual drive, has been interpreted as a disconnection syndrome with loss of inhibitory cortical control over the limbic system [10]. The orbitofrontal and caudal medial (limbic) prefrontal cortices receive major projections from the amygdala, associated with emotional memory, and from medial temporal and thalamic structures associated with long-term memory [5].

Thus, as demonstrated by CT scans, the chief cause of the presented self-limited KBS was responsible for, albeit hypothetically, oedema-induced transient dysfunction of the right temporal and the basal frontal lobes (bilateral rectal and medial orbital gyri which are supposed to conduct inhibitory cortical control over the limbic system). This is applicable as a pathogenesis of KBS to the one case with putaminal hemorrhage [20].

As an alternative pathogenesis of KBS following recovery from transtentorial herniation, cerebral blood hypoperfusion of both temporal lobes due to increased intracranial pressure and/or compression of both posterior cerebral arteries at the edge of the tentorium cerebelli

Fig. 1. (A, B, and C) Preoperative CT scan images on admission (Day0) show right hemispheric acute subdural haematoma with midline shift to the left. (D, E, and F) Post-decompression CT scan images on postoperative day (POD) 11 demonstrate oedema of the right temporal and basal frontal lobes (bilateral rectal and medial orbital gyri) and reveal the intact left temporal lobe. (G, H, and I) Post-decompression CT scan images on POD29 show regression of the oedema. (J, K, and L) Fluid attenuation inversion recovery images on POD89 reveal damaged scars in the basal frontal lobes and the right temporal lobe with the dilated temporal horn indicating atrophy

can be implicated. So, KBS described in this report can be compatible with reversible ischemic neurological deficits due to ASDH. This hypothesis, however, has a little difficulty explaining the rarity of KBS following transtentorial herniation; Neurosurgeons encounter transtentorial herniation occasionally but KBS scarcely. Disturbance of consciousness during the recovery phase may mask KBS following transtentorial herniation in many cases.

KBS remains a fascinating syndrome whose exact neuro-anatomical basis is unclear. The presented transient KBS caused by oedema of the right temporal lobe and bilateral rectal and medial orbital gyri bilaterally following right ASDH, sparing the left temporal lobe, provides new and interesting insights into the potential pathophysiology of KBS. The self-limited etiology of our case provides not only a hypothetical pathogenesis of KBS but also an important framework for deciphering its infrequency and the mechanisms of both post-traumatic and non-traumatic cases.

### Acknowledgement

We deeply appreciate Susumu SATOH, M.D., ex-director of our medical center, for his critical review of our manuscript.

### References

- Aichner F (1984) Phenomenology of the Kluver-Bucy syndrome in man. *Fortschr Neurol Psychiatr* 52: 375–397
- Anson JA, Kuhlman DT (1993) Post-ictal Kluver-Bucy syndrome after temporal lobectomy. *J Neurol Neurosurg Psychiatry* 56: 311–313
- Assal G (1985) Post-traumatic deficit syndromes. *Schweiz Arch Neurol Psychiatr* 136: 17–24
- Bakchine S, Chain F, Lhermitte F (1986) Complete human Kluver-Bucy syndrome after encephalitis caused by herpes simplex type 2. *Rev Neurol (Paris)* 142: 126–132
- Barbas H (2000) Connections underlying the synthesis of cognition, memory, and emotion in primate prefrontal cortices. *Brain Res Bull* 52: 319–330
- Burns A, Jacoby R, Levy R (1990) Psychiatric phenomena in Alzheimer's disease. IV: disorders of behaviour. *Br J Psychiatry* 157: 86–94
- Cummings JL, Duchon LW (1981) Kluver-Bucy syndrome in Pick disease: clinical and pathologic correlations. *Neurology* 31: 1415–1422
- Formisano R, Saltuari L, Gerstenbrand F (1995) Presence of Kluver-Bucy syndrome as a positive prognostic feature for the remission of traumatic prolonged disturbances of consciousness. *Acta Neurol Scand* 91: 54–57
- Gerstenbrand F, Lucking CH (1971) The Kluver-Bucy syndrome during recovery from severe cerebral injuries (author's transl). *J Neurovisc Relat [Suppl]* 10: 524–537
- Gerstenbrand F, Poewe W, Aichner F, Saltuari L (1983) Kluver-Bucy syndrome in man: experiences with posttraumatic cases. *Neurosci Biobehav Rev* 7: 413–417
- Ghika-Schmid F, Assal G, De Tribolet N, Regli F (1995) Kluver-Bucy syndrome after left anterior temporal resection. *Neuropsychologia* 33: 101–113
- Guedalia JS, Zlotogorski Z, Goren A, Steinberg A (1993) A reversible case of Kluver-Bucy syndrome in association with shigellosis. *J Child Neurol* 8: 313–315
- Horel JA, Keating EG (1969) Partial Kluver-Bucy syndrome produced by cortical disconnection. *Brain Res* 16: 281–284
- Kluver H, Bucy PC (1938) An analysis of certain effects of bilateral temporal lobectomy in the rhesus monkey with special reference to "psychic blindness." *J Psycho* 5: 33–54
- Kluver H, Bucy PC (1939) Preliminary analysis of functions of the temporal lobes in monkeys. *Arch Neurol Psychiatr* 42: 979–1000
- Lilly R, Cummings JL, Benson DF, Frankel M (1983) The human Kluver-Bucy syndrome. *Neurology* 33: 1141–1145
- Muller A, Baumgartner RW, Rohrbach C, Regard M (1999) Persistent Kluver-Bucy syndrome after bilateral thalamic infarction. *Neuropsychiatry Neuropsychol Behav Neurol* 12: 136–139
- Nicolai A, Lazzarino LG, Alari E (1991) Partial Kluver-Bucy syndrome arising from a multicentric glioblastoma: anatomoclinical study of a case with unusual involvement of CNS. *Clin Neuropathol* 10: 16–20
- Pilleri G (1966) The Kluver-Bucy Syndrome in man. A clinico-anatomical contribution to the function of the medial temporal lobe structures. *Psychiatr Neurol (Basel)* 152: 65–103
- Rossitch E Jr, Carrazana EJ, Ellenbogen R, Alexander E 3<sup>rd</sup> (1989) Kluver-Bucy syndrome following recovery from transtentorial herniation. *Br J Neurosurg* 3: 503–506
- Rossitch E Jr, Oakes WJ (1989) Kluver-Bucy syndrome in a child with bilateral arachnoid cysts: report of a case. *Neurosurgery* 24: 110–112
- Salim A, Kim KA, Kimbrell BJ, Petrone P, Roldan G, Asensio JA (2002) Kluver-Bucy syndrome as a result of minor head trauma. *South Med J* 95: 929–931
- Sourander P, Sjogren H (1970) The concept of Alzheimer's disease and its clinical implications. Alzheimer's disease and related conditions. In: Wolenstenholme G, O'Connor M (eds) Churchill, London, pp 11–32
- Terizian H, Dalle Ore G (1955) Syndrome of Kluver and Bucy reproduced in man by bilateral removal of the temporal lobes. *Neurology* 5: 373–380

### Comment

This interesting case report describes a 17-year old patient who went through a transient complete Kluver-Bucy syndrome caused by an acute subdural haematoma following a sports accident. This case presentation provides some interesting and rare observations because a complete Kluver-Bucy syndrome is rarely encountered in the neurosurgical treatment of acute subdural haematomas. Furthermore, the authors demonstrate that the whole clinical picture of KBS was transiently expressed although the left temporal lobe was not significantly effected by the trauma as shown on the CT and MRI scans. This provides new and interesting insights into the potential pathophysiology of KBS and is therefore of considerable interest for the neurosurgical community.

G. Nikkhah

Correspondence: Yuichiro Yoneoka, Department of Neurosurgery, Yamagata Prefecture Central Hospital, 1800 Aoyagi, Yamagata, 990-2292, Japan. e-mail: yone@bri.niigata-u.ac.jp