

Minimally Invasive Management of a Traumatic Artery Aneurysm Resulting from Shaken Baby Syndrome

Nicholas B. Levine^b Tomoko Tanaka^a Blaise V. Jones^a Kerry R. Crone^{a,b}

Departments of Neurosurgery, ^aCincinnati Children's Hospital Medical Center, and
^bUniversity of Cincinnati College of Medicine, Cincinnati, Ohio, USA

Key Words

Traumatic aneurysms · Pericallosal artery ·
Posttraumatic obstructive hydrocephalus ·
Third ventriculostomy · Coiling

Abstract

Based on our review of the literature, we present the first use of coiling in an infant with a traumatic artery aneurysm that resulted from shaken baby syndrome. Computed tomography (CT) scans showed a skull fracture, hemorrhagic subdural collections, multiple parenchymal contusions, and intraventricular and subarachnoid hemorrhages in a 3-week-old infant who presented with lethargy, poor feeding, and seizure. These multiple injuries were consistent with shaken baby syndrome. After closed-head injury medical management, including subdural taps, the baby was discharged home. When increasing seizures and hydrocephalus developed 8 months later, CT angiographic scans showed a pseudoaneurysm of the anterior cerebral artery. We successfully occluded the aneurysm with pushable coils placed via a microcatheter and treated the obstructive hydrocephalus with endoscopic third ventriculostomy. We show that minimally invasive radiological and surgical techniques may be effective in managing the sequelae of trauma in children.

Case Report

A 3-week-old infant presented with lethargy, poor feeding, and seizure. The patient was intubated and the initial examination was significant for sluggish yet reactive pupils, an absent gag reflex, and a bulging anterior fontanel. Computed tomography (CT) revealed a right parietal linear skull fracture, bilateral hemorrhagic subdural collections, multiple parenchymal contusions, intraventricular hemorrhage, and subarachnoid hemorrhage (fig. 1). Constellations of other injuries (i.e., bilateral retinal hemorrhages, a right tibial fracture, a spinal epidural hematoma) were all consistent with shaken baby syndrome. We began intracranial pressure monitoring and closed-head injury medical management, which included serial subdural taps. The baby responded to treatment and was discharged home 1 month later.

Eight months after discharge, the baby was hospitalized because of increasing seizure activity. A CT scan showed obstructive hydrocephalus that was likely secondary to intraventricular hemorrhage resulting in occlusion of the cerebral aqueduct, and a hyperdense focus with calcification anterior to the lamina terminalis (fig. 2). Subsequent CT angiographic scan showed a pseudoaneurysm of the anterior cerebral artery with a lumen diameter of 8 mm, an outer wall diameter of 13 mm, and an aspect ratio of approximately 3.4 (fig. 3). The parent vessel (right callosomarginal artery) measured approximately 2 mm in diameter. Because the risk of aneurysm rupture with surgical intervention was considered substantial, an endovascular approach to aneurysm treatment was used. A 3-Fr Excelsior microcatheter (Boston Scientific, Natick, Mass., USA) was placed into the parent artery just beyond the aneurysm neck. A 2 × 3 mm Tornado pushable fibered coil (Cook Inc., Bloomington, Ind., USA) was deployed to occlude the vessel both proximal and distal to the aneurysm and partially filled the lumen (fig. 4). Three more fibered coils were placed proximally to ensure stability. Postembolization angiog-

Copyright © 2004 S. Karger AG, Basel

KARGER

Fax +41 61 306 12 34
E-Mail karger@karger.ch
www.karger.com

© 2004 S. Karger AG, Basel
1016-2291/04/0403-0128\$21.00/0

Accessible online at:
www.karger.com/pne

Kerry R. Crone, MD
c/o Editorial Office, The Neuroscience Institute, Department of Neurosurgery
University of Cincinnati College of Medicine, ML 0515
231 Albert Sabin Way, Cincinnati, OH 45267-0515 (USA)
Tel. +1 513 558 3563, Fax +1 513 558 7702, E-Mail editor@mayfieldclinic.com

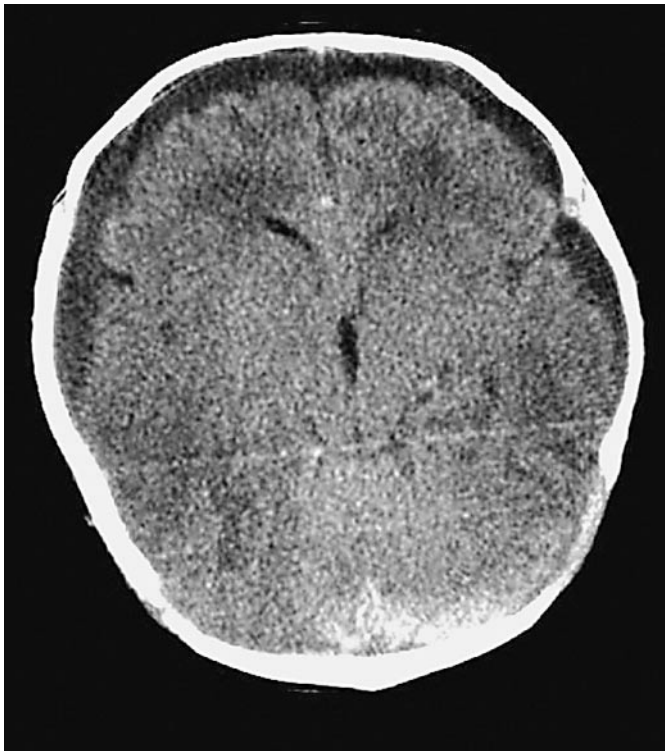

Fig. 1. Noncontrast head CT shows bilateral subdural collections, falcine subdural hematoma, and traumatic subarachnoid hemorrhage (with permission from Mayfield Clinic).

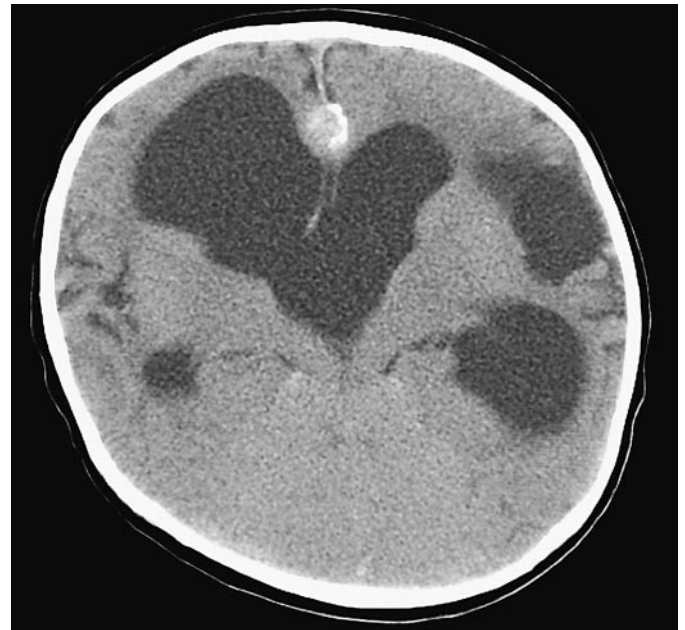

Fig. 2. Noncontrast CT demonstrates obstructive hydrocephalus (with permission from Mayfield Clinic).

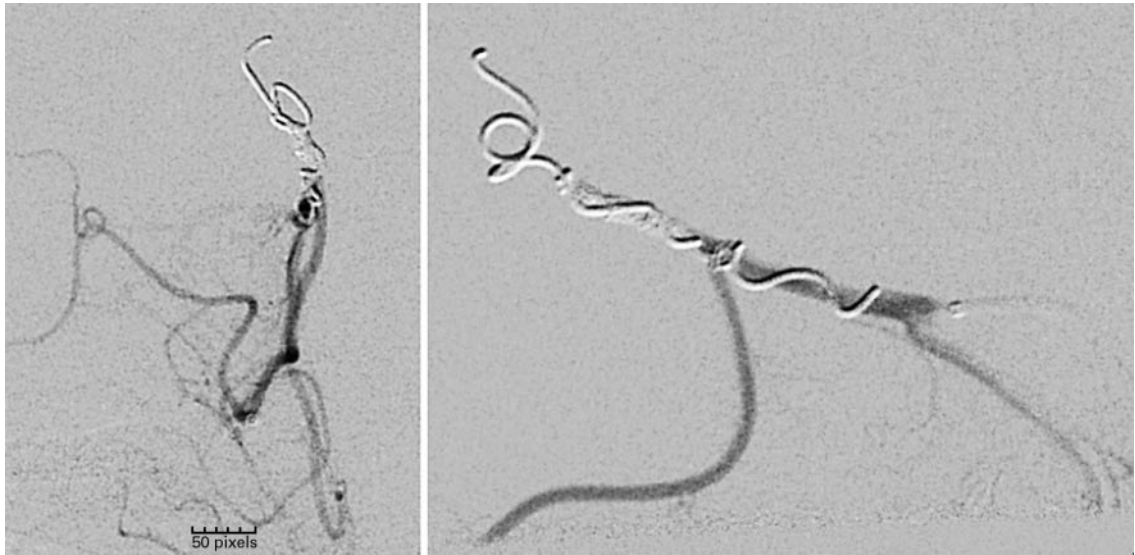
raphy showed complete exclusion of the aneurysm from the vascular system, with good flow to the distal callosomarginal artery via collaterals. The patient tolerated the procedure well, and subsequently underwent an endoscopic third ventriculostomy for treatment of obstructive hydrocephalus (fig. 5). Follow-up MR and MR angiography scans showed a patent ventriculostomy, shrinking of the pseudoaneurysm, and no evidence of increased ventricular size.

Discussion

Traumatic arterial aneurysms comprise less than 1% of all intracranial aneurysms. However, 25–75% of traumatic aneurysms occur in patients 18 years or younger [1, 3, 5] and have been documented to develop in association with shaken baby syndrome [3]. These traumatic aneurysms of the pericallosal region are more distal than congenital aneurysms, which typically occur at the bifurcation of the pericallosal vessels [4]. Nakstad et al. [4] proposed that traumatic pericallosal artery aneurysms result from development of a false wall after a full-thickness vessel tear caused by shearing of the vessel against the falx.

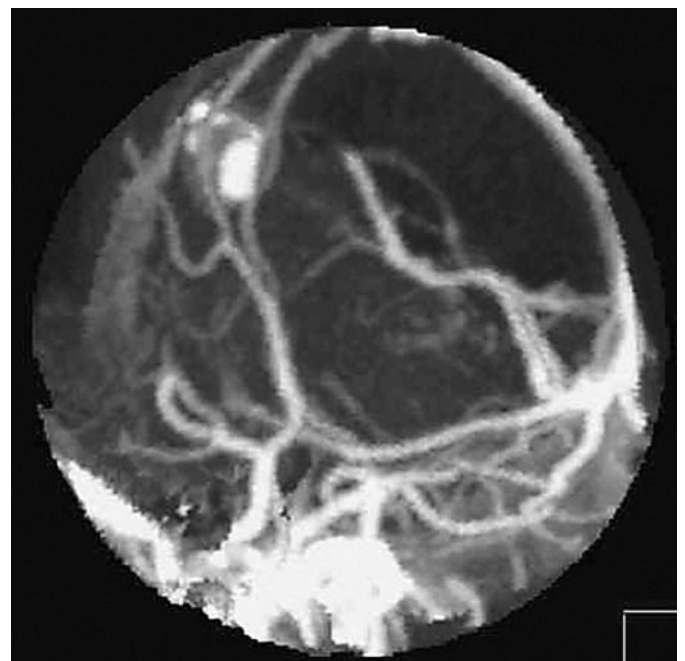

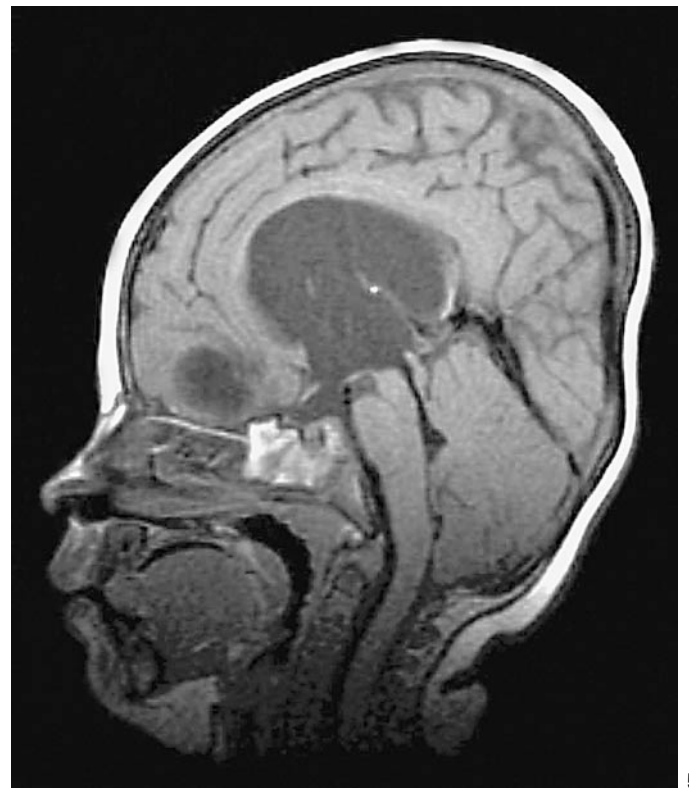Fig. 3. CT angiogram with three-dimensional reconstruction of traumatic pericallosal aneurysm (with permission from Mayfield Clinic).



4

Fig. 4. Anterior-posterior and lateral angiograms show post-coiling occlusion of aneurysm and feeding vessel (with permission from Mayfield Clinic).

Fig. 5. Sagittal FSE MRI sequence demonstrates a hole in third ventricle floor after endoscopic third ventriculostomy (with permission from Mayfield Clinic).



5

Treatment of peripheral artery aneurysms traditionally has consisted of a craniotomy and aneurysm trapping [1, 3, 5].

Based on our review of the literature, our case represents the first use of coiling a traumatic artery aneurysm in an infant. We selected an endovascular approach rather

than craniotomy and aneurysm trapping because of the patient's small size, clinical condition, and hydrocephalus [2]. This technique enabled the elimination of the aneurysm from the vascular tree, and minimized the risk of further hemorrhage due to pressure alterations associated with ventricular decompression. In addition, the patient's

post-traumatic obstructive hydrocephalus was treated with an endoscopic third ventriculostomy. Both techniques minimized the potential of additional injury to the already compromised brain parenchyma, presumably im-

proving the long-term prognosis for recovery. In this case report, we document that minimally invasive radiological and surgical techniques can be used successfully to manage the sequelae of trauma in children.

References

- 1 Buckingham MJ, Crone KR, Ball WS, Tomsick TA, Berger TS, Tew JM Jr: Traumatic intracranial aneurysms in childhood: Two cases and a review of the literature. *Neurosurgery* 1998;22:398–408.
- 2 Jones BV, Tomsick TA, Franz DN: Guglielmi detachable coil embolization of a giant mid-basilar aneurysm in a 19-month-old patient. *Am J Neuroradiol* 2002;23:1145–1148.
- 3 Lam CH, Montes J, Farmer JP, O’Gorman AM, Meagher-Villemure K: Traumatic aneurysm from shaken baby syndrome: Case report. *Neurosurgery* 1996;39:1252–1255.
- 4 Nakstad, P, Nornes H, Hauge HN: Traumatic aneurysms of the pericallosal arteries. *Neuroradiology* 1986;28:335–338.
- 5 Ventureyra EC, Higgins MJ: Traumatic intracranial aneurysms in childhood and adolescence: Case reports and review of the literature. *Child’s Nerv Syst* 1994;10:361–379.
- 6 Yazbak, PA, McComb JG, Raffel C: Pediatric traumatic intracranial aneurysms. *Pediatr Neurosurg* 1995;22:15–19.

Copyright: S. Karger AG, Basel 2004. Reproduced with the permission of S. Karger AG, Basel. Further reproduction or distribution (electronic or otherwise) is prohibited without permission from the copyright holder.

Copyright: S. Karger AG, Basel 2004. Reproduced with the permission of S. Karger AG, Basel. Further reproduction or distribution (electronic or otherwise) is prohibited without permission from the copyright holder.