

Koji Kakishita  
Eri Sekiguchi  
Shinichiro Maeshima  
Hideo Okada  
Ryuji Okita  
Fuminori Ozaki  
Hiroshi Moriwaki

## Stuttering without callosal apraxia resulting from infarction in the anterior corpus callosum

### A case report

Received: 12 May 2003  
Received in revised form:  
18 December 2003  
Accepted: 13 January 2004

Sirs: Stuttering may be defined as a “a deviation of speech which attracts attention or which adversely affects the speaker or listener because of an interruption of the normal rhythm of speech by involuntary repetition, prolongation, or arrest of sound” [3].

Although developmental stuttering is common in childhood, acquired stuttering occurring in adults in association with stroke, trauma, or certain medications is rare. Acquired stuttering shows five important characteristics: lack of an adaptation (training) effect, occurrence mainly but not exclusively with initial syllables, occurrence in grammatical as well as in substantive words, absence of anxiety, and a paucity of associated motor symptoms [6].

Acquired stuttering caused by stroke is uncommon, and its mechanisms are poorly understood. Acquired stuttering has been attributed to stroke involving the supplementary motor area [9], left parietal lobe [12], midbrain and thalamus [1], subcortical [10] and corpus callosum [2, 5, 7, 13]. In pre-

vious reports of acquired stuttering associated with callosal infarction it usually has been associated with callosal apraxia, and with callosal lesions extending from the genu to the entire body (Table 1). We present a patient with acquired stuttering associated with callosal infarction but not apraxia.

A 51-year-old, right-handed man was admitted to the hospital on the day following onset of stuttering. He had 12 years education. He had a history of hypertension and hyperuricemia, but no prior neurological problems including stuttering. His parents, brothers, and sisters all were right handed, and none stuttered. Neurological examination revealed no motor and sensory disturbance. Soft palate and tongue movement were normal. Articulation and prosody were completely normal except for stuttering. The patient stuttered while repeating phrases and with confrontation naming on the examiner's request and while reading aloud. His stuttering was characterized by multiple repetitions and blocking, involving mainly the initial syllables of either grammatical or substantive words. Stuttering occurred with both monosyllabic and polysyllabic words. Repeatedly learned and rhythmical tapping sequences improved his stuttering. The patient scored 25/30 on the mini-mental state examination. On the revised Wechsler Adult Intelligence Scale (WAIS-R), the verbal

Intelligence Quotient (IQ) was 72, performance IQ 87, and full-scale IQ 77.

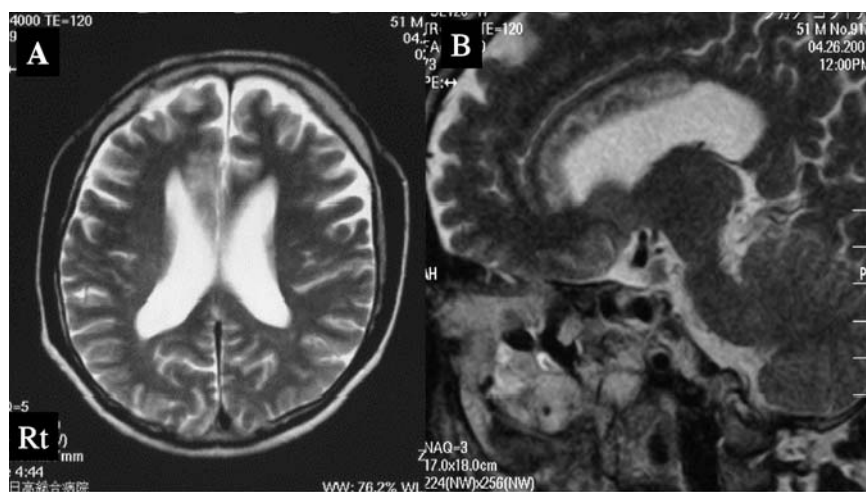
Comprehension of spoken language was good. Buccofacial apraxia and unilateral spatial neglect were absent. Ability to copy a cube with either hand was normal. No ideomotor or ideational apraxia was seen for either hand. MRI of the brain 12 days after admission showed a right-sided infarction in the anterior half of body of the corpus callosum (Fig. 1A, B).

Most patients with acquired stuttering associated with callosal infarction have shown callosal disconnection syndrome, but our patient did not. We therefore retrospectively studied reported MRI findings in these cases. We found that the lesion of acquired stuttering included the body of corpus callosum [2, 5, 7, 13] (Table 1). In particular, the lesion of acquired stuttering with callosal disconnection syndrome tended to be the entire body, especially the posterior portion. The present lesion underlying the stuttering without callosal disconnection syndrome involved only the anterior part of the body and the genu. Mechanisms of acquired stuttering associated with callosal infarction are poorly understood. The left hemisphere generally is the dominant side for language, while the right hemisphere may contribute to processing of prosodic information by way of integrating certain aspect of left

**Table 1** Characteristics of patients with acquired stuttering resulting from callosal infarction

Authors & Year	Age & Sex	Handedness	Clinical findings	MRI (callosal lesion)
Nishikawa, et al. 1986	41, M	Rt	Callosal apraxia	G-B-S
Endo, et al. 1990	56, M	Ambidextrous	Lt hemiparesis	G-B
Tsumoto, et al. 1999	66, M	Rt	Callosal apraxia without agraphia Lt hemiparesis	B-S
Hagiwara, et al. 2000	52, M	Rt	Callosal apraxia without agraphia	B-S
Present case	51, M	Rt	None	G-AB

G genu; B body; AB anterior part of body; S splenium



**Fig. 1** Axial (A) and Sagittal (B) T2-weighted magnetic resonance imaging scan illustrating increased signal in the right anterior part of the corpus callosum

hemispheric output. Synchronizing and coordinating the activities of both hemispheres during speech is probably mediated through inter-hemispheric callosal connections. Several reports have concluded that integrative function most likely occurs via the corpus callosum [4, 10, 11]. Callosal infarction interrupts this interhemispheric pathway. Yet not all cases of callosal infarction are associated with acquired stuttering, so neural circuits affected in callosal apraxia apparently differ from damaged connections in acquired stuttering. In particular, the anterior part of the callosal body may be important in acquired stuttering without other sign of interhemispheric disconnection.

## References

1. Abe K, Yokoyama R, Yorifji S (1992) On stuttering-like hesitation resulting from infarction in the midbrain and the mesial th
2. Endo K, Fukusako Y, Kawamura M, Shiota J, Masaki S, Hirose H (1990) Acquired stuttering associated with callosal infarction. *Onnseigenngoigaku* 31:388–396
3. Espir MLE, Rose FC (1970) The basic neurology of speech. Blackwell Scientific Publication. Oxford and Edinburgh
4. Klouda GV, Robin DA, Graff-Radford NR, Cooper WE (1988) The role of callosal connections in speech prosody. *Brain Lang* 35:154–171
5. Hagiwara H, Takeda K, Saito F, Shimizu T, Bando M (2000) A case of callosal apraxia without agraphia and acquired stuttering associated with callosal infarction. *Clin Neurol* 40:605–610
6. Helm NA, Butler RB, Benson DF (1978) Acquired stuttering. *Neurology* 28: 1159–1165
7. Nishikawa T, Okuda J, Tabushi K, Tanabe H, Shiraishi J, Nishimura T (1986) Hemispheric specialization in elementary auditory perception – A study on a case with callosal infarction. *Higher Brain Function Research* 6:1071–1082
8. Rosenbek JC, Messert B, Collins M, Wertz RT (1978) Stuttering following brain damage. *Brain Lang* 6:82–96
9. Rubens AB (1975) Aphasia with infarction in the territory of the anterior cerebral artery. *Cortex* 11:239–250
10. Soroker N, Bar-Israel Y, Schechter I, Solzi P (1990) Stuttering as a manifestation of right-hemispheric subcortical stroke. *Eur Neurol* 30:268–270
11. Speedie LJ, Coslett HB, Heilman KM (1984) Repetition of affective prosody in mixed transcortical aphasia. *Arch Neurol* 41:268–270
12. Trost JE (1971) Apraxic dysfluency in patients with Broca's aphasia. Paper presented at the American Speech and hearing Convention. Chicago, Ill
13. Tsumoto T, Nishioka K, Nakakita K, Hayashi Y, Maeshima S (1999) Acquired stuttering associated with callosal infarction: a case report. *No Shinkei Geka* 27(1):79–83

K. Kakishita (✉) · H. Okada · R. Okita · F. Ozaki · H. Moriwaki  
Department of Neurological Surgery  
Hidaka General Hospital  
116-2, Sono, Gobo, Wakayama, Japan  
Tel.: +81-738/221111  
Fax: +81-738/227140  
E-Mail:  
kakishita@hidakagh.gobo.wakayama.jp

E. Sekiguchi  
Division of Speech Therapy  
Hidaka General Hospital  
Gobo, Wakayama, Japan

S. Maeshima  
Department of Physical Medicine  
and Rehabilitation  
Wakayama Medical University  
Wakayama, Japan