

## Posterior Alien Hand Syndrome: Case Report and Rehabilitative Treatment

A. Pappalardo, M. R. Ciancio, E. Reggio, and F. Patti

*Alien hand syndrome (AHS) is a rare syndrome characterized by involuntary, uncontrollable, and purposeless movement of one upper limb, which is considered as extraneous by the patient. The term AHS was previously used to describe a syndrome due to lesions in the anterior corpus callosum. Successively, some authors reported cases of AHS in patients due to posterior cerebral lesions, without lesions of the corpus callosum. Thus, it was possible to distinguish the posterior variant of AHS from the anterior form. The authors report an unusual case of posterior AHS due to a unique parieto-occipital lesion of the dominant hemisphere. However, the patient showed clinical findings that were similar to the anterior AHS. The rehabilitative treatment, individualized and targeted toward the specific needs of the patient, allowed the improvement of the patient's participation in activities of daily living.*

Key Words: *Alien hand syndrome—Rehabilitation.*

The alien hand syndrome (AHS) is a condition characterized by involuntary and uncontrollable motor activity of an upper limb, associated with sense of extraneousness of the same limb.<sup>1</sup> Such movements are aimless and differentiable from those choreic and athetotic (mioclonic). Criticism is another specific condition of AHS, in which the patient criticizes the behavior of his affected limb, with a feeling of frustration.<sup>2</sup>

From Dipartimento di Scienze Neurologiche, Università degli Studi di Catania, Italy (AP, ER, FP), and U.O. Medicina Fisica e Riabilitazione, Ospedale Gravina e S. Pietro, Caltagirone, Italy (MRC).

Address correspondence to A. Pappalardo, MD, PhD, Dipartimento di Scienze Neurologiche, Università di Catania, Azienda Policlinico—Edificio 20, Via S. Sofia 78, Catania, Italy. E-mail: pange.bel@virgilio.it.

Pappalardo A, Ciancio MR, Reggio E, Patti F. Posterior alien hand syndrome: case report and rehabilitative treatment. *Neurorehabil Neural Repair* 2004;18:176–181.

DOI: 10.1177/0888439004269031

Initially AHS was used to indicate cases with anterior corpus callosum lesions, determining involuntary movements.<sup>3</sup> Afterward, some authors described other cases of AHS involving lesions of the corpus callosum plus dominant medial frontal cortex<sup>4</sup> and posterior cortical-subcortical areas.<sup>5</sup>

Goldstein first described the syndrome in a discussion of apraxia in 1908.<sup>6</sup> Brion and Jedynak introduced the term “main étrangère” to describe a feeling of foreignness of an arm in patients with lesions of the corpus callosum.<sup>7</sup> Goldberg applied the term to unintended motor actions of the hand opposite to medial frontal lobe lesions.<sup>8</sup>

Actually 3 varieties of AHS are reported:

- 1) AHS provoked by a lesion of the corpus callosum alone, where the most important feature is the intermanual conflict<sup>9</sup>;
- 2) AHS due to a lesion of the dominant medial frontal cortex plus corpus callosum, characterized by compulsive manipulation of tools, associated with grasping and groping signs<sup>10</sup>;
- 3) AHS due to a lesion in cortical region supplied by the right posterior cerebral artery and characterized by stereotyped simple hand.<sup>11</sup>

Further cases with thalamic injury were also described.<sup>12</sup> AHS was due to posterior lesions resulting either from cortico-basal degeneration involving primarily posterior cortical degeneration or from cerebrovascular accidents.<sup>13</sup> In this subtype of AHS movement, disorders are less specific.

The first 2 types of AHS are classified as an “anterior” or “motor” form of AHS, whereas the posterior AHS (PAHS) is also defined as a “sensory” form.

**Table 1.** Neuropsychological Evaluation of Visual-Spatial Cognition and Constructive Abilities

Description of the Task	Number of Errors T0/T1
Length of 10 different lines	8/2
Angle between 2 lines (10 tasks)	8/2
Spatial orientation of 10 lines	7/1
Mental rotation of 10 two-dimensional complex geometric figures	10/3
Identification of 10 complex figures	8/2
Identification of 10 hidden figures	8/2
Mental construction of 10 complex figures	10/3

T0 = start of rehabilitation; T1 = 6 months after start of rehabilitation.

Recently, the term “anarchic hand” has been proposed for unintended actions to distinguish them from the “alien hand” in its original sense.<sup>14</sup>

We report a rare case of AHS due to left parieto-occipital damage from ischemic stroke. However, the clinical findings were typical of the anterior form. We also highlight that in our patient the PAHS involved the dominant limb. Contrarily, the reported cases of PAHS affected the nondominant limb.<sup>5</sup>

## CASE REPORT

MA, male, 60 years old, right-handed, with a high education level, was injured by an ischemic stroke, due to an occlusion of the left posterior cerebral artery. At the hospital, the neurological examination highlighted a moderate right upper motor neuron facial paresis, associated with mild weakness of both upper and lower limbs, Babinski on the right side. Verbal comprehension, repetition, and reading were moderately impaired, as well as object naming to visual and tactile presentation in both the hands.

Initial brain CT without contrast evidenced probable infarct in the left cortical-subcortical parieto-occipital region. Routine blood laboratory data were unremarkable. The electrocardiogram revealed normal sinus rhythm with occasional supraventricular premature beats and a previous inferior wall infarction. Follow-up MRI at 15 days poststroke onset showed low density in the left parieto-occipital gray and white matter, with sparing of the corpus callosum.

Three months after stroke onset, neurological examination highlighted complete recovery of the right facial-brachial-crural hemiparesis; word comprehension, repetition, and reading were normal, as well as object naming to visual and tactile presentation in both the hands.

Examination of the motor behavior revealed the following signs in the right upper arm: unwanted,

uncontrollable, and purposeless motor activity, well distinguishable from other known movement disturbances such as myoclonus, athetosis, chorea, and so on; intermanual conflict; rare involuntary synchronous movements during voluntary unilateral movements of the nonaffected limb; and difficulty releasing objects.

MA did not recognize his right arm and right hand as being part of his own body. Autocriticism toward the affected arm was present too; MA defined his right hand as “handicapped.”

Activities of daily living (ADLs) were severely impaired. MA was unable to use a knife or a fork while eating, dress himself, do up buttons, shave himself, drink a glass of water, catch, and manipulate and release various tools. Also the bimanual coordination was seriously impaired. The total score of a Functional Independence Measure (FIM)<sup>15</sup> was 70/126.

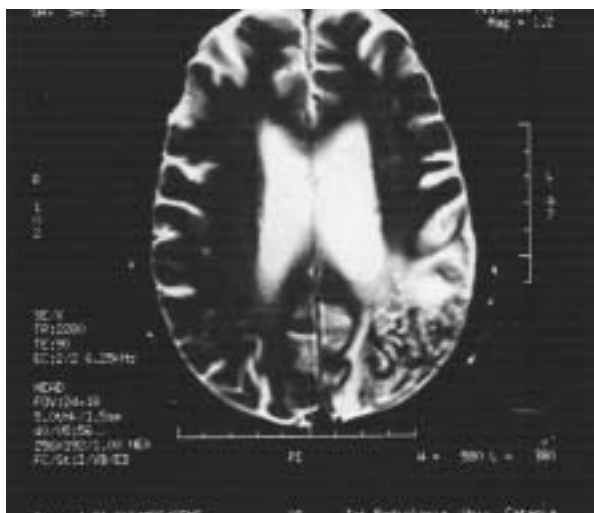
The patient dramatically suffered from his incapability to control his hand. Furthermore, attempts to execute regular repetitive self-paced flexion-extension movements of individual fingers of the right hand resulted in errors of timing and sequencing, which were not observed in the left hand.

A new brain MRI, 3 months postonset, demonstrated a large left cortical-subcortical parieto-occipital ischemic injury (Figure 1). Acoustic P-300 wave with odd-ball paradigm<sup>16</sup> showed a morphologic alteration of P-300 wave and a marked increase in its latency.

The neuropsychological evaluation demonstrated severe impairment of both perception and spatial thought, deficit of visual-spatial cognition, and constructive disorders (Table 1). MA did not evidence neglect in spatial exploration tasks (line and letter cancellation, sentence reading).

The patient was asked to

- 1) measure the length of 10 different lines,
- 2) measure the angle between 2 lines (10 tasks),
- 3) recognize the spatial orientation of 10 lines,



**Figure 1.** Brain NMR, showing a large left parieto-occipital ischemic injury.

- 4) perform the mental rotation of 10 two-dimensional complex geometric figures,
- 5) perform the identification of 10 complex figures,
- 6) perform the identification of 10 hidden figures, and
- 7) perform the mental construction of 10 complex figures.<sup>17</sup>

We started the rehabilitative treatment 3 months after the stroke onset.<sup>18,19</sup> In total, the rehabilitative therapy went on for 6 months, 6 times a week for the 1st month, 3 times a week from months 2 to 6.

As intermanual conflict interfered with intended movements, we initially positioned the affected arm on the patient's back when the patient was away from the rehabilitative setting. In this way, intermanual conflict was inhibited and the patient could use the nonaffected arm in many ADLs. Obviously, the motor training was focused on the affected arm within the rehabilitative setting. Afterward, we gradually encouraged the use of the right arm in some ADLs.

Rehabilitation was planned by the physiatrist in collaboration with the neurologist, the neuropsychologist, the therapist, and members of the patient's family. His family lived in close contact with the patient and provided useful contributions and suggestions on strategies that could be adopted.

The rehabilitation program put active and conscious participation at the forefront. We focused our attention to environmental factors such as the manner in which health care professionals informed the patient and overprotection by family

members and nurses. All the rehabilitative treatment was directed to meet the needs of the patient, who was gradually motivated to use the acquired abilities in his daily activities. At the beginning of therapy, the patient failed to recognize the special position of his limbs while watching the mirror. Such errors were not evident without a mirror. This sign may be due to the impairment of spatial abilities.

We trained the patient to use the temporal sequence assignments with himself (catching a bottle of water, unscrewing the cap, and pouring out the water in a glass), as well as visual feedback, to minimize the intermanual conflict.

The patient regained enough competence in the performance of some therapeutic practices just based on daily activities; in this way, he was gradually able to cut most types of food and use implements with the right hand. Although there was functional improvement, his hand motor behavior was not fluid and was poorly coordinated. We also used a modified pen that, being larger than a normal one, facilitated both handling and pinching movements. MA gradually regained the ability to write with his right hand. The manipulation of tools was performed by wearing gloves; this task was facilitated by handling smooth round tools. In this way, the patient could either catch or release the tools.

Because returning to work constituted a main goal in MA's life, we tried to create a special rehabilitative setting with particular focus on job activities (calling on and answering the telephone, writing for public relations, etc.).

## RESULTS

A new neuropsychological, neurophysiological, and motor examination was performed 6 months after the beginning of rehabilitative therapy.

The patient was still obliged to practice the various tasks feedback with both sustained attention and effort. He managed to identify both complex and hidden figures, as well as measure both length and space orientation. Furthermore, he could carry out the mental construction of complex figures, even if he sometimes failed the mental rotation of bidimensional complex geometric figures (Table 1). The total score of the FIM was 112/126.

The motor examination evidenced the reduction of the involuntary and purposeless activity. Manipulation of tools became less compulsive than at the beginning of rehabilitation; MA was

able to release objects. Even the intermanual conflict had subsided, but the sense of alienness persisted as well as the autocriticism. Nevertheless, the patient was still obliged to practice the various tasks feedback with both sustained attention and effort.

The second electrophysiologic evaluation demonstrated a normalization in either the latency or the morphology of the P-300 wave. As known, the P-300 wave may be considered as a neuropsychophysiologic marker of cognitive process involving attention and skills, generated by the activity of posterior cerebral areas (parietal and occipital lobes mainly).

In the follow-up examination, 24 months after the stroke event, we found neither compulsive manipulation of tools nor intermanual conflict.

Specific rehabilitative treatment had not been executed between 6 months and 2 years after start of the therapy.

## DISCUSSION

We present a rare case of PAHS, unusual because the patient exhibited

- intermanual conflict, which is usually particular to callosal lesion,
- compulsive manipulation and difficulty in releasing tools, which are typical features of a frontal lesion, and
- sense of extraneousness of the right arm and hand, as being part of his own body.

These pathological findings involved the dominant limb.

Our case of PAHS differs substantially from those reported in the literature. Levine and Rinn<sup>20</sup> described a case of PAHS associated with opticosensory ataxia. According to them, alien hand movements are caused from posterior disconnection of the hemisphere, due to right temporo-occipital infarction.

Doody and Jancovic<sup>21</sup> reported a case of a patient with a large right posterior infarct involving the corpus callosum and posterior internal capsule.

Bundick and Spinella<sup>5</sup> issued the case of a woman presenting uncontrolled levitation in the left arm, without intermanual conflict. The lesion was located in the right parietal-temporal-occipital region. They speculated that the sense of estrangement from the nondominant upper limb and its

movements were similarly produced by body schema distortion and hemineglect secondary to the nondominant parietal lobe infarct.

Ay et al.<sup>22</sup> described a case of left AHS, characterized by involuntary movement disorders of primary sensation and sensory processing, due to an infarction in the right thalamus, hippocampus, inferior-medial temporal lobes, and splenium of the corpus callosum. Furthermore, the patient exhibited a combination of sensory, optic, and cerebellar ataxia (triple ataxia).

Pack et al.<sup>23</sup> published a case of PAHS with primary sensory loss and hemispatial neglect, different from our case, because in our patient, primary sensation was spared.

Recently, Rohde et al.<sup>24</sup> reported a case of PAHS involving the dominant right hand. Clinical features consisted of uncontrollable elevation of the right arm, associated with a sense of alienness. MRI showed left central-parietal cortical and subcortical lesions and extensive atrophy of the pre- and postcentral gyri. The authors postulated (as Ay et al.<sup>22</sup>) that the sensation of estrangement was due to a distortion of the body image secondary to the postcentral cortical lesions, even though this phenomenon is usually observed in the nondominant limb. Surely the case described by Rohde is the most similar to ours, even if it differs in anatomical location.

From a clinical point of view, MA's case should be classified as a "motor" or "anterior" form of AHS, despite the fact that both corpus callosum and frontal lobe were not directly involved. The "posterior" form is often characterized by the impairment of the sensitive system, which was spared in our case. In any case, some authors disagree with the classical criteria adopted to correlate clinical aspects with anatomical localization in AHS. According to Jiu-Lech Chan and Ross,<sup>25</sup> the significance of the intermanual conflict as a sign of callosal disconnection is not well validated. But if we consider the clinical and anatomical findings, we can classify our patient as neither posterior or anterior.<sup>21-24</sup> As affirmed by Aboitiz et al.,<sup>26</sup> the above-mentioned categorization might be insufficient to distinguish all clinical forms reported for this syndrome. So Aboitiz et al. recently proposed dividing these syndromes into at least 4 broad categories:

- 1) intermanual conflict and diagnostic dyspraxia, in which one hand (usually the left one) interferes with the movements of the other hand;
- 2) alien hand sign, in which the hand is perceived as extraneous by the patient;

- 3) syndrome of the anarchic hand, which concerns denial of the patient's own intentions for actions of the hand; and
- 4) supernumerary hands, in which the patient complains of feelings of having an extra extremity.

These different forms may coexist in 1 patient. The case of MA may best fit the 1st 2 categories.

However, it is difficult to explain why a parietal-occipital lesion would produce the intermanual conflict. One possible explanation might be an outflow from the parietal cortex into the frontal cortex or fronto-striatal system. For the reasons described above, there is perhaps a potential need to reconsider the correlation between the clinical features and the anatomical localization of AHS.<sup>1</sup>

Literature data on rehabilitative treatment of AHS is lacking. Few authors have addressed this issue. Wu et al.<sup>9</sup> described a potentially effective technique involving biofeedback for patients with AHS. Groom et al.<sup>2</sup> suggested the masking and/or fastening of the affected hand. Pack et al.<sup>23</sup> underlined the excellent prognosis of PAHS, with resolution of associated neurological impairment during the course of rehabilitation.

We proposed a rehabilitative treatment, planned on the real needs of the patient and corroborated by ecological contents. It allowed an evident improvement of the patient's participation in daily living activities. The neuropsychological rehabilitation targeting the selective treatment of both visual-spatial and constructive disorders allowed the recovery of the ability to recognize geometric forms, spatial representation with generalization, and the "transfer" of every reacquired skill in routine daily activities.

The patient achieved a level of complete independence (112/126 FIM score). He returned to work as expected by the rehabilitative aims. He is now completely independent in taking care of himself, but the harmonious flow of the gesture has slowed down.

There was a clear reduction in intermanual conflict, so that the patient could carry out many activities, like writing, dressing, and lifting objects. This recovery was partly due to spontaneous improvement, which usually occurs in the 1st months following stroke onset or a brain injury. Most important, however, the recovery was due to the rehabilitative project, which was based on selective treatment of both the spatial cognition and constructive apraxia disorders. Nevertheless, we were not able to clarify whether the recovery of spatial cognition positively influenced the improvement of motor aspects of AHS. It is tempt-

ing to hypothesize that the severe impairment of bimanual coordination could have taken advantage from the improvement of visual-spatial disorders.

An individualized rehabilitation program targeted to the specific requirements of the patient, aimed either at inhibiting the pathological aspects of AHS (intermanual conflict) or at stimulating the correct manipulation of tools, may be indicated as a possible therapy in AHS.

## ACKNOWLEDGMENTS

The authors wish to thank Prof. Arturo Reggio and Prof. Francesco Le Pira for the precious collaboration.

## REFERENCES

1. Smith Doody R, Jankovic J. The alien hand and related signs. *J Neurol Neurosurg Psychiatry* 1992;55:806-10.
2. Groom KN, Ng WK, Kevortin CG, Levy JK. Ego syntonic alien hand syndrome after right posterior cerebral artery stroke. *Arch Phys Med Rehabil* 1999;80(2):162-5.
3. Suwanwela NC, Leelacheavasin N. Isolated corpus callosal infarction secondary to pericallosal artery disease presenting as alien hand syndrome. *J Neurol Neurosurg Psychiatry* 2002;72(4):533-6.
4. Chan JL, Liu AB. Anatomical correlates of alien hand syndromes. *Neuropsychiatr Neuropsychol Behav Neurol* 1999;12(3):149-55.
5. Bundick LT Jr, Spinella M. Subjective experience, involuntary movement, and posterior alien hand syndrome. *J Neurol Neurosurg Psychiatry* 2000;68(1):83-5.
6. Goldstein K. Zur Lehre von der motorischen Apraxie. *J Psychol Neurol* 1908;11:169-86.
7. Brion S, Jedynak CP. Troubles de transfert interhemispherique (callosal disconnection). A propos de trois observations de tumeurs du corps calleux. Le sign de la main étrangère. *Rev Neurol* 1972;126:257-66.
8. Goldberg G, Mayer NH, Toglia JU. Medial frontal cortex infarction and the alien hand sign. *Arch Neurol* 1981;38:683-6.
9. Wu FY, Leong CP, Su TL. Alien hand syndrome: report of two cases. *Changcheng Yi Xue Za Zhi* 1999;22(4):660-5.
10. Persaud RS. Sensory alien hand syndrome. *J Neurol Neurosurg Psychiatry* 1999;67(1):130-1.
11. Marey-Lopez J, Rubio-Nazabal E, Alonso-Magdalena L, Lopez-Facal S. Posterior alien hand syndrome after a right thalamic infarct. *J Neurol Neurosurg Psychiatry* 2002;73(4):447-9.
12. Gibb WR, Luthert PJ, Marsden CD. Corticobasal degeneration. *Brain* 1989;112:1171-92.
13. Keith RA, Granger CV, Hamilton BB, Sherwin FS. The functional independence measure: a new tool for rehabilitation. *Adv Clin Rehabil* 1987;1:6-18.
14. Marchetti C, Della Sala S. Disentangling the alien and anarchic hand. *Cognit Neuropsychiatr* 1998;3:191-207.
15. Linacre JW, Heinemann AW, Wright BD, Granger C, Hamilton BB. The structure and stability of the functional independence measure. *Arch Phys Med Rehabil* 1994;75:127-32.

16. Pfefferbaum A, Ford JM, Wenegrat BG, Roth WT, Kopell BS. Clinical applications of the P-300 component of event-related potentials. *Norm Aging Electroencephalogr Clin Neurophysiol* 1984;59:85-103.
17. Angelici R, Corra G, Calice C, D'Aurria V, Grossi D. La Terapia Razionale dei Disordini Costruttivi. *Centro di Riabilitazione Neuromotoria S. Lucia – Sezione Ricerca “i quaderni”*, n° 10, appendice 2, Roma 1991.
18. Nudo RJ, Friel KM. Cortical plasticity after stroke: implications for rehabilitation. *Rev Neurol (Paris)* 1999;155(9):713-17.
19. Hallett M. Plasticity of the human motor cortex and recovery from stroke. *Brain Res Rev* 2001;36(2-3):169-74.
20. Levine DN, Rinn WE. Opticosensory ataxia and alien hand syndrome after posterior cerebral artery territory infarction. *Neurology* 1986;36:1094-7.
21. Doody RS, Jancovic J. The alien hand and related signs. *J Neurol Neurosurg Psychiatry* 1992;55:806-10.
22. Ay H, Buonanno FS, Price BH, Le DA, Koroshetz WJ. Sensory alien hand syndrome: case report and review of the literature. *J Neurol Neurosurg Psychiatry* 1998;65(3):366-9.
23. Pack BC, Stewart KJ, Diamond PT, Gale SD. Posterior-variant alien hand syndrome: clinical features and response to rehabilitation. *Disabil Rehabil* 2002;24(15):817-8.
24. Rohde S, Weidauer S, Lanfermann H, Zanella F. Posterior alien hand syndrome: case report. *Neuroradiology* 2002;44(11):921-3.
25. Chan JL, Ross ED. Alien hand syndrome: influence of neglect on the clinical presentation of frontal and callosal variants. *Cortex* 1997;33(2):287-99.
26. Aboitiz E, Carrasco X, Schroter C, Zaidel D, Zaidel E, Lavados M. The alien hand syndrome: classification, of forms reported and discussion of a new condition. *Neurol Sci* 2003;24:252-7.