



ELSEVIER

Parkinsonism and Related Disorders 10 (2004) 429–431

Parkinsonism &  
Related Disorders

[www.elsevier.com/locate/parkreldis](http://www.elsevier.com/locate/parkreldis)

## Unilateral periodic limb movement in sleep after supratentorial cerebral infarction

Suk Y. Kang<sup>a</sup>, Young H. Sohn<sup>a,b,\*</sup>, Il K. Lee<sup>c</sup>, Jin-Soo Kim<sup>a</sup>

<sup>a</sup>*Department of Neurology and Brain Research Institute, Yonsei University College of Medicine, 134 Shinchon-dong, Seodaemun-gu, Seoul 120-752, South Korea*

<sup>b</sup>*Brain Korea 21 Project for Medical Science, Yonsei University College of Medicine, Seoul, South Korea*

<sup>c</sup>*Department of Neurology, Konkuk University College of Medicine, Seoul, South Korea*

Received 24 February 2004; revised 15 April 2004; accepted 17 April 2004

### Abstract

We report a patient with involuntary right leg movements during sleep, which developed after acute ischemic stroke in the corona radiata. Nocturnal polysomnography confirmed the diagnosis of periodic limb movement in sleep (PLMS). Although the pathogenesis of PLMS is still controversial, it has been proposed that the loss of cortical or subcortical inhibition resulting from the pyramidal tract lesion might cause PLMS. The present case provides evidence to support this hypothesis.

© 2004 Elsevier Ltd. All rights reserved.

*Keywords:* Periodic limb movement; Cerebral infarction; Pyramidal tract

### 1. Introduction

Periodic limb movement in sleep (PLMS) is characterized by periodic episodes of repetitive and highly stereotyped limb movements that occur during sleep [1]. Although various conditions, such as uremia, iron deficiency, peripheral neuropathy, radiculopathy, spinal cord and brainstem lesions [2–5], are known to cause PLMS, no case wherein a focal supratentorial infarction was responsible for PLMS has ever been reported. We present a patient in whom PLMS developed after ischemic stroke involving the corona radiata.

### 2. Case report

A 40-year-old right-handed man visited our clinic because of frequent nighttime awakening due to repetitive right leg movements during sleep. He was healthy until one month prior to visiting our clinic, at which time he

developed mild right hemiparesis and dysarthria, followed 7 days later by involuntary right leg movement, repetitive and stereotyped flexion of the ankle and knee, during sleep. He sometimes noticed tingling sensation in his right leg immediately before this movement, when he was falling asleep. The past medical history included hypertension and cigarette smoking, but no sleep disorder. On neurological examination, he still had mild motor weakness (grade IV) of the right extremities without any sensory deficit. Deep tendon reflexes were enhanced with positive Babinski's sign in the right side. Magnetic resonance imaging (MRI) of the brain revealed a small infarct in the left corona radiata (Fig. 1). The results of a magnetic resonance angiogram, routine laboratory tests, electrocardiography and echocardiogram were not remarkable.

Three months later, his arm weakness was nearly recovered, but his leg weakness and involuntary leg movement during sleep still persisted. Nocturnal polysomnography (Fig. 2) revealed that sleep efficiency was as low as 62%. Respiratory disturbance index was normal at 2.9 apneas plus hypopneas per hour, and the average oxyhemoglobin saturation was 97% (the lowest, 89%). The periodic limb movement index was 64 events per hour, and the periodic limb movement arousal index was 6.8 events per hour.

\* Corresponding author. Address: Department of Neurology and Brain Research Institute, Yonsei University College of Medicine, 134 Shinchon-dong, Seodaemun-gu, Seoul 120-752, South Korea. Tel.: +82-2-361-5468; fax: +82-2-393-0705.

E-mail address: [yhsohn62@yumc.yonsei.ac.kr](mailto:yhsohn62@yumc.yonsei.ac.kr) (Y.H. Sohn).

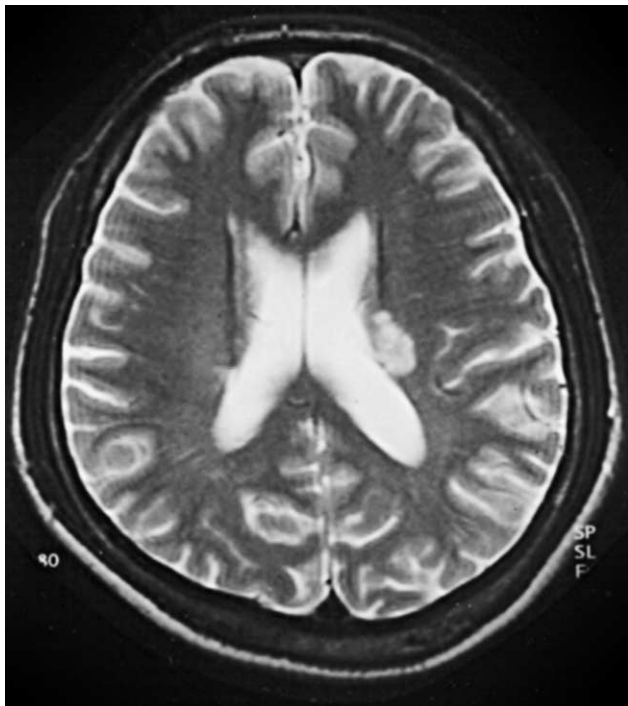

Fig. 1. T2-weighted brain MRI showing an infarction in the left corona radiata.

Levodopa treatment (100 mg, once daily before sleep) resulted in a moderate reduction in this movement. After a two-year follow-up period, his leg weakness was nearly improved, but involuntary leg movements persisted.

### 3. Discussion

The involuntary leg movement in this patient, when considering its clinical presentation, polysomnographic finding and drug response pattern, is quite consistent with PLMS. PLMS is often accompanied with restless leg syndrome (RLS) [1]. This patient sometimes noticed tingling sensation in his right leg before the involuntary leg movements, only when he was falling asleep (i.e. at sleep onset). However, he had no unpleasant sensation while awake, no motor restlessness, and did not know whether this tingling sensation was relieved by the involuntary leg movements. Patients usually do not notice their periodic limb movements in pure PLMS because it occurs during sleep. Thus, this patient may also have mild RLS in addition to PLMS, but do not fulfill the proposed criteria for RLS because of the above mentioned reasons [1]. The possibility of focal motor seizure, i.e. cortical myoclonus, can be excluded by negative electroencephalography during the leg movements and relatively long duration of leg EMG activity. Since PLMS is observed in up to 30% of the general population [4], the development of PLMS in this patient might be coincidental. However, the close temporal relationship between the onset of PLMS and stroke, and unilateral PLMS in the paretic leg support the idea that PLMS in this patient primarily resulted from the ischemic stroke in the corona radiata. In addition, he and his wife did not notice this leg movement before stroke.

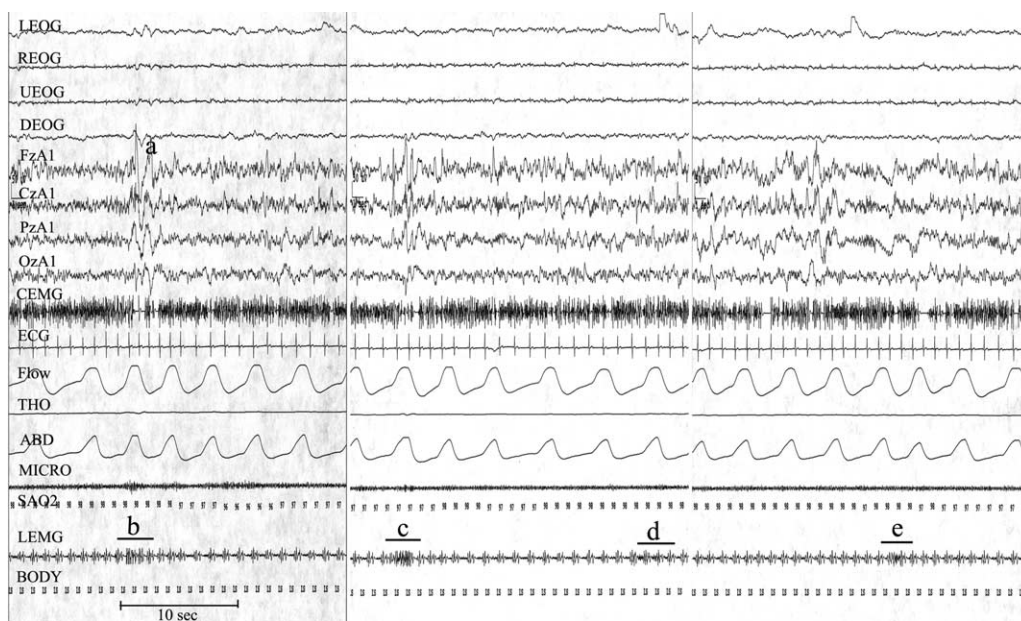


Fig. 2. Polysomnographic recording demonstrated four episodes of periodic leg movements over the course of 90 s. The leg movements were repeated every 22–23 s, and persisted for 3–4 s. K complexes were easily identified (a). Although the electrocardiography artifacts were intermixed with leg EMG recording, the leg EMG activity related to PLMS is nevertheless recognizable (b–e). LEOG, left electrooculogram; REOG, right electrooculogram; UEOG, upward electrooculogram; DEOG, downward electrooculogram; FzA1, CzA1, PzA1, OzA1, four channels of electroencephalogram; CEMG, chin EMG; Flow, nasal airflow; THO, thoracic movements; ABD, abdominal movements; Micro, snore microphone; SAO2, oxyhemoglobin saturation by pulse oximetry; LEMG, right tibialis anterior electromyogram.

The pathogenesis of PLMS has not yet been clarified. The association of PLMS with wide range of conditions makes it difficult to establish a single mechanism. Considering its relationship to sleep, the generator of PLMS is presumed to be associated with sleep-related structures such as the reticular activating system. This assumption was confirmed by a functional MRI study which pointed to the reticular structure in the brainstem as the primary generator of PLMS [6]. Unilateral PLMS associated with lesions near the brainstem reticular formation provides additional evidence to support the role of this structure in generating PLMS [5]. The involuntary leg movements observed in PLMS is similar to Babinski's sign, which is usually observed in the case of a pyramidal tract lesion. In addition, PLMS occurs preferentially during non-REM sleep, in which the nocturnal Babinski's sign is normally observed [7]. Unilateral PLMS has been observed in the symptomatic limbs of the patients with corticobasal degeneration, in whom the pyramidal tract is progressively degenerated [8]. With the above observations, it has been proposed that PLMS is the result of a pyramidal tract lesion, in which the loss of cortical or subcortical inhibition exerting on the brainstem generator might cause PLMS [7,8]. The present case provides additional evidence to support this hypothesis.

In this patient, PLMS persisted after complete recovery of leg weakness. However, recovery of motor weakness does not directly indicate that pyramidal tract is functionally intact. Various upper motor neuron signs including Babinski's sign often persist after complete recovery of motor weakness. It is unclear why PLMS is not often observed in patients with this type of cerebral infarction. There could be either individual variation in susceptibility

of the brainstem generator or under-recognition of PLMS in the presence of motor weakness and spasticity. The mechanisms of secondary PLMS should be multiple considering the fact that various lesions in the brainstem, spinal cord and cerebrum cause PLMS [2,3,5,8]. Therefore, any lesion influencing either the brainstem generator or its downstream pathway can cause PLMS. The pyramidal tract lesion with loss of inhibition exerting on the brainstem generator may be one of these mechanisms.

## References

- [1] Hening W, Allen R, Earley C, Kushida C, Picchiotti D, Silber M. The treatment of restless legs syndrome and periodic limb movement disorder: an American Academy of Sleep Medicine Review. *Sleep* 1999;22:970–99.
- [2] Lee MS, Choi YC, Lee SH, Lee SB. Sleep-related periodic leg movements associated with spinal cord lesions. *Mov Disord* 1996;11:719–22.
- [3] Noguez M, Cammarota A, Leiguarda R, Rivero A, Pardal A, Encabo H. Periodic limb movements in syringomyelia and syringobulbia. *Mov Disord* 2000;15:113–9.
- [4] Trenkwalder C. Restless legs syndrome and periodic limb movements. *Adv Neurol* 2002;89:145–51.
- [5] Kim JS, Lee SB, Park SK, Han SR, Kim YI, Lee KS. Periodic limb movement during sleep developed after pontine lesion. *Mov Disord* 2003;18:1403–5.
- [6] Bucher SF, Seelos KC, Oertel WH, Reiser M, Trenkwalder C. Cerebral generators involved in the pathogenesis of the restless legs syndrome. *Ann Neurol* 1997;41:639–45.
- [7] Smith RC. Relationship of periodic movements in sleep (nocturnal myoclonus) and the Babinski sign. *Sleep* 1985;8:239–43.
- [8] Iriarte J, Alegre M, Arbizu J, de Castro P. Unilateral periodic limb movements during sleep in corticobasal degeneration. *Mov Disord* 2001;16:1180–3.