

Sinking Skin Flap Syndrome

A Case of Improved Cerebral Blood Flow After Cranioplasty

Tsukasa Isago, MD, Motohiro Nozaki, MD,* Yuji Kikuchi, MD,* Takashi Honda, MD,* and Hiroaki Nakazawa, MD†*

Abstract: Sinking skin flap syndrome is defined as a series of neurologic symptoms with the skin depression at the site of cranial defect, which develop several weeks to months after large external cerebral decompression.

The case of a 28-year-old female with the sinking skin flap syndrome is reported together with the evaluation of cerebral blood flow using xenon computed tomography (CT). Although her general condition stabilized within 7 months after the injury, the skin of the bilateral temporal regions was markedly depressed due to large bone defects. She was confined to bed and showed reduced levels of consciousness. We decided to treat this case by performing cranioplasty with a hydroxyapatite ceramic implant. Not only were good cranial contour reconstructed after cranioplasty, but neurologic conditions were also improved after cranioplasty.

Regarding the change in cerebral blood flow in the present case, as measured with xenon CT, the cerebral blood flow 3 days after the injury was 18.7 ± 12.3 mL/100 mL/min and 26.5 ± 11.6 mL/100 mL/min in the left and right hemispheres, respectively. After the bilateral cranioplasty, it had increased by approximately 2-fold to 36.4 ± 23.2 mL/100 mL/min in the left hemisphere and approximately 1.5-fold to 43.8 ± 23.3 mL/100 mL/min in the right hemisphere as compared with the levels obtained 3 days after the injury.

Therefore, xenon CT appears to be useful in the monitoring of regional cerebral blood flow in patients with cranial bone defects that are directly affected by atmospheric pressure and in predicting functional prognosis. For the sinking skin flap syndrome cases, cranioplasty is not only useful for cerebral protection and improvement of appearance, but cranioplasty is also useful for improving neurologic symptoms.

(Ann Plast Surg 2004;53: 288–292)

Received October 9, 2003 and accepted for publication, after revision, December 31, 2003.

From the *Department of Plastic and Reconstructive Surgery, Tokyo Women's Medical University, Tokyo, Japan; and the †Department of Plastic and Reconstructive Surgery, National Disaster Medical Center, Tokyo, Japan.

Reprints: Tsukasa Isago, MD, Department of Plastic and Reconstructive Surgery, Tokyo Women's Medical University, 8-1 Kawada-cho, Shinjuku-ku, Tokyo, Japan 162-8666. E-mail: isago@prs.twmu.ac.jp

Copyright © 2004 by Lippincott Williams & Wilkins

ISSN: 0148-7043/04/5303-0288

DOI: 10.1097/01.sap.0000106433.89983.72

Sinking skin flap syndrome (SSFS) is defined as serious disabling neurologic deficits and impairment of the general status with concave deformity and relaxation of the skin flap, which develop several weeks to months after large craniectomy^{1,2}. In general, large cerebral decompression is performed to reduce high intracranial pressure. The cranial defect produced by large craniectomy is directly affected by atmospheric pressure. As cerebral swelling improves, the skin at the cranial defect gradually sinks due to atmospheric pressure to deform cerebral tissue. The neurologic symptoms of SSFS include headache, vertigo, tinnitus, fatigue, loss of concentration, loss of memory, depression, dysphagia, apraxia, paresis of extremities, and convulsions. This paper reports the case of large cranial bone defect, which was treated with large hydroxyapatite ceramic implant. Also included are the improved neurologic symptoms of SSFS by cranioplasty and the evaluation of cerebral blood flow using xenon computed tomography (CT).

CASE REPORT

A 28-year-old female was hospitalized at an emergency care center with bruising over her whole body and consciousness disorder because she jumped out of a fourth floor window. On admission, she had a consciousness level of coma and unequal pupils (right > left). She also had severe head injuries, depressed skull fracture, pelvic, and vertebral fractures, and open fracture of the toes of her right foot. Since a head CT revealed intracerebral and subarachnoid hemorrhage, an emergency bilateral cranial decompression to remove hematoma was performed by a neurosurgeon. The right surgical site was then incised for drainage and debridement due to infection. Although her general condition stabilized within 7 months, the skin of the bilateral temporal regions was markedly depressed due to large bone defects (Fig. 1). She was bedridden with neurologic symptoms, such as loss of concentration, loss of memory, depression, dysphagia, and paresis of extremities. Although her eyes were open, she did not speak at all. She was under nutritional control with tube feeding. Simultaneous bilateral cranioplasty was considered; however, it was considered that the procedure might result in

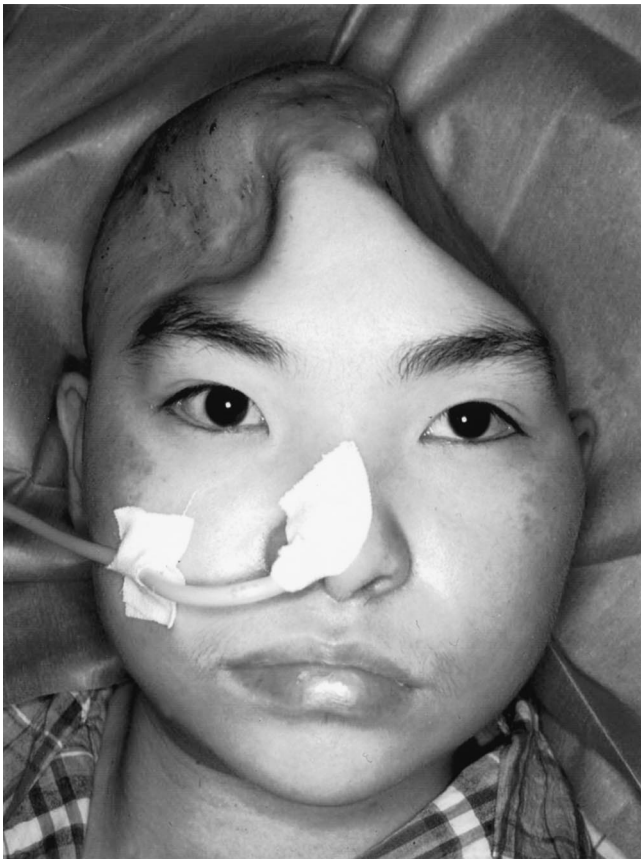

FIGURE 1. Seven months after the removal of hematoma by bilateral cranial decompression.

a shortage of cranial skin because the size of the left and right bone defects was as large as 13 x 8 cm and 8 x 5 cm, respectively. It was thus decided that cranioplasty be per-

formed in 2 stages and initiated from the left side because of the larger size of the bone defect on that side. A bone defect model was prepared from head CT images and modified so that it would include the thickness of the temporal muscle. A hydroxyapatite ceramic implant was prepared using this model, which was used for the cranioplasty for the left bone defect (Fig. 2A and B). The surgery was cooperatively performed under general anesthesia by a plastic surgeon and a neurosurgeon. To avoid suturing the skin flap just over the implant, the incision was made slightly outside the scar from the previous craniectomy, the skin and the dura were detached carefully, and the area of cranial bone defect was completely exposed and complete hemostatic control was gained. The prepared hydroxyapatite ceramic implant was then inserted. Since the hydroxyapatite ceramic implant fit the bone defect, modification of the shape of the implant was unnecessary. At that time, the dura was raised and fixed in place by using a hole created in the center of the hydroxyapatite ceramic implant, with the implant itself fixed to the surrounding bone with silk thread twine. Extradural and subcutaneous drains were then inserted, and the skin was sutured to complete the procedure, which took approximately 3 hours and during which the volume of blood loss was only 200 mL. Depression improved around 2 weeks postoperatively. The training of oral intake of food relieved dysphagia and incorrect deglutition, allowed her to feed herself using a spoon, and eliminated the need for tube feeding. She also became able to perform smoothly coordinated actions of the upper extremities, such as changing her pajamas and doing up buttons. Although she could not walk because of paralysis of the lower extremities due to pelvic fracture and lumbar vertebra pressure fracture, she became able to move using a wheelchair. Thus, general improvement of her neurologic

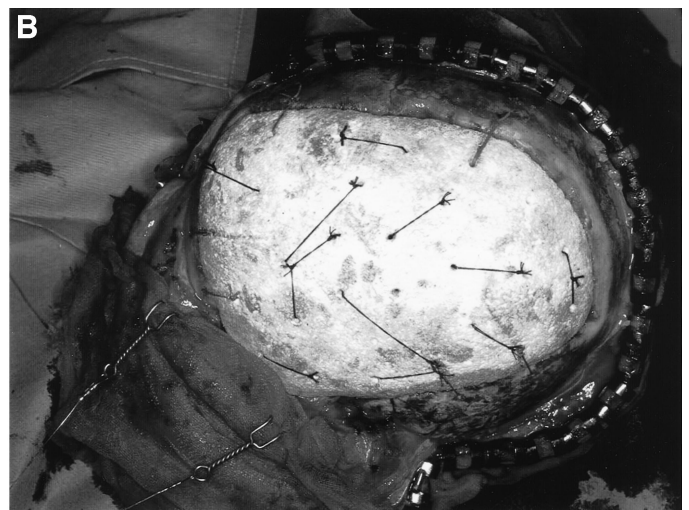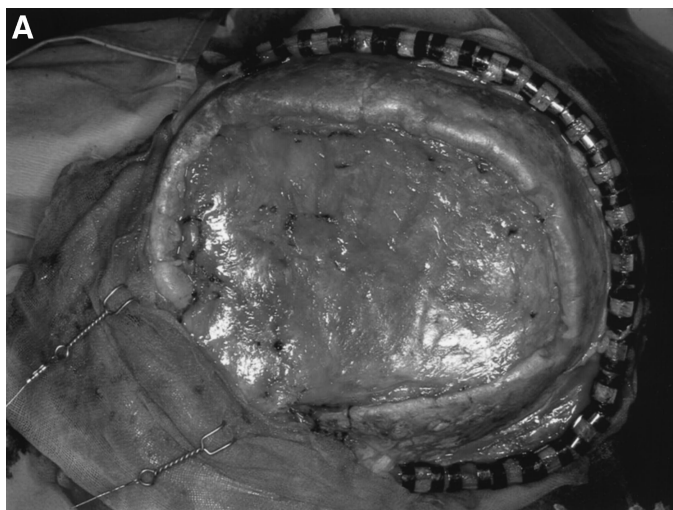


FIGURE 2. A, Cranial bone defect on the left temporal region. B, Hydroxyapatite ceramic implant fit the cranial bone defect.

symptoms was observed postoperatively. However, she remained expressionless and speechless, despite becoming able to understand easy words. A hydroxyapatite ceramic implant for the right cranial defect was prepared in the same manner as for the left cranial defect. The cranioplasty of the right cranial defect was performed 4 months after the first cranioplasty. After the cranioplasty for the right cranial defect was completed, she gradually began smiling and started to laugh aloud. Neurologic symptoms observed preoperatively, such as loss of concentration, loss of memory, depression, dysphagia, and paresis of extremities, started to improve around 2 weeks postoperatively. Dysphagia and incorrect deglutition disappeared within 2 months postoperatively, and the patient was able to feed herself using a spoon and was able to perform coordinated actions using the upper extremities, such as changing her pajamas and doing up buttons. Further, she was able to speak an increasing number of words, said her name, repeated words given to her, and sang songs, although she could not speak a word 1 month after the right cranioplasty (Fig. 3).

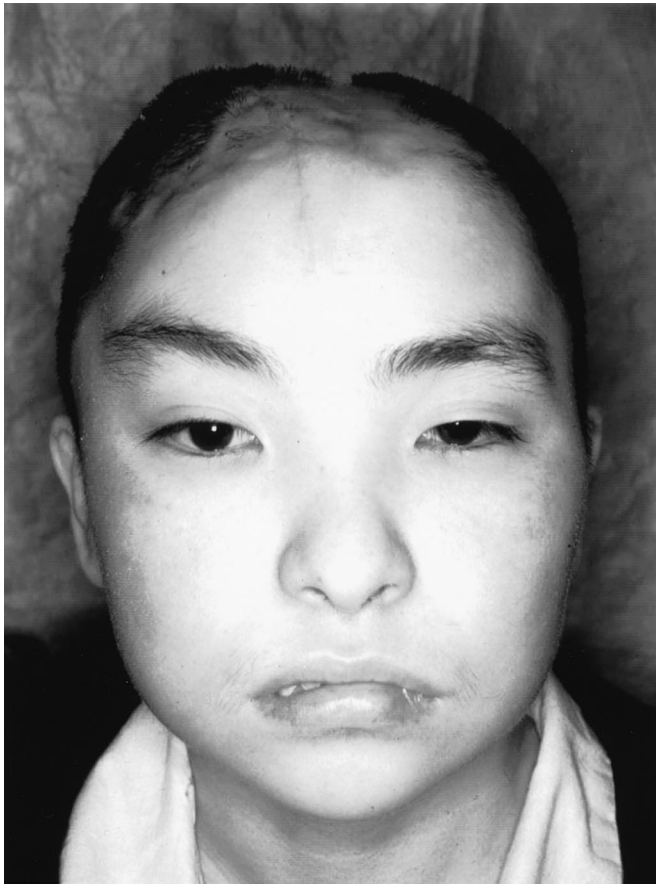

FIGURE 3. Eight months after left cranioplasty and 4 months after right cranioplasty.

Xenon CT was performed to measure cerebral blood flow 3 days after the injury, before the left cranioplasty, after the left cranioplasty (before the right cranioplasty), and after the right cranioplasty. The cerebral blood flow at 3 days after the injury was 18.7 ± 12.3 mL/100 mL/min and 26.5 ± 11.6 mL/100 mL/min in the left and right hemispheres, respectively (Fig. 4A). It was slightly increased to 26.1 ± 19.5 mL/100 mL/min in the left hemisphere but remained the same at 28.3 ± 18.5 mL/100 mL/min in the right hemisphere at 8 months after the injury (just before the left cranioplasty; Fig. 4B). At 1 week after the left cranioplasty, it was 24.8 ± 15.3 mL/100 mL/min and 34.8 ± 20.3 mL/100 mL/min in the left and right hemispheres, respectively (Fig. 4C). At 3 months after the right cranioplasty, it had increased by approximately 2-fold to 36.4 ± 23.2 mL/100 mL/min in the left hemisphere and approximately 1.5-fold to 43.8 ± 23.3 mL/100 mL/min in the right hemisphere as compared with the levels obtained 3 days after the injury (Figs. 4D and 5).

DISCUSSION

SSFS is defined as a series of neurologic symptoms with the skin depression at the site of cranial defect, which develops several weeks to months after large external cerebral decompression. Yamaura and Makino¹ and Yamaura et al² proposed SSFS in 1977 when they reported that some patients with a depressed skin flap after external cerebral decompression showed improved neurologic symptoms after cranioplasty to correct tissue deformation under the flap. SSFS is characterized by the rapid improvement of neurologic symptoms after cranioplasty.

The mechanism of SSFS has been considered to be as follows: large cranial decompression is generally performed to reduce high intracranial pressure, and the cranial defect produced by craniotomy is directly affected by atmospheric pressure; as cerebral swelling improves, the skin at the cranial defect gradually sinks due to atmospheric pressure to deform cerebral tissue, resulting in local cerebral circulation disorder and cerebral dysfunction.^{3,4} However, few studies have reported SSFS. In particular, none has reported the change in cerebral blood flow in patients with SSFS after cranioplasty, as measured using xenon CT. The increased blood flow observed in the present case may support the mechanism.

Xenon CT is a new diagnostic technique in which head CT is performed under the inhalation of xenon gas to measure cerebral blood flow by determining the concentration of xenon in cerebral tissue.^{5,6} Estimation of cerebral blood flow by noninvasive xenon CT has been used to identify blood-flow thresholds for the development of irreversible ischemia following severe head injury or stroke. It is expected that xenon CT technology will play a major role in severe head injury or stroke research. The concentration in cerebral tissue is color-coded on the monitor: the highest blood flow is expressed in blue, followed by green and yellow, and the

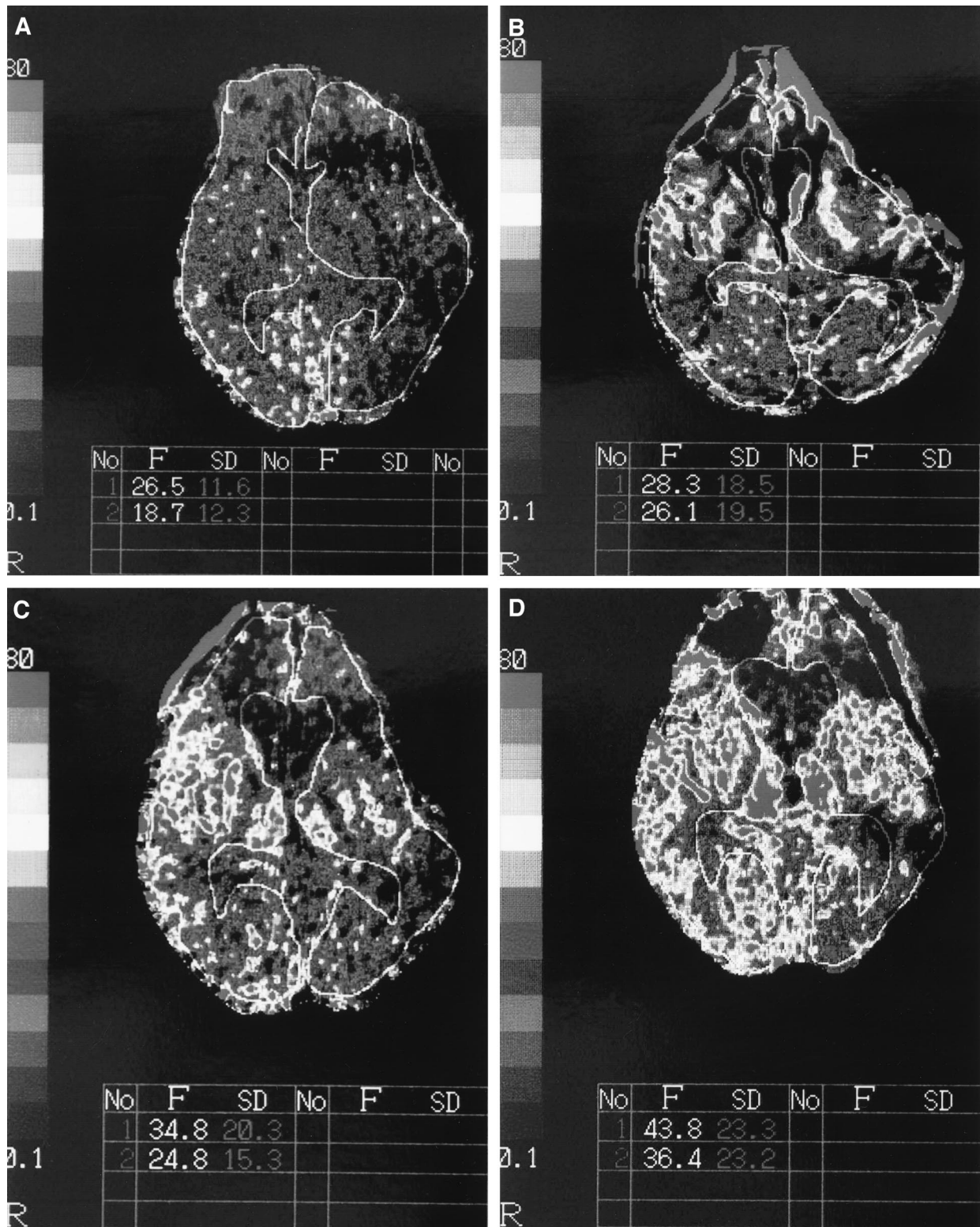


FIGURE 4. A, Xenon CT image taken 3 days after the injury and removal of hematoma by bilateral cranial decompression. The high blood flow is expressed in light color and the low blood flow is expressed in dark color in this images. B, Xenon CT image before left cranioplasty. C, Xenon CT image after left cranioplasty and before right cranioplasty. D, Xenon CT image after right cranioplasty.

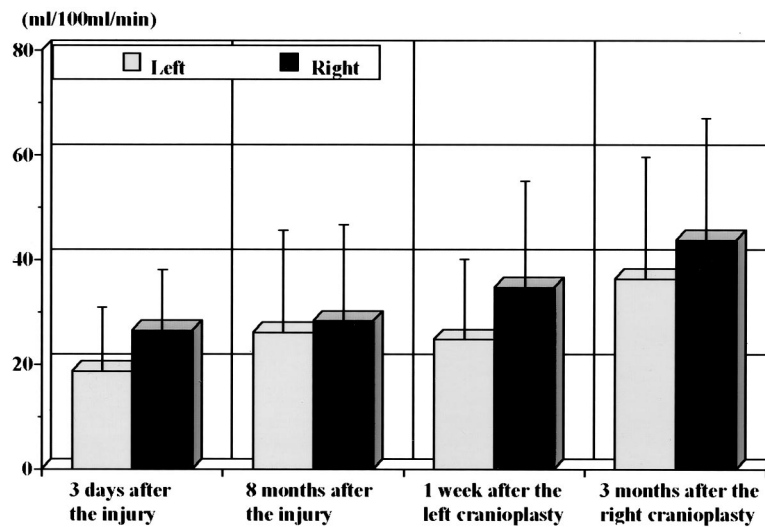


FIGURE 5. Change in the cerebral blood flow. The flow was increased after the bilateral cranioplasty. Values are means \pm SD.

lowest blood flow is expressed in red. Regarding the change in cerebral blood flow in the present case, as measured with xenon CT, the cranioplasty of the left cranial defect alone increased cerebral blood flow. The flow was further increased after the cranioplasty for the right cranial defect was completed. These findings were consistent with the improvements in her clinical symptoms. These results indicate that the cerebral blood flow measurement using xenon CT can be a good monitor for determining the effects of atmospheric pressure on cerebral circulation at external decompression, indication of cranioplasty, and prognosis of SSFS.

Conventionally, treatment of small cranial bone defects caused by trauma or neurosurgery has involved autogenous bone grafting of the outer layer of the cranium or the iliac bone. For larger defects, resin still has been used for cranioplasty. However, the poor biocompatibility of the resin and the occurrence of infection have frequently necessitated post-operative removal of the resin. In contrast, hydroxyapatite has a high degree of biocompatibility and stability in vivo, and its safety and effectiveness have been confirmed in animal experiments and in clinical settings. When performing cranioplasty on this case, the general condition of the patient is poor and surgical invasion must be minimized. As demonstrated here, procedures that use hydroxyapatite ceramic implants are advantageous in such cases because operating times are short, and patients quickly become ambulant because of the exclusion of bone harvesting.

Since cranioplasty has been discussed in terms of cerebral protection and improvement of appearance, it has been considered that cranioplasty is not indicated in patients with serious neurologic symptoms or in bedridden patients. However, cranioplasty may be useful for improving neurologic symptoms and should therefore be performed in such patients.

CONCLUSIONS

This paper reports the case whose neurologic symptoms of SSFS were improved by cranioplasty. The cerebral blood flow of the present case, as determined using xenon CT, was increased after cranioplasty. For SSFS cases, cranioplasty is not only useful for cerebral protection and improvement of appearance, but cranioplasty is also useful for improving neurologic symptoms.

ACKNOWLEDGMENTS

We would like to extend deep thanks to Yoshio Takasato, MD, Director General of the Department of Neurosurgery, National Hospital Tokyo Disaster Medical Center, and other staff physicians for their cooperation. We are grateful to Lillian D. Traber for her assistance in the preparation of the manuscript.

REFERENCES

1. Yamaura A, Makino H. Neurological deficits in the presence of the sinking skin flap following decompressive craniectomy. *Neurol Med.* 1977;17:43–53.
2. Yamaura A, Sato M, Meguro K, et al. Cranioplasty following decompressive craniectomy: analysis of 300 cases. *Neurol Surg.* 1977;5:345–353.
3. Nakamura T, Takashima T, Isobe K, et al. Rapid neurological alteration associated with concave deformity of the skin flap in a craniectomized patient: case report. *Neurol Med.* 1980;20:89–93.
4. Stula D. The problem of the “sinking skin-flap syndrome” in cranioplasty. *J Maxillofac Surg.* 1982;10:142–145.
5. Suzuki R, Nariai T, Hirakawa K. Measurement of cerebral blood flow by stable xenon-enhanced computed tomography. *Neurol Surg.* 1993;21:197–203.
6. Gur D, Good WF, Wolfson SK Jr., et al. In vivo mapping of local cerebral blood flow by xenon-enhanced computed tomography. *Science.* 1982; 215:1267–1268.