

Most paraneoplastic syndromes associated with neuroblastoma have been reported in young children with cerebellar ataxia, myoclonus, and opsoclonus. ANNA-1 antibodies are usually present in patients with small cell carcinomas and paraneoplastic gastroparesis but have not been previously reported in association with neuroblastoma and autonomic dysfunction.^{3,4} Although new antibodies continue to be reported in association with paraneoplastic neurological disorders, the majority of patients with subacute onset of autonomic failure or gastrointestinal dysmotility are considered idiopathic. The most specific marker autoantibody recognised so far is directed at postsynaptic acetylcholine receptors in autonomic ganglia, and was not detected in our patient.⁴

We suspect that the primary mechanism for her severe postural hypotension was baroreflex failure resulting in increased, rather than decreased, basal efferent sympathetic activity. Baroreflex failure refers to loss of inhibitory feedback from the arterial baroreceptors to the brainstem. The baroreflexes are the most important mechanism for maintaining blood pressure during rapid changes in posture and central blood volume. Baroafferents may be damaged in the periphery (for example, arterial baroreceptors during carotid endarterectomy) or, as we suspect in this patient, the central nervous system where they enter the superior medulla.⁵ We hypothesise that baroreflex failure caused severe postural hypotension by two mechanisms: firstly, the immediate vasoconstrictor and AYP responses to changes in central blood volume were decreased; and secondly, increased sympathetic activity at rest mediated chronic splanchnic vasoconstriction and decreased venous capacitance. This caused decreased venous return and an exaggerated fall in cardiac output in response to upright posture. Efferent sympathetic failure was unlikely because MSNA activity was increased at rest and increased normally (with resulting hypertension) during the diving reflex. The diving reflex is mediated by increased sympathetic output from the medulla in response to trigeminal sensory (as opposed to baroafferent) pathways.

Acknowledgements

We are grateful for the assistance of Professor Vanda A Lennon, Mayo Clinic, Rochester, MN who undertook paraneoplastic autoantibody screening and identified the ANNA-1 antibody. Dr Carina Miles reported the tumour biopsy. The figure was prepared by The Department of Medical Illustration, Christchurch Hospital, New Zealand.

D L Jardine

Department of General Medicine, Christchurch Hospital, Christchurch, New Zealand

C P T Krediet

Academic Medical Center, Amsterdam, The Netherlands

B A Robinson

Department of Oncology, Christchurch Hospital, Christchurch, New Zealand

Correspondence to: D L Jardine, General Medicine Department, Private Bag 4710, Christchurch Hospital, Christchurch, New Zealand; david.jardine@cdhb.govt.nz

doi: 10.1136/jnnp.2003.034827

References

- 1 Valbo AB, Hagbarth KE, Torebjork HE, *et al.* Somatosensory, proprioceptive, and sympathetic activity in human peripheral nerves. *Physiol Rev* 1979;59:919-57.
- 2 Jardine DL, Mellon IC, Crozier IG, *et al.* Decrease in cardiac output and muscle sympathetic activity during vasovagal syncope. *Am J Physiol Heart Circ Physiol* 2001;282:H1804-9.
- 3 Darnell RB, Posner JB. Paraneoplastic syndromes involving the nervous system. *N Engl Med J* 2003;349:1543-54.
- 4 Lee H, Lennon VA, Camilleri M, *et al.* Paraneoplastic gastrointestinal motor dysfunction: clinical and laboratory characteristics. *Am J Gastroenterol* 2001;96:373-9.
- 5 Fagius J, Wallin BG, Sundlof G, *et al.* Sympathetic outflow in man after anaesthesia of the glossopharyngeal and vagus nerves. *Brain* 1985;108:423-38.

Acquired ocular motor apraxia from bilateral frontoparietal infarcts associated with Takayasu arteritis

The relatively rare syndrome of acquired ocular motor apraxia is characterised by difficulty in initiating saccades to command and to visual targets, usually in all directions.¹

Case report

Our patient was a 52 year old left handed and non-literate man. He was admitted to a local hospital with the complaint of acute and persistent thoracic and epigastric pain radiating to his back. Five days later he developed acute loss of consciousness and was sent to our hospital.

Blood pressure was 170/100 mm Hg from the right arm and 160/100 mm Hg from the left, the right femoral artery was pulseless, and the epigastric was painful on palpation. He was stuporose, disoriented, and his cooperation was limited to simple commands only. He had bilateral ptosis with his eyes fixed in the primary position. Convergence was absent. However, an oculocephalic reflex could be elicited in both vertical and horizontal directions. His left nasolabial sulcus was somewhat reduced. He had paresis of both his arms and his left leg, while the motor strength in his right leg was almost completely normal. Hoffman and Babinski signs were positive on the left side, with hyperreflexia. The tendon reflexes were normal on the right side and no pathological reflexes were elicited. He had urinary incontinence.

On the third day of admission he appeared apathetic. Although his thinking was slowed, and his affect was flattened, he could answer simple questions and obey simple commands. He still had difficulty in understanding complex orders. His ptosis had resolved but the hypertonia in the left upper extremity was more pronounced. His eyes were still fixed in the primary position.

In the following few days, when he was no longer stuporose, he was observed to execute spontaneous eye movements in all directions without associated head movements, but he was unable to carry out any eye movements when he was instructed to gaze at an object. He was also unable to execute pursuit movements, and there was no optokinetic nystagmus response. On bedside examination, optokinetic nystagmus was tested for by rotating a drum vertically and horizontally before his eyes. Foveal smooth pursuit was tested by asking the patient to follow the

movement of a target light produced by a light source. Examination of the visual fields with confrontation was normal. He also had no visual extinction. Two months after admission, the patient was transferred to a rehabilitation centre, showing full cooperation and orientation and with his eye movements partly recovered. He had no anosognosia or right-left disorientation. His muscle strength had only mildly improved and he had severe hypertonia in his paretic extremities, with clonus of the left leg. A month later he was discharged from the rehabilitation centre without any eye movement abnormality. The oculocephalic reflexes were spared throughout the course of the illness.

Blood studies showed a leucocytosis (14 600 WBC/mm³) and an inflammatory reaction (erythrocyte sedimentation rate 124 mm/h, C reactive protein 110 mg/l). Cranial computed tomography (CT) showed hypodense lesions of cortical grey matter at the level of both cerebral convexities. Cranial magnetic resonance imaging (MRI) showed subacute infarcts involving the cortical grey matter of both frontal and parietal border zone areas bilaterally. The frontal eye field (FEF, at the intersection of the precentral sulcus and the superior frontal sulcus) and the parietal eye field (PEF, in the posterior part of the intraparietal sulcus) were involved bilaterally (fig 1A), whereas both supplementary eye fields (SEF, in the medial wall of the superior frontal gyrus) were spared (fig 1A). Coronal section through the parietal lobe revealed that the intraparietal sulcus (PEF) was involved, whereas the posterior cingulate cortex (PCC) was spared (fig 1B). Three dimensional time of flight magnetic resonance angiography (MRA) showed no abnormality of the cerebral vessels. Contrast enhanced MRA revealed irregularity of the vessel wall beginning from the aortic arch and extending the abdominal aorta (fig 1C). Cutaneous biopsy from the abdomen supported a diagnosis of vasculitis. The patient was diagnosed as having Takayasu arteritis.

Comment

The case is a good example of "acquired" ocular motor apraxia. It appears that both frontal eye fields of the patient were affected by ischaemia. We concluded that ischaemia in the border zone areas of both hemispheres was the result of sudden haemodynamic insufficiency during dissection of the aorta.

Saccadic eye movements can be divided into three types: reflexive, intentional, and spontaneous saccades. Reflexive saccades are triggered by the sudden appearance of an external visual stimulus, whereas intentional and spontaneous saccades are internally triggered. Three cortical areas may trigger saccades—the frontal eye field (FEF), the supplementary eye field (SEF), and the parietal eye field (PEF). The FEF are involved mainly in intentional visual exploration (intentional saccades), the PEF mainly in reflexive visual exploration (reflexive saccades), and the SEF mainly in the preparation of motor programmes. SEF also appear to control spontaneous saccades.²

Only bilateral lesions affecting these areas result in visible saccade disturbances on bedside examination. Saccadic eye movement disorders resulting from unilateral lesions of these areas can only be revealed by electro-oculographic recordings.³ Acquired ocular motor apraxia is usually caused by

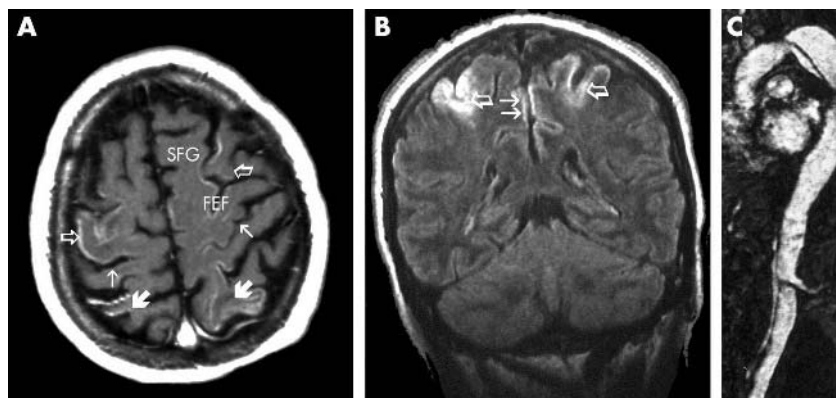


Figure 1 (A) Axial contrast enhanced T1 weighted magnetic resonance scan showing gyriform cortical enhancement caused by laminar cortical necrosis following a hypoxic ischaemic episode. Neural parenchyma of both the precentral area (frontal lobe, open arrow) and the postcentral area (parietal lobe, thick arrow) was involved. The thin arrow indicates the central sulcus. FEF, frontal eye field; SFG, superior frontal gyrus. (B) Contrast enhanced coronal section through the parietal lobe. The intraparietal sulcus (PEF, open arrows) was involved as well as the medial part of the parietal lobe (thin arrows), while posterior cingulate cortex was spared. (C) Contrast enhanced magnetic resonance angiography showing irregularity of the vessel wall beginning from the aortic arch and extending to the abdominal aorta.

bihemispheric infarcts.¹ Our patient could not be evaluated for any apraxia of his extremities or for optic ataxia because of the degree of paresis in both his arms. He might also have had an optical ataxia during the period when he had anosognosia and right–left disorientation. The development of a substantial degree of paresis with hypertonia in the first days of the ischaemic insult, and the continuation of these symptoms after ocular motor apraxia had resolved, may suggest that the anterior border zone areas were affected to a greater degree than the posterior border zone areas.

For this reason the functions of both the FEFs might have been undertaken by the PEFs. It seems likely that this role could be assumed by other areas, such as the posterior areas, as an adaptive response after injury.⁴ Bilateral damage to the PEFs may result in severe impairment of pursuit movements.¹ The posterior cingulate cortex (PCC)—which is known to show neuronal activity during pursuit movements²—was spared in our patient. However, the medial superior temporal lobe (MST), located close to the intraparietal sulcus, was possibly damaged. This area is known to be implicated in pursuit

eye movements from single cell recording studies in the monkey.³

We observed in our patient that ocular apraxia and pursuit movements of the eyes began to resolve simultaneously. This observation may suggest that recovery in the PEFs might have occurred first and have compensated for the FEFs. Recovery of spontaneous saccades in the first few days of ischaemia might indicate that the SEFs, which are assumed to be responsible for these eye movements, were not seriously damaged.

B O Genç, E Genç, L Açıık, S İlhan

Selçuk University, Meram Medical Faculty,
Department of Neurology, Konya, Turkey

Y Paksoy

ULTRA Görüntüleme Merkezi (Imaging Centre), Konya

Correspondence to: Dr Bülent Oğuz Genç, Selçuk University, Meram Medical Faculty, Department of Neurology, Konya 42080, Turkey; bogenc@mynet.com

doi: 10.1136/jnnp.2004.036525

Competing interests: none declared

References

- 1 **Pierrot-Deseilligny C, Gautier JC, Loron P.** Acquired ocular motor apraxia due to bilateral frontoparietal infarcts. *Ann Neurol* 1988;**23**:199–202.
- 2 **Pierrot-Deseilligny C, Milea D, Müri RM.** Eye movement control by the cerebral cortex. *Curr Opin Neurol* 2004;**17**:17–25.
- 3 **Pierrot-Deseilligny C, Gaymard B, Müri R, et al.** Cerebral ocular motor signs. *J Neurol* 1997;**244**:65–70.
- 4 **Anderson TJ, Henkins IH, Brooks DJ, et al.** Cortical control of saccades and fixation in man: a PET study. *Brain* 1994;**117**:1073–84.
- 5 **Wardak C, Duhamel JR.** The control of gaze. (1) The role of parietal cortex. *Med Sci (Paris)* 2004;**20**:89–97.