

DISCUSSION

Craniofacial FD is a lesion of unknown etiology, uncertain pathogenesis, and diverse histopathology.⁶ However, it has been considered that a congenital anomaly of mesenchymal development may be responsible for craniofacial FD.² It has been reported that FD of the paranasal air sinuses usually develops as a result of extension of the disorder into the sinuses from adjacent facial osseous tissue.⁵ Craniofacial FD frequently involves the anterior base of the skull.³ In a series of 16 patients with FD of the craniomaxillofacial bones, the most common location was maxillary.⁷ In our patient, FD presented in the bones anterior to the frontal lobe. FD of the skull radiologically takes three forms:^{1,2} (1) A compact form detected in 50% of cases, with a homogeneous and relatively radiopaque CT appearance with uniformly increased density due to thickening of bone; (2) A cystic form affecting the cranial vault (primarily the outer table) more frequently, accounting for only 5% of cases. The CT scan shows an irregular lucent area surrounded by a margin of increased density and no contrast enhancement; (3) A mixed form occurs primarily in the cranial vault. A ground-glass appearance on CT scan, thinning of the cortical bone, and ballooning of the affected area are the hallmarks of FD. In our patient, CT scan findings were consistent with typical FD with an opacity filling the left frontal sinus and the anterior cranial fossa. Additionally, this lesion was associated with a cerebral abscess.

Cerebral abscess often arises from infection (sinusitis, otitis, cranial osteomyelitis) of structures adjacent to the brain; however, it may also be associated with systemic infections, especially those of the lungs (pneumonitis, lung abscess), and less commonly dental infections.^{8–10} Sinus infection has been reported due to osteomas, as a result of obstruction of the sinus by the tumour.¹¹ Likewise, it is probable that FD can also lead to a collection of infected mucous by obstruction of the frontal sinus. FLA arises most often from paranasal sinus infection.¹⁰ Reports suggest that transmission of infection to the brain from the sinuses may be via the venous system.^{12,13} However, it has also been reported that FD of the paranasal sinuses rarely remains within the sinuses and often involves the adjacent brain tissue.⁵ Thus, after the destruction of the posterior wall of the frontal sinus by the dysplastic process, extradural extension of FD, followed by meningeal erosion, may result in a communication between the frontal sinus and the brain. It is possible that our patient developed a cerebral abscess as a result of venous seeding (such as via an epidural vein) from the left frontal sinus infection or alternatively, that transmission of the infection to the brain from the sinus may have been via a fistula between the frontal sinus and the brain.

In cerebral abscess, the clinical symptoms are dependent on the lesion location.¹⁰ Frontal lobe abscess presents predominantly with headache, drowsiness, confusion, and general impairment of mental function.^{10,14} Summers et al.¹³ diagnosed a frontal sinus osteoma associated with frontal lobe abscess by CT scan in a 51-year-old man who had symptoms consistent with a cerebral abscess including frontal headaches, new onset of seizures, lethargy, global dysphasia, and hemiparesis. Although our patient presented with prolonged confusion after convulsions, she had no history of headache, vomiting, drowsiness or behavioural abnormality. She displayed no signs or symptoms of long tract involvement. Simovic et al.⁴ reported three patients with FD of the frontal sinus, ethmoid sinus, and maxillary sinus. In another report, a 28-year-old man presented with fronto-orbital FD associated with convulsions.⁶ In these two papers, neither developed a cerebral abscess. It is probable that in our patient, epileptic seizures were associated with both the FLA and FD.

In conclusion, we describe the radiological appearance of FD of the frontal sinus and discuss an unusual clinical presentation (prolonged post-ictal confusion) and a rare complication (cerebral ab-

cess). Our report emphasises that patients presenting with prolonged post-ictal confusion, without a metabolic disorder, should have a CT scan.

REFERENCES

- Adada B, Al-Mefty O. Fibrous dysplasia of the clivus. *Neurosurgery* 2003; 52: 318–323.
- Jan M, Dweik A, Destrieux C, Djebbari Y. Fronto-orbital sphenoidal fibrous dysplasia. *Neurosurgery* 1994; 34: 544–547.
- Lee JS, Fitzgibbon E, Butman JA, et al. Normal vision despite narrowing of the optic canal in fibrous dysplasia. *N Engl J Med* 2002; 347: 1670–1676.
- Simovic S, Klapac I, Bumber Z, Bura M. Fibrous dysplasia in paranasal cavities. *Otorhinolaryngol Relat Spec* 1996; 58: 55–58.
- Feldman MD, Rao VM, Lowry LD, Kelly M. Fibrous dysplasia of the paranasal sinuses. *Otolaryngol Head Neck Surg* 1986; 95: 222–225.
- Kanda M, Yuhki I, Murakami Y, Hasegawa Y, Kanki T. Monostotic fronto-orbital fibrous dysplasia with convulsion – case report. *Neurol Med Chir* 2002; 42: 36–39.
- Ozek C, Gundogan H, Bilkay U, Tokat C, Gurler T, Songur E. Craniomaxillofacial fibrous dysplasia. *J Craniofac Surg* 2002; 13: 382–389.
- Asensi V, Alvarez M, Carton JA, et al. *Eikenella corrodens* brain abscess after repeated periodontal manipulations cured with imipenem and neurosurgery. *Infection* 2002; 30: 240–242.
- Greenberg DA, Aminoff MJ, Simon RP. *Clinical Neurology*. New York: McGraw-Hill; 2002.
- Solbrig MV, Healy JF, Jay CA. Infections of the Nervous system: bacterial infections. In: Bradley WG, et al, editors. *Neurology in Clinical practice*. Boston: Butterworth-Heinemann; 2000. p. 1317–1351.
- Smith ME, Calcaterra TC. Frontal sinus osteoma. *Ann Otol Rhinol Laryngol* 1989; 98: 896–900.
- Gallagher RM, Gross CW, Phillips CD. Suppurative intracranial complications of sinusitis. *Laryngoscope* 1998; 108: 1635–1642.
- Summers LE, Mascott CR, Tompkins JR, Richardson De. Frontal sinus osteoma associated with cerebral abscess formation: a case report. *Surg Neurol* 2001; 55: 235–239.
- Victor M, Ropper AH. *Adams and Victor's Principles of Neurology*. New York: McGraw-Hill; 2001.

Peritumoural haematoma and meningioma: a common tumour with an uncommon presentation

A.T. Kouyialis MD¹, G. Stranjalis MD¹, R. Analyti MD², E.J. Boviatsis MD¹, S. Korfiatis MD¹, D.E. Sakas MD¹

¹ Department of Neurosurgery, University of Athens Medical School, Evangelismos General Hospital, Athens, Greece, ² Department of Radiology, Evangelismos General Hospital, Athens, Greece

Summary Spontaneous peritumoural haemorrhage in meningiomas is a rare but serious complication with a grave prognosis. It occurs at the interface between the tumour and the parenchyma, either from the tumour surface or the cortical vessels in association with it. Although several pathophysiologic mechanisms for this complication have been proposed, they all remain speculative. We report a 72-year-old female who presented with sudden onset of headache and a left homonymous hemianopia. Neuroimaging revealed a parasagittal meningioma at the posterior third of the superior sagittal sinus with peritumoural intracerebral haematoma, 1 cm away from the tumour. An uncomplicated gross total excision of the meningioma and aspiration of the haematoma was achieved through a craniotomy. The postoperative course was uneventful with an excellent clinical out-

come. Possible mechanisms for this unusual complication are discussed. We emphasise the importance of prompt diagnosis and simultaneous excision of the tumour and aspiration of the haematoma as prerequisites for a favourable outcome.

© 2004 Elsevier Ltd. All rights reserved.

Journal of Clinical Neuroscience (2004) 11(8), 906–909
0967-5868/\$ - see front matter © 2004 Elsevier Ltd. All rights reserved.
doi:10.1016/j.jocn.2004.02.014

Keywords: meningioma, peritumoural haemorrhage, tumour, tumour infarction, cerebral venous hypertension

Received 25 August 2003

Accepted 3 February 2004

Correspondence to: George Stranjalis MD, 32 Skoufa St., Kolonaki 10673, Athens, Greece. Tel.: +30 210 362 3740; Fax: +30 210 724 9986

INTRODUCTION

Meningiomas are usually benign tumours arising from arachnoidal cap cells that manifest through symptoms of increased intracranial pressure and seizures. Progressive neurologic deficits may also occur and depend on tumour location and growth.¹ However, diagnosis of a meningioma due to spontaneous peritumoural intracerebral haemorrhage is very uncommon, with an incidence of approximately 1% and only a few cases reported in the literature.² In most cases presented, the haemorrhage occurs within the tumour itself or at its boundaries within the brain.^{3,4}

Although several hypotheses have been proposed in an attempt to explain the pathophysiologic mechanism of bleeding, they remain speculative.

In this report, we describe a 72-year-old patient with parasagittal meningioma at the posterior third of the superior sagittal sinus causing spontaneous intracerebral peritumoural haematoma. Unusually, the haematoma was not intracavitary or located at the interface between the tumour and the cortex, but rather at a distance of approximately 1 cm from the meningioma. We discuss the possible mechanisms of this rare presentation.

CASE REPORT

A 72-year-old woman with no past medical history was admitted to our department with sudden onset of headache and vomiting, followed by loss of consciousness. On admission, she had a Glasgow Coma Score of 13 and vital signs within normal limits. Physical examination revealed nuchal rigidity and left homonymous hemianopia. Laboratory tests were normal. The patient had no predisposing factors for the development of a haematoma, including head injury, arterial hypertension or coagulopathy. A brain CT scan showed a 3 cm right-sided parasagittal mass at the posterior third of the superior sagittal sinus, with no signs of mass effect. The lesion was homogenous, had rounded well-defined margins and showed homogenous enhancement. Next to the lesion, at a distance of 1 cm, there was an area of increased attenuation surrounded by a hypodense ring (Fig. 1). The diagnosis was spontaneous intracerebral haematoma in the vicinity of a meningioma and this was confirmed by an MRI (Fig. 2). Angiography showed the blood supply to be coming from the right external carotid artery, relative stenosis of the superior sagittal sinus caudal to the meningioma and a congested bridging vein (Fig. 3).

The patient was immediately taken to the operating room. Via a right parieto-occipital craniotomy the meningioma was totally removed, along with the overlying dura. No invasion of the superior sagittal sinus was noted. The haematoma adjacent to the tumour

was aspirated through a separate small cortical incision. Histological examination showed endotheliomatous meningioma with sites of atypia. Although no abnormal vasculature was noted, there were several sites of infarction and necrosis. The recovery was uneventful and the patient was discharged with a Glasgow Outcome Score of 5. At six months follow up, she had a normal neuro-behavioural examination and no systemic abnormalities.

DISCUSSION

Haemorrhage has been reported as an initial presenting symptom in 3.9% of all intracranial neoplasms and usually occurs within the tumour.⁵ It mostly occurs in glioblastoma multiforme, metastatic tumours (melanoma, hypernephroma and choriocarcinoma), germ cell tumours, oligodendrogliomas and pituitary adenomas.⁶ In contrast, spontaneous intracranial haemorrhage as initial presentation for meningiomas, even though reported, is less frequent, despite the fact that these are usually vascular tumours.^{1,3,4,7–9} The incidence is 1.3% of all meningiomas,² with parasagittal, intraventricular or convexity meningiomas having a higher incidence of spontaneous haemorrhage than those located elsewhere.⁸ The commonly reported site of haemorrhage from meningiomas is the subarachnoid space, followed by intratumoural and intracerebral haemorrhage.¹

The histological type of meningioma has been reported to play an important role in the occurrence of haemorrhage. Several authors have suggested that the bleeding potential is higher in angioblastic and malignant meningiomas.^{8,10,11} In cases of angioblastic meningioma the newly formed tumour vessels have thin walls, thus are fragile and bleed easily. For malignant meningiomas, the mechanism is assumed to be invasion of vessels, endothelial proliferation with weak vascular walls or obstruction of a vessel lumen leading to infarction, necrosis and bleeding.¹ Kohli and Crouch⁸ through, reviewing 45 cases of spontaneous intracranial haemorrhage in meningiomas, indicated that the endotheliomatous type of meningioma accounted for the majority

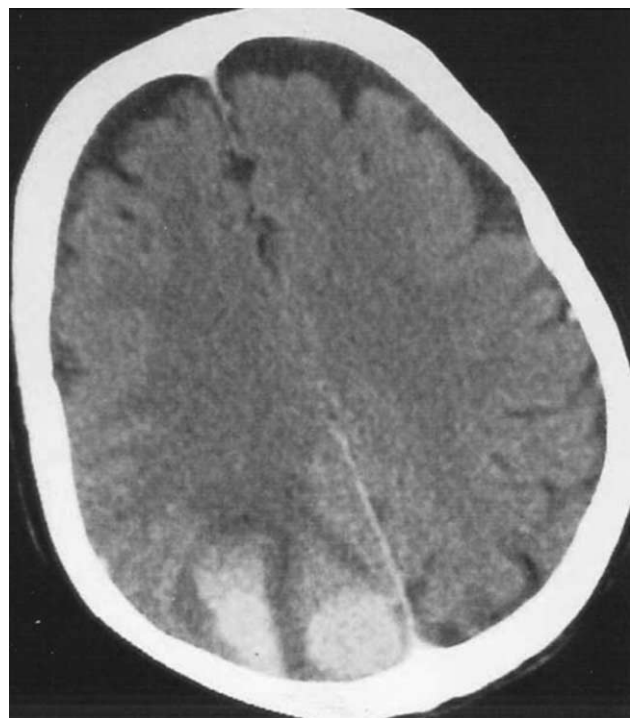

Fig. 1 Enhanced CT scan, showing a parasagittal homogenous high-density meningioma and a cortical parietal haematoma.

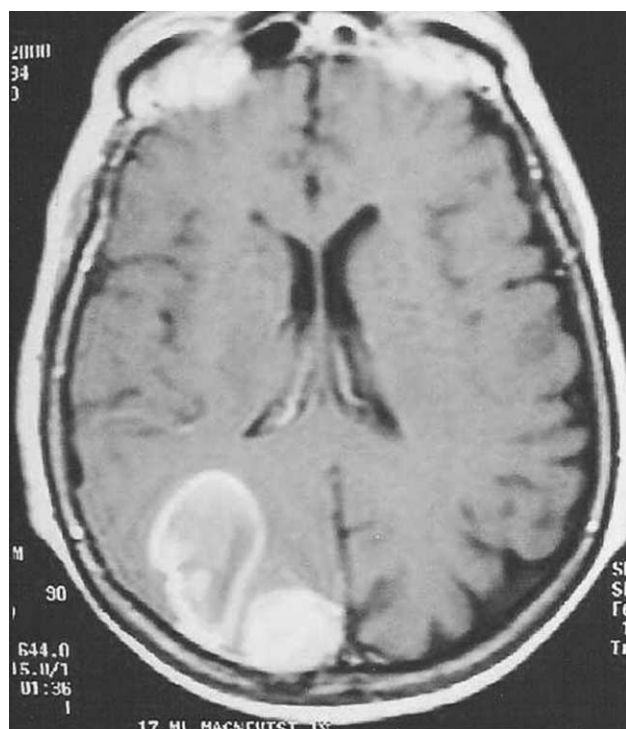


Fig. 2 T1-weighted brain MRI with gadolinium enhancement, showing both the meningioma and the intracerebral haematoma.

of reported cases. A possible explanation, as reported by Lazaro et al.,¹² is the presence of more than one tissue patterns within this subtype, confined to compartments in the tumour, that include areas of increased vascularity with thin-walled vessels. In the reported case, the histological diagnosis was endotheliomatous meningioma with sites of atypia. There were several sites of infarction and necrosis but no abnormal or thin-walled vessels were noted. This finding does not contradict previous reports, since the bleeding occurred at a distance and not within or directly associated with the tumour.

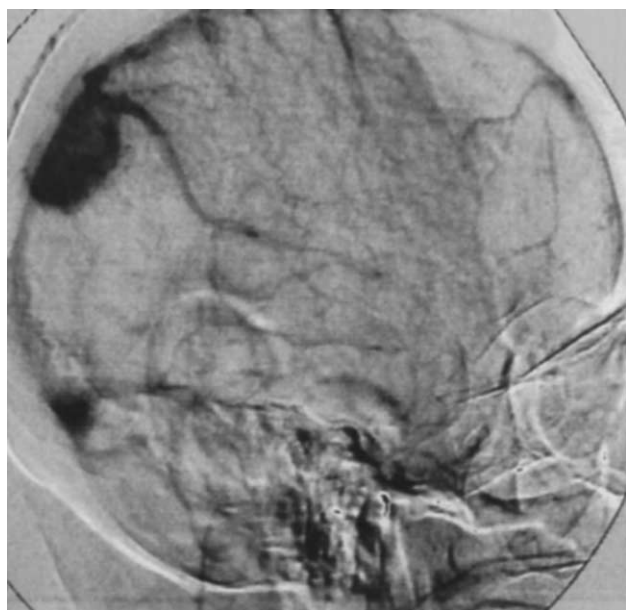


Fig. 3 A digital subtraction angiography, showing a typical meningioma blush and superior sagittal sinus stenosis. Tumour blood supply is from the occipital branch of the right external carotid artery.

The exact mechanism of haemorrhage is not fully understood despite several hypotheses. The most common is the rupture of newly formed tumour vessels or direct peritumoural vascular erosion.^{10,13,14} This hypothesis is based on the presence of abnormal vessels, a histological finding not reported in every case. A second hypothesis is that rapid growth of the tumour leads to intratumoural necrosis, direct breakdown of tumour vessels and haemorrhage.¹⁵ A rapidly growing tumour may imply a malignant meningioma, but this is not the case in the majority of reported cases. Furthermore, there is no objective evidence of tumour vessel structural failure caused by necrosis.⁴ Third, Okuno et al.¹ suggested that mechanical stretching and distortion of cortical bridging veins by a growing tumour may cause haemorrhage. For this mechanism, the site of haemorrhage would be mainly the subdural space and not the parenchyma, but Martinez-Lage et al.⁹ reported that of 57 meningiomas with spontaneous haemorrhagic onset, in only 10 the haemorrhage was located subdurally. Fourth, El-Banhawy et al.¹⁶ proposed that the development of most meningiomas in the vicinity of meningeal and cerebral vessels and dural venous sinuses leads to thrombosis or obstruction or vessels with resulting oedema, ischaemia, necrosis and haemorrhage. Likewise, Renowden et al.⁶ suggested that falxine meningiomas, in a close association with the sagittal sinus, which they tend to invade and occlude, may cause venous hypertension and haemorrhage.

Thus, one may expect a higher incidence of spontaneous bleeding from meningiomas than is reported. In another hypothesis, extensive intratumoural infarction has been implicated. Kim et al.⁴ in a series of three patients and a review of other reported cases, found tumour infarction to be common. They suggested that rapid tumour growth and other predisposing events such as thrombosis, oedema and vessel erosion would eventually result in infarction. Progression of the infarction would increase intratumoural pressure and lead to rupture of peritumoural vessels. Finally, other proposed mechanisms include seizures, intratumoural coagulopathy, trauma and malignant transformation.^{12,13}

Despite the many theories, it is impossible to explain the various patterns of haemorrhage described in the literature, so the definitive cause of bleeding remains unclear. It is possible that a combination of these mechanisms operates in each case. In our patient, the haematoma occurred within the parenchyma, but at a distance of 1 cm from the tumour. Even though there was no major venous invasion or obstruction, development in direct contact with the superior sagittal sinus, combined with the presence of several sites of infarction and necrosis, within the tumour, led us to conclude that the haemorrhage was a result of cerebral venous hypertension. We concluded that the haemorrhage was a combination of long-term venous compression and congestion and structural change in small intraparenchymal veins in the vicinity of the tumour, which became fragile. The prognosis of these patients is generally poor, and approximately 50% of them will die, regardless of haemorrhage type.¹ The factors responsible for this high mortality have not been precisely identified. However, most frequently associated with a grave outcome is poor clinical status at onset.¹ In the case reported, the good initial neurological status (admission GCS of 13), combined with the small size of the haematoma, the absence of mass effect and the rapid tumour excision and evacuation of the haematoma before irreversible damage had occurred, led to a good outcome.

CONCLUSIONS

Spontaneous peritumoural intracerebral haemorrhage as an initial presentation of meningiomas is uncommonly reported in neurosurgical literature and although rare, should be considered in the

differential diagnosis of intracranial haemorrhage. In a patient with a meningioma, it is imperative that the surgeon distinguishes whether haemorrhage has resulted from the adjacent tumour, or is the result of other causes such as head trauma, arterial hypertension, drugs, or coagulopathy. Treatment should aim at evacuation of the haematoma with simultaneous total excision of the tumour. The operation should be performed as soon as other causes have been excluded and before irreversible brain damage has occurred.

REFERENCES

- Okuno S, Touho H, Ohniski H, Karasawa J. Falx meningioma presenting as acute subdural hematoma: case report. *Surg Neurol* 1999; 52: 180–184.
- Modesti LM, Binet EF, Collins GH. Meningiomas causing spontaneous intracranial hematomas. *J Neurosurg* 1976; 45: 437–441.
- Kanak KB, Tamaki N, Ehara K, Nagashima T, Suzuki H. Spontaneous peritumoral haemorrhage associated with sinus confluence meningioma: case report. *Surg Neurol* 2000; 54: 254–259.
- Kim DG, Park C-K, Paek SH, Choe GY, Gwak HS, Yoo H, Jung HW. Meningioma manifesting intracerebral haemorrhage: a possible mechanism of haemorrhage. *Acta Neurochir (Wien)* 2000; 142: 165–168.
- Salzman M. Intracranial hemorrhage caused by brain tumour. In: Kaufman H, editor. *Intracerebral hematomas*. New York: Raven Press; 1992. p. 95–106.
- Renowden SA, Houran MD. Case report: acute subdural haematoma – an unusual presentation of a meningioma. *Clin Radiol* 1992; 45: 351–352.
- Kaur U, Chopra JS, Kak VK, Banerjee AK. Meningioma presenting as recurrent transient cerebral ischemia and intracranial hemorrhage. *Surg Neurol* 1982; 17: 120–122.
- Kohli CM, Crouch RL. Meningioma with intracerebral hematoma. *Neurosurgery* 1984; 14: 237–240.
- Martinez-Lage JF, Martinez MPM, Esteban JA, Antunez MC, Sola J. Meningiomas with hemorrhagic onset. *Acta Neurochir (Wien)* 1991; 110: 129–132.
- Helle TL, Conley FK. Haemorrhage associated with meningioma: a case report and review of the literature. *J Neurol Neurosurg Psychiatry* 1980; 43: 725–729.
- Nakao S, Sato S, Ban S, Inutsuka N, Yamamoto T, Ogata M. Massive intracerebral haemorrhage caused by angioblastic meningioma. *Surg Neurol* 1977; 7: 245–248.
- Lazaro RP, Messer HO, Brinker RA. Intracranial haemorrhage associated with meningioma. *Neurosurgery* 1981; 8: 96–101.
- Bloomgarden GM, Byrne TN, Spencer DO, Heafer MD. Meningioma associated with aneurysm and subarachnoid hemorrhage: case report and review of the literature. *Neurosurgery* 1987; 20: 24–26.
- Chaskis C, Raftopoulos C, Noterman J, Flament-Durant J, Brotchi J. Meningioma associated with subdural hematoma: report of two cases and review of the literature. *Clin Neurol Neurosurg* 1992; 94: 269–274.
- Gruszkiewicz J, Doron Y, Gellei B, Peyer E. Massive intracerebral bleeding due to supratentorial meningioma. *Neurochirurgia (Stuttg)* 1969; 12: 107–111.
- El-Banhawy A, Walter W. Meningiomas with acute onset. *Acta Neurochir (Wien)* 1962; 10: 194–206.

Cervical subdural empyema following acupuncture

Ming-Hong Chen MD¹, Mei-Hsiu Chen MD²,
Jing-Shan Huang MD¹

¹ Division of Neurosurgery, Department of Surgery, Cathay General Hospital, Taipei, Taiwan, ROC, ² Department of Internal Medicine, Far Eastern Memorial Hospital, Taipei, Taiwan, ROC

Summary A review of the literature reveals only a few cases of spinal subdural empyema. Etiologies of spinal subdural empyema include hematogenous spread from skin lesions, systemic sepsis,

direct spread from spinal osteomyelitis and complications of discography. However, in this report, we describe a patient who developed spinal subdural empyema following several cervical acupuncture sessions. Operative treatment with adequate laminectomy, removal of abscess, and copious irrigation resulted in good recovery. Microbiologic culture study of pus obtained at surgery was positive for *Staphylococcus aureus*. The need for sterilization procedures for acupuncture is emphasized and a brief review of the relevant literature is presented.

© 2004 Elsevier Ltd. All rights reserved.

Journal of Clinical Neuroscience (2004) 11(8), 909–911
0967-5868/\$ - see front matter © 2004 Elsevier Ltd. All rights reserved.
doi:10.1016/j.jocn.2004.02.011

Keywords: cervical, subdural empyema, acupuncture

Received 25 August 2003

Accepted 5 February 2004

Correspondence to: Jing-Shan Huang, Division of Neurosurgery, Department of Surgery, Cathay General Hospital No. 280, Sec. 4, Jen-Ai Road, Taipei, Taiwan, ROC. Tel.: +886-2-2708-2121; Fax: +886-2-2754-0222; E-mail: cmhcmh@so-net.net.tw

INTRODUCTION

Acupuncture is a very popular treatment modality used by patients with chronic painful musculoskeletal disorders in Asian countries. There are, however, few well-designed studies of its benefits. Regardless of the efficacy of acupuncture, its associated complications and its mechanism for pain relief remained an issue of debate.¹ In this report, we describe a patient with a cervical spinal subdural empyema that developed following acupuncture in the posterior nuchal region and in whom surgical decompression and copious irrigation, followed by adequate antibiotics treatment resulted in a favorable outcome. To the best of our knowledge, no other cases of spinal subdural empyema after acupuncture have been previously reported in the English-language literature. Although the need for skin disinfection before insertion of an acupuncture needle is controversial, we contribute this case to emphasize the importance of sterilization procedures for acupuncture.

CASE REPORT

A 44-year-old man had suffered from chronic nuchal and subscapular pain for months and underwent cervical acupuncture for treatment of those symptoms 4 weeks before admission. The patient had no history of diabetes mellitus. The acupuncture had been conducted for several sessions in the cervical paraspinal and medial scapular region at a private acupuncture clinic. After the last session of acupuncture, the patient experienced new radiating pain to the left upper extremity. During the 2 weeks following the acupuncture sessions, the patient began to experience left elbow soreness and weakening of left-hand grip strength. Progressive left hemiparesis involving the upper and lower limbs, radiating pain to the back and buttocks subsequently developed. The patient had intermittent fever and one episode of chills during the week before admission.

At the time of admission, neurological examination revealed weakness of left upper limb and spastic paraparesis. Left hemifacial hyperhidrosis was noted. There was no localized tenderness on the neck. The WBC count was 8230/mm³, with 80.9% segmented neutrophils. Cultures of blood drawn on admission were