

MRI of patients with cerebral palsy and normal CT scan

P. van Bogaert¹, D. Baleriaux², C. Christophe², and H. B. Szliwowski¹

Departments of ¹ Neurology (Pediatric Neurology) and

² Radiology (Neuroradiology), Hôpital Erasme, Université Libre de Bruxelles, Brussels, Belgium

Received: 5 November 1990

Summary. Three children with clinical evidence of cerebral palsy (CP) and normal cerebral computed tomography (CT) scans were evaluated by magnetic resonance imaging (MRI) to identify CT-undetectable white matter lesions in the watershed zones of arterial territories. The two patients with spastic diplegia showed bilateral lesions either in the subcortical regions or in the occipital periventricular regions. The patient with congenital hemiplegia exhibited unilateral lesions in the periventricular region. We conclude that MRI is more informative than CT for the evaluation of patients with CP.

Key words: Cerebral palsy – Congenital hemiplegia – Spastic diplegia – Magnetic resonance imaging – Computed tomography – Periventricular leukomalacia

Spastic diplegia (SD) and congenital hemiplegia are the most common forms of cerebral palsy (CP), defined as a permanent impairment of movement and posture resulting from a non-progressive brain disorder.

SD is a spastic paresis of the lower extremities with variable but lesser involvement of the upper limbs. It is one of the most characteristic clinical presentations of periventricular leukomalacia (PVL) [1]. This condition occurs preferentially in premature infants as the result of ischemic infarction of the periventricular white matter [2]. Nevertheless, SD can occur in full-term infants with normal birth weight, and in these cases the causes and the neuropathologic correlates seem to be more varied [3].

Congenital hemiplegia is defined as unilateral motor disability. It has many etiologies but results most often from unilateral ischemic infarction in the distribution of the middle cerebral artery or in the periventricular region [1].

CP can be documented by sonography during the neonatal period [4, 5] or by CT scanning [6–13]. Unfortunately, the results of neonatal sonograms are not always available or contributory, and the CT scan can be normal [7–13]. We have investigated the value of MRI in three

children with CP and absence of abnormalities on their CT scans.

Patients and methods

Patient 1 is a 3-year-old boy born by cesarian section for acute fetal distress at 39 weeks gestational age. Birth weight was 2280 g. Apgar score was 0 at 1 min and 4 at 5 min. After resuscitation, he was treated for 3 weeks in a neonatal intensive care unit. A few seizures were noted during his first 3 days of life. Cranial sonography and CT scanning performed on the 5th day were normal. His psychomotor development was retarded, and he began to walk at the age of 30 months. His head circumference, length and weight are all below the third percentile. He speaks short sentences with a marked dysarthria. Examination of the cranial nerves is otherwise normal. Motor function testing discloses a spastic paresis predominating at the lower limbs with a characteristic spastic gait. Milder involvement of the upper limbs is noted for finger movements. His development quotient on the Brunet-Lezine scale is 80.

Patient 2 is a 5-year-old boy, born prematurely at 33 weeks gestational age by cesarian section because of maternal hemorrhage; his birth weight was 1180 g. Apgar score was 5 at 1 min and 8 at 5 min. A few hours after birth he developed severe respiratory distress from hyaline membrane disease, requiring prolonged artificial ventilation in a neonatal intensive care unit. Cranial sonogram on the 19th day of life demonstrated a left subependymal hemorrhage. His milestones were delayed but constantly progressive; he began to walk at 21 months of age and to talk at 24 months of age. Surgery was performed to correct an alternating convergent strabismus at 27 months of age. Head circumference, length and weight are in the third percentile. The clinical picture is that of an asymmetric SD which predominates on the right side: fine motricity of the fingers is better on the left side, the bilateral equinovarus deformity of the feet and hyperreflexia are more pronounced on the right side, and a Babinski sign is present bilaterally.

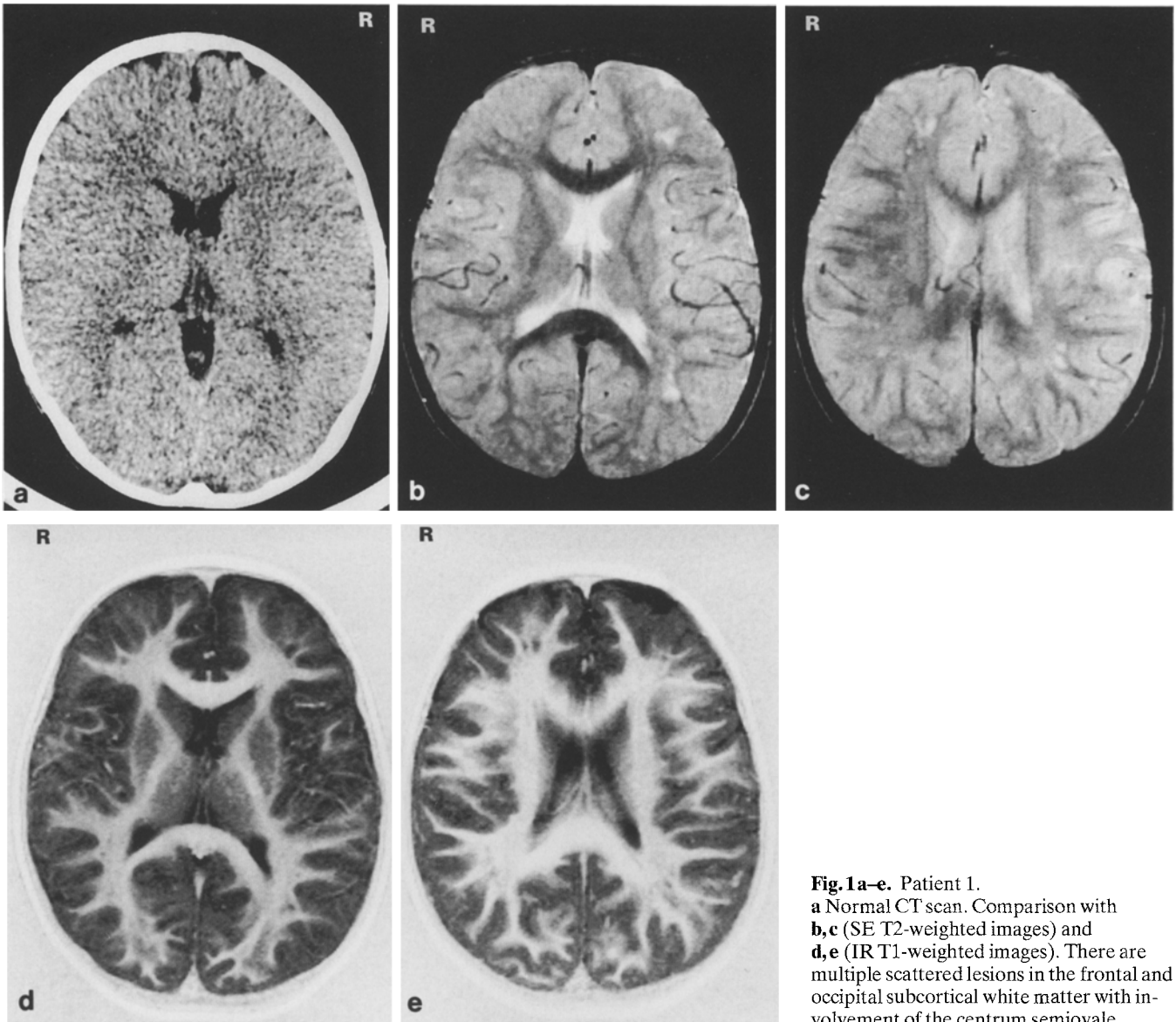


Fig. 1a-e. Patient 1.
a Normal CT scan. Comparison with **b, c** (SE T2-weighted images) and **d, e** (IR T1-weighted images). There are multiple scattered lesions in the frontal and occipital subcortical white matter with involvement of the centrum semiovale

Patient 3 is an 8-year-old girl, born after 41 weeks gestation with a birth weight of 2540 g. She cried spontaneously but there was a question of mild hypothermia on her 1st day of life. During the first months, her parents reported that her left wrist nearly always remained closed, and that she manipulated objects with her right hand preferentially. She began to walk at 15 months of age with an abnormal gait characterized by circumduction of her left leg. Clinical examination at 2 years of age revealed a clear picture of left hemiplegia with spontaneous positioning of the left forearm in flexion and pronation, hyperextensibility of the fingers, clumsiness with prehensile movement of objects with the left hand, equinovarus deformity of the left foot, left hyperreflexia and left Babinski sign. Her congenital hemiplegia has remained moderate until now with physical therapy. Development of cognitive functions has been normal.

MRI was performed on a superconducting 0.5 T system. For all patients, T2-weighted images were obtained

in either axial or coronal planes with a standard spin echo (SE) technique (TE: 40 and 95 ms; TR: 2500 ms); T1-weighted images were obtained in the axial plane with an inversion recovery (IR) technique (TE: 35 ms, TI: 300 ms, TR: 1500 ms).

CT scans were performed for all patients with a 2-mm slice thickness and a 2-mm interslice gap. Images were viewed with a narrow window.

Results

The CT scans were normal in all cases (Figs. 1 a, 2 a and 3 a). In patient 1, MRI demonstrated scattered lesions in the subcortical white matter of the frontal and occipital lobes. These lesions were hyperintense on T2-weighted images (Fig. 1 b, c). The same lesions appeared less extensive and hypointense on T1-weighted images (Fig. 1 d, e).

In patient 2, T2-weighted images exhibited periventricular hyperintense lesions in front of the trigone of the

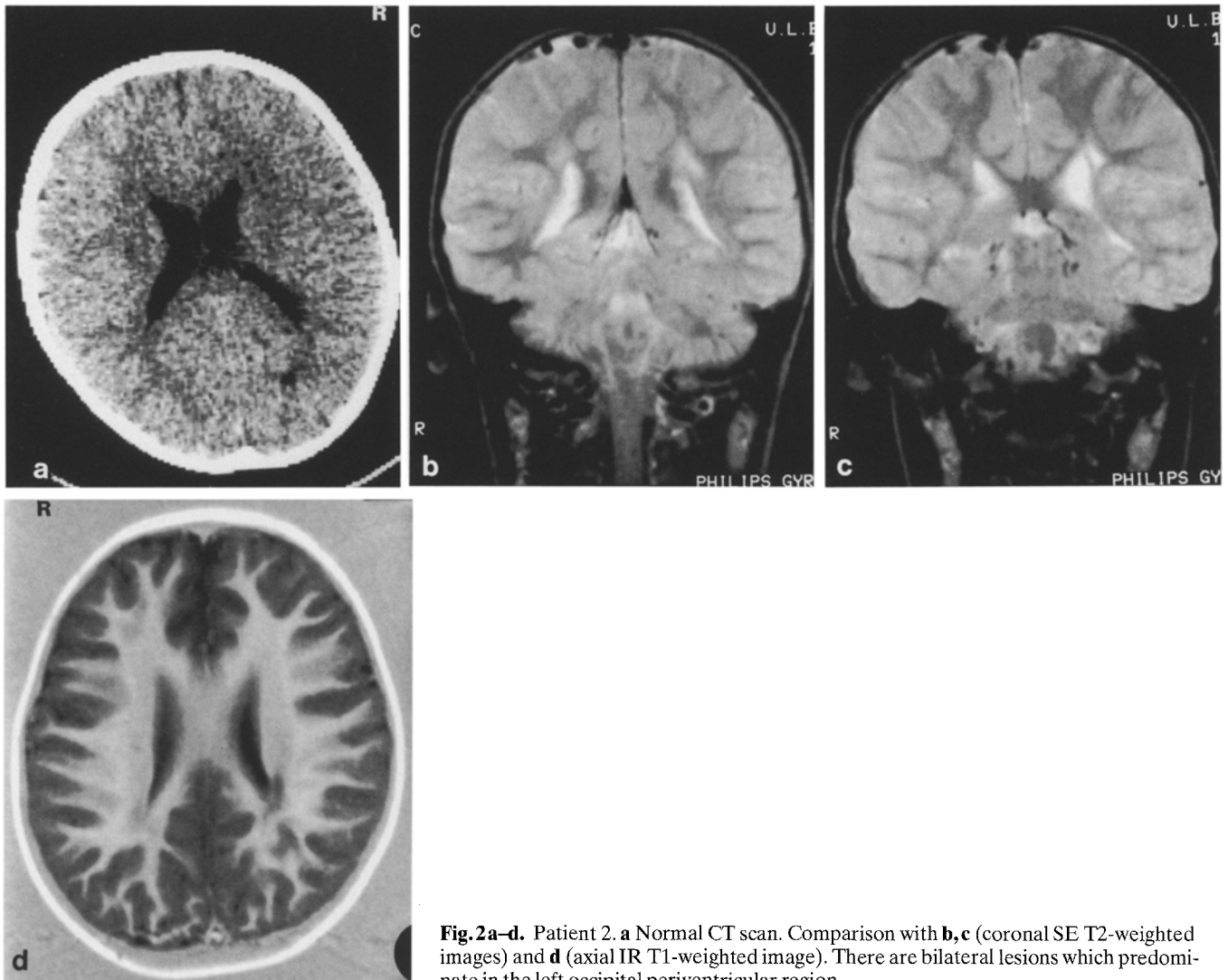


Fig. 2a-d. Patient 2. **a** Normal CT scan. Comparison with **b,c** (coronal SE T2-weighted images) and **d** (axial IR T1-weighted image). There are bilateral lesions which predominate in the left occipital periventricular region

lateral ventricle. However, coronal images demonstrated clear asymmetry of the lesions, which were more extensive on the left side (Fig. 3b, c). T1-weighted images in the axial plane confirmed this asymmetric involvement of the occipital periventricular regions as hypointense areas (Fig. 3d).

Patient 3, with congenital left hemiplegia, exhibited two right lateral periventricular lesions: the more extensive is located in front of the trigone while a smaller one is seen in the frontal region (Fig. 4b-c). These lesions are hyperintense on T2-weighted images and hypointense on T1-weighted images.

Discussion

In three patients with CP, MRI identified abnormalities not visible on CT scan. These abnormalities consist of hyperintense white matter lesions on T2-weighted images with corresponding hypointense but less extensive abnormalities on T1-weighted images. In all cases, the abnormalities are situated in the watershed zones between the

anterior, middle and posterior cerebral arteries and presumably result from an ischemic injury.

The two patients with SD exhibit bilateral white matter lesions. The localization of these watershed infarcts differs in the first case when compared to the second one. In the first patient, a full-term child with SD, the lesions are located predominantly in the subcortical white matter and appear to correspond to a mild parasagittal cerebral injury without cortical involvement. Indeed parasagittal cerebral injury is characteristic of the full-term child with intrauterine asphyxia, and consists in necrosis of the cortex and the subcortical white matter especially in the parieto-occipital region [1]. In the second case of SD, we suggest that the lesions correspond to mild PVL, since the involvement of the occipital radiation at the trigone of the lateral ventricle is a constant autopsy finding in PVL [2]. It is of great interest in this patient that his asymmetric neurologic impairment (predominantly right paresis) correlates well with the asymmetric MRI abnormalities which are more pronounced in the left periventricular region.

Several reports have already described the MRI appearance of PVL, but most of them address premature in-

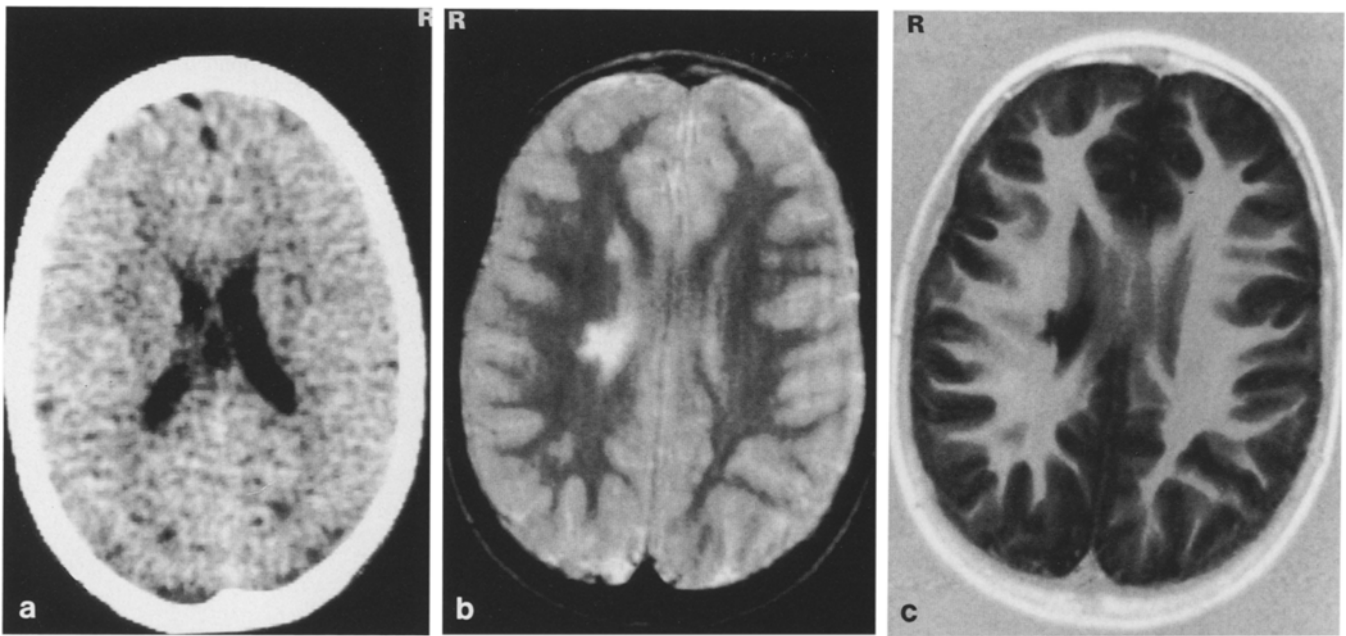


Fig. 3a-c. Patient 3. **a** Normal CT scan. Comparison with **b** (SE T2-weighted image) and **c** (IR T1-weighted image). There are right periventricular lesions

infants with evidence of PVL on sonograms [14, 15] or CT scans [16]. Flodmark et al. [16] concluded that MRI is more precise than CT scanning in the evaluation of PVL. The abnormalities demonstrable on CT scans (reduction in the amount of periventricular white matter, widening of sulci, ventriculomegaly, irregular ventricular outline) are more precisely delineated on IR images. Moreover, on T2-weighted images these authors described hyperintense lesions located in the occipital lobes beyond the periventricular region without involvement of the centrum semiovale and the subcortical white matter. In their study, there were no cases of CP with normal CT scan. More recently, Koeda et al. [17] reported their MRI observations in preterm and term infants with SD. In one term infant they found isolated periventricular lesions extending to the subcortical white matter. These lesions appeared hypointense on T1-weighted images and hyperintense on T2-weighted images; CT scan results were not mentioned in their cases.

Our patient with congenital hemiplegia (no. 3) exhibits lateral periventricular lesions which may correspond to unilateral PVL. No other report has emphasized the importance of MRI in the evaluation of infants with congenital hemiplegia. We believe that the physiopathology of this condition could be better understood by use of MRI, especially for patients with normal CT scans.

In conclusion, MRI evaluation of children with CP may disclose white matter lesions not visible on CT scan images. These lesions are most evident on T2-weighted images as hyperintense areas. MRI is useful in all conditions, such as the leukodystrophies, in which the white matter is affected [18]. Clinical evaluation of these children remains of primary importance. Other investigations must be performed if a progressive neurologic deterioration is suspected.

References

1. Volpe JJ (1987) *Neurology of the newborn*. Saunders, Philadelphia, pp 209–279
2. Shuman RM, Selednik LJ (1980) Periventricular leukomalacia: a one-year autopsy study. *Arch Neurol* 37: 231–235
3. Veelken N, Hagberg B, Hagberg G, Olow I (1983) Diplegic cerebral palsy in Swedish term and preterm children: differences in reduced optimality, relations to neurology and pathogenic factors. *Neuropediatrics* 14: 20–28
4. Bowerman RA, Donn SM, Di Pietro MA, D'Amato CJ, Hicks SP (1984) Periventricular leukomalacia in the pre-term newborn infant: sonographic and clinical features. *Radiology* 151: 383–388
5. Dubowitz LMS, Bydder GM, Mushin J (1985) Developmental sequence of periventricular leukomalacia: correlation of ultrasound, clinical, and nuclear magnetic functions. *Arch Dis Child* 60: 349–355
6. Flodmark O, Roland EH, Hill A, Whitfield MF (1987) Periventricular leukomalacia: radiologic diagnosis. *Radiology* 162: 119–124
7. Taudorf K, Melchior JC, Pedersen H (1984) CT findings in spastic cerebral palsy: clinical, aetiological and prognostic aspects. *Neuropediatrics* 15: 120–124
8. Koch B, Braillier D, Eng G, Binder H (1980) Computerized tomography in cerebral-palsied children. *Dev Med Child Neurol* 22: 595–607
9. Kulakowski S, Larroche JC (1980) Cranial computerized tomography in cerebral palsy. An attempt at anatomic-clinical and radiological correlations. *Neuropediatrics* 11: 339–353
10. Kotlarek F, Rodewig R, Brull D, Zeumer H (1981) Computed tomographic findings in congenital hemiparesis in childhood and their relation to etiology and prognosis. *Neuropediatrics* 12: 101–109
11. Cohen ME, Duffner PK (1981) Prognostic indicators in hemiparetic cerebral palsy. *Ann Neurol* 9: 353–357
12. Molteni B, Oleari G, Fedrizzi E, Bracchi M (1987) Relation between CT patterns, clinical findings and etiological factors in children born at term, affected by congenital hemiparesis. *Neuropediatrics* 18: 75–80

13. Wiklund LM, Uvebrant P, Flodmark O (1990) Morphology of cerebral lesions in children with congenital hemiplegia: a study with computed tomography. *Neuroradiology* 32: 179–186
14. Dubowitz LMS, Bydder GM (1985) Nuclear magnetic resonance imaging in the diagnosis and follow-up of neonatal cerebral injury. *Clin Perinatol* 12: 243–260
15. Wilson DA, Steiner RE (1986) Periventricular leukomalacia: evaluation with MR imaging. *Radiology* 160: 507–511
16. Flodmark O, Lupton B, Li D, Stimac GH, Roland EH, Hill A, Whitfield MF, Norman MG (1989) MR imaging of periventricular leukomalacia in childhood. *AJR* 152: 583–590
17. Koeda T, Suganuma I, Kohno Y, Takamatsu T, Takeshita K (1990) MR imaging of spastic diplegia: comparative study between preterm and term infants. *Neuroradiology* 32: 187–190
18. Kumar AJ, Rosenbaum AE, Naidu S, Wener L, Citrin CM, Lindenberg R, Kim WS, Zinreich SJ, Molliver ME, Mayberg HS, Moser HW (1987) Adrenoleukodystrophy: correlating MR imaging with CT. *Radiology* 165: 497–504

Dr. P. van Bogaert
Department of Neurology
Hôpital Erasme
Université Libre de Bruxelles
Route de Lennik, 808
B-1070 Brussels
Belgium