

# Different Perceived Foreign Accents in One Patient after Prerolandic Hematoma

D.H. Christoph<sup>a</sup> G.R. de Freitas<sup>a</sup> D.P. dos Santos<sup>a</sup> M.A.S.D. Lima<sup>b</sup>  
A.Q.C. Araújo<sup>a,b</sup> A. Carota<sup>c</sup>

<sup>a</sup>Department of Neurology, Hospital Universitário Clementino Fraga Filho, Universidade Federal do Rio de Janeiro and <sup>b</sup>Department of Neurology, Hospital Barra D'Or, Rio de Janeiro, Brazil; <sup>c</sup>Clinique de Rééducation, Hôpital Cantonal Universitaire, Genève, Suisse

## Key Words

Foreign accent syndrome · Cerebrovascular disorder · Arteriovenous malformation · Aphasia

## Abstract

Foreign accent syndrome (FAS), a rare disorder characterized by the emergence of a new accent perceived as foreign by listeners, is usually reported with left brain damage. We here report the case of a 28-year-old native Brazilian who appeared, to the examiner, to show a North American accent during recovery from Broca's aphasia. The lesion was due to a frontal hematoma. Without referring specifically to speech, we asked 10 independent observers to comment on a videotape of the patient's interview. Seven reported that the patient had a foreign accent, while 3 simply noted a 'strange' accent. The observers did not agree on the origin of the accent, 5 identifying it as Spanish, 1 as German, and 1 as south Brazilian. These findings suggest that FAS is not due to the acquisition of a specific foreign accent, but to impairment of the suprasegmental linguistic abilities (tone, accent, pauses, rhythm, and vocal stress) that make it possible to distinguish native language.

Copyright © 2004 S. Karger AG, Basel

## Introduction

Foreign accent syndrome (FAS), a rare disorder characterized by the emergence of new prosodic features that listeners perceive as a foreign accent, is usually due to left hemisphere lesion or dysfunction [1, 2]. It was first described in 1919 by Pick [3], who reported that his Czech-speaking patient sounded Polish after a left hemisphere stroke.

FAS is a rare consequence of stroke, which generally manifests during aphasia recovery. In a small number of cases, it has been reported after trauma [1]. The emergence of Polish, German, English, Spanish, Nordic, Asian, French, Slavic, Hungarian, Korean, and Irish accents in nonnative speakers has been reported [4]. In most cases, the patient develops a new foreign accent to which they had never been exposed [4]. Currently, there is no cognitive model that adequately explains FAS.

We here report the case of a Portuguese-speaking native Brazilian man who developed a foreign accent after left hemorrhagic stroke. Several independent observers were asked to comment on a videotape of the patient's interview.

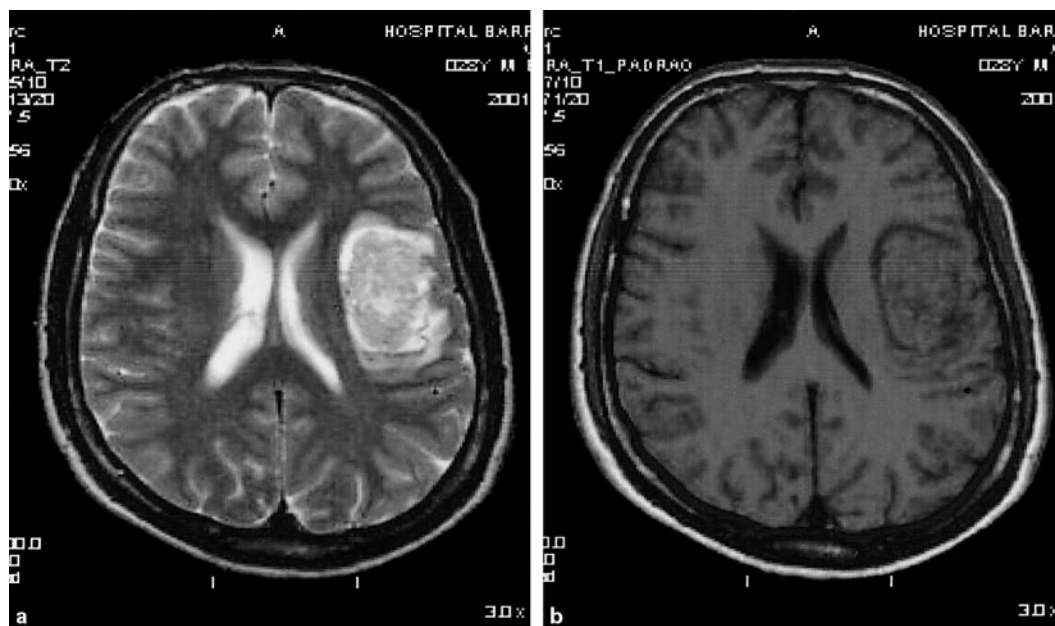
## KARGER

Fax +41 61 306 12 34  
E-Mail [karger@karger.ch](mailto:karger@karger.ch)  
[www.karger.com](http://www.karger.com)

© 2004 S. Karger AG, Basel  
0014-3022/04/0524-0198\$21.00/0

Accessible online at:  
[www.karger.com/ene](http://www.karger.com/ene)

Gabriel R. de Freitas  
Rua Mário Pederneiras 55, 206-I  
Rio de Janeiro, CEP 22261-020 (Brazil)  
Tel./Fax +55 21 2246 2793, E-Mail [gfreitas@ufrj.br](mailto:gfreitas@ufrj.br)



**Fig. 1.** Magnetic resonance imaging showing left cortical-subcortical hyperacute intraparenchymal hemorrhage in the prerolandic area. **a** T<sub>2</sub>-weighted axial image. **b** T<sub>1</sub>-weighted axial image.

## Case Report

A 28-year-old right-handed Portuguese-speaking Brazilian man was admitted to hospital because of sudden headache followed by right hemiparesis and nonfluent aphasia with features of Broca's aphasia. Magnetic resonance imaging showed a hematoma of the prerolandic cortex extending to the underlying white matter. It also involved the insula and frontal operculum. The slightly hyperintense lesion on the T<sub>2</sub>-weighted sequences (fig. 1a) and the isointensity in the T<sub>1</sub>-weighted sequences (fig. 1b) indicated bleeding in the hyperacute stage. A digital angiography revealed a small arteriovenous malformation of the distal middle cerebral artery. There was dramatic recovery from motor deficit and aphasia in the following 2 days, but the examiner (G.R.d.F.) noticed a different accent, which sounded like that of a native of North America speaking Portuguese.

The patient was a native Brazilian who had had no particular accent until this time and was not fluent in any foreign language, despite some ability to read basic texts in English. When questioned about his accent, he was unaware of it, although he said that some nurses had asked him whether he was a foreigner. Examination at this time revealed no aphasic disturbances. Language was fluent, with occasional problems of word finding, but no aphasic errors in visual confrontation naming (Boston Naming Test: score 56, normal score 50–60), verbal fluency in 2 min in the semantic and phonological categories, auditory (Token Test: score 35/36) and written comprehension, repetition, dictated and spontaneous writing, or oral reading. The patient presented some slight difficulty in performing buccofacial motor acts (e.g., blowing out a match or protruding the tongue) on command and by imitation. Oral agility was slightly impaired. The neurological examination was otherwise unremarkable.

The perceived foreign accent was due to a melodic pattern different in rhythm, intonation, and stress accent from his native language. Vowel duration was sometimes prolonged or consonants aspirated and, occasionally, unnecessary pauses separated syllables within the same word. These features were not systematic and the foreign accent was less noticeable during automatic series (counting, naming the months of the year), repetition of meaningless nonreal words, and reading. Affective prosody was spared, as the patient was able to recognize intonations and to express sentences with different emotional content, despite his foreign accent.

One month after stroke onset, the neurological features of FAS completely disappeared. At this time, he complained only of occasional problems in word finding in stressful situations.

### *Comments of Observers*

A 10-min interview consisting of a dialogue between the examiner and the patient, in which the patient described the beginning of his motor symptoms, was videotaped on the 3rd day after admission. The tape was then shown separately to 10 persons living in the same region, who were not aware of the case. All 10 observers (table 1) had a university degree and fluency in at least one foreign language. Five had a foreign (Spanish or French) mother or grandmother (observers 1–5); 2 had lived abroad (South Africa) for a year (observers 6 and 8), and all had traveled abroad more than once. Their age, gender, profession, and the language in which they were fluent were also recorded. They were requested to describe the scene shown on the tape and, if they did not spontaneously report a foreign accent, were specifically asked if the patient had an accent and, if so, which. Seven out of 10 observers reported that the patient had a foreign accent, 3 spontaneously and 4 after being specifically questioned. Five said that the accent was Spanish, 1 German, and the last identified it as typical of

**Table 1.** Characteristics of the observers and their opinions concerning the origin of the foreign accent

Observer	Age, years/sex	Profession	Languages of fluency <sup>1</sup>	Accent
1	55/F	Spanish teacher	English, French, Spanish	Spanish
2	23/F	medical student	English, French	Spanish
3	51/F	architect	English	German
4	21/F	medical student	English	difficulty in speaking
5	21/F	medical student	English	Spanish
6	50/F	mathematics teacher	English	southern region of Brazil
7	24/M	odontology student	English, German	Spanish
8	52/M	naval officer	English	Spanish
9	50/F	engineer	English	difficulty in speaking
10	25/M	engineer	English	difficulty in speaking

<sup>1</sup> Other than Portuguese. M = Male; F = female.

a southern region of Brazil. The remaining 3 observers only reported that the patient had difficulty in speaking (table 1), but they were not able to characterize the problem precisely. One of them said that there were pauses between words.

## Discussion

The aspect of speech that causes a speaker's accent to sound foreign seems to be prosody [2]. Whether FAS should be classified as an aphasic syndrome or as a particular form of dysarthria or speech apraxia is still debated.

The term 'prosody' was introduced by Monrad-Kröhn to describe a 'third element of speech', the other components being vocabulary and grammar. Prosody is the melodic line produced by the variation in pitch, rhythm, and stress of pronunciation that bestows certain semantic and emotional meaning on speech [5]. In 1947, Monrad-Kröhn [6] reported a case of a 30-year-old Norwegian woman who had a frontotemporoparietal lesion and acquired an accent perceived by many listeners as German. The acquired accent was characterized by the adoption of German prosodic patterns, including differences in word level stress and sentence level intonation contours. Monrad-Kröhn used the term 'dysprosody' to classify this clinical disorder of prosody. Although the right hemisphere plays a dominant role in the emotional features of prosody (either production or comprehension), some linguistic aspects of prosody, related to lexical retrieval, sentence construction, and phonetic ordering, are preferentially processed by the left hemisphere [7].

The location of the lesion responsible for FAS may vary, but almost all published cases involved either the left prerolandic motor cortex (Brodmann's area 4) or the left frontal motor association cortex (Brodmann's areas 6 or 44) and/or their subcortical projections [1]. However, FAS has also been reported following a left parietal hemorrhage [4] or corpus callosum infarction [8], and an association with a right hemisphere lesion has been reported in 1 case [9]. Processing of suprasegmental linguistic features in prosody occurs in the middle part of the posterior lateral area of the left precentral gyrus [2]. Others have suggested a role of the dorsolateral inferior frontal gyrus within a corticostriatopallidal-thalamic pathway [10].

Our patient developed FAS as a consequence of acute bleeding in the region of the precentral gyrus with extension to the underlying white matter, in line with lesion localization in previous reports. However, several of the above-mentioned areas or connections might have been involved, since hemorrhagic stroke is often accompanied by a mass effect, causing dysfunction in adjoining structures and making specific clinical correlation difficult.

While some studies have described the sudden acquisition of one specific foreign accent [6, 8, 11, 12], others found that different observers who listened to the same patient at different times had different opinions on the origin of the accent ('pseudoaccent' or 'unlearned foreign accent') [1, 13].

As aphasic changes may evolve very rapidly and FAS is often transient, documenting the syndrome during the acute phase of stroke may be the only way to ensure that all observers are listening to the same phenomenon. In our study, we formally assessed accent perception by dif-

ferent independent observers at the same time point during acute stroke. The facts that the observers and the examiner interpreted the foreign accent as being of different origins (North American, Spanish, German, or south of Brazil) and that the patient was not fluent in any foreign languages before stroke support the hypothesis that FAS is due to some dysbalance in the fine tuning of pre-programmed speech movements necessary for prosodic features specific to the native language. This suggests that FAS does not reflect the acquisition of any particular foreign accent, but rather of a 'generic foreign accent' [1]. Although we did not perform a detailed acoustic and

phonetic analysis of the patient's speech, the disagreement between several listeners about the foreign origin of the accent probably reflects the fact that the speech errors were not stereotyped.

Our case is not consistent with the adoption of a second language already known by the patient [3, 14], and cases in which this does occur could correspond to a different category of FAS, in which prelearned accents are disinhibited. We have been unable to find any previous reports of native Portuguese-speaking patients developing FAS, but we think that this may be due to limited knowledge about the disorder.

## References

- 1 Kurowski KM, Blumstein SE, Alexander M: The foreign accent syndrome: A reconsideration. *Brain Lang* 1996;54:1–25.
- 2 Takayama Y, Sugishita M, Kido T, Ogawa M, Akiguchi I: A case of foreign accent syndrome without aphasia caused by a lesion of the left precentral gyrus. *Neurology* 1993;43:1361–1363.
- 3 Pick A: Über Änderungen des Sprachcharacters als Begleiterscheinung aphasischer Störungen. *Z Gesamte Neurol Psychol* 1919;54:230–241.
- 4 Roth EJ, Fink K, Cherney LR, Hall KD: Reversion to a previously learned foreign accent after stroke. *Arch Phys Med Rehabil* 1997;78:550–552.
- 5 Ross DE, Mesulam MM: Dominant language functions of the right hemisphere? Prosody and emotional gesturing. *Arch Neurol* 1979;36:144–148.
- 6 Monrad-Kröhn GH: Dysprosody or altered 'melody of language'. *Brain* 1947;70:405–415.
- 7 Ross ED: Prosody and brain lateralization: Fact vs. fancy or is it all semantics? *Arch Neurol* 1988;45:338–339.
- 8 Hall DA, Anderson CA, Filley CM, Newcombe J, Hughes RL: A French accent after corpus callosum infarct. *Neurology* 2003;60:1551–1552.
- 9 Dankovicova J, Gurd JM, Marshall JC, et al: Aspects of non-native pronunciation in a case of altered accent following stroke (foreign accent syndrome). *Clin Ling Phonet* 2001;15:195–218.
- 10 Moonis M, Swearer JM, Blumstein SE, et al: Foreign accent syndrome following a closed head injury: Perfusion on single photon emission tomography with normal magnetic resonance imaging. *Neuropsychiatry Neuropsychol Behav Neurol* 1996;9:272–279.
- 11 Graff-Radford NR, Cooper WE, Colsher PL, Damasio AR: An unlearned foreign 'accent' in a patient with aphasia. *Brain Lang* 1986;28:86–94.
- 12 Ardila A, Rosselli M, Ardila O: Foreign accent: An aphasic epiphenomenon? *Aphasiology* 1988;2:493–499.
- 13 Blumstein SE, Alexander MP, Ryalls JH, Katz W, Dworetzky B: On the nature of the foreign accent syndrome: A case study. *Brain Lang* 1987;31:215–244.
- 14 Seliger GM, Abrams GM, Horton A: Irish brogue after stroke. *Stroke* 1992;23:1655–1656.

Copyright: S. Karger AG, Basel 2004. Reproduced with the permission of S. Karger AG, Basel. Further reproduction or distribution (electronic or otherwise) is prohibited without permission from the copyright holder.