

A carcinoid tumor mimicking an isolated intracranial meningioma

Case report

ERIC M. DESHAIES, M.D., MATTHEW A. ADAMO, M.D., JIANG QIAN, M.D., PH.D.,
AND DARRYL A. DIRISIO, M.D.

Department of Surgery, Division of Neurosurgery; and Department of Pathology, Albany Medical Center, Albany, New York

✓ This 79-year-old woman presented with progressively worsening dementia, abulia, flat affect, urinary incontinence, and profuse watery diarrhea. Results of computerized tomography and magnetic resonance studies indicated an extraaxial, dural-based mass compressing the right frontal lobe and consistent with a convexity meningioma. A right frontal craniotomy was performed and the dural-based mass was resected. Histopathological features on immunostaining of the lesion were consistent with a carcinoid tumor (low-grade neuroendocrine carcinoma). Further evaluation revealed no primary carcinoid tumor in the foregut from which they typically originate. The authors concluded that this intracranial carcinoid tumor was the primary lesion despite its unusual location and that it should be included in the differential diagnosis of dural-based, extraaxial brain lesions.

KEY WORDS • carcinoid syndrome • carcinoid tumor • extradural tumor • meningioma • neuroendocrine carcinoma

CARCINOID tumors (neuroendocrine carcinomas) arise from Kulchitsky cells, a type of biogenic amine-secreting enterochromaffin cell located in the crypts of Lieberkuhn of the intestinal lumen. These tumors commonly arise from the foregut and metastasize to the breasts, lungs, and brain but rarely to the meninges. Patients with carcinoid tumors can present with flushing and diarrhea caused by elevated nonphysiological levels of serotonin or other biogenic amines secreted from these enterochromaffin cell tumors; this clinical entity is called “carcinoid syndrome.” Because these lesions are indolent and are sought only when there is a high index of suspicion for a carcinoid tumor, it is not uncommon for the primary carcinoid tumor to go undetected until a CT scan or an ultrasonogram demonstrates metastatic disease. Once the diagnosis is made, surgical, chemotherapeutic, and radiotherapeutic means can be used to treat these tumors.

We present the case of an isolated right frontal convexity carcinoid tumor that demonstrated radiographic characteristics consistent with a meningioma. The histopathological diagnosis of this lesion was a carcinoid tumor (low-grade neuroendocrine carcinoma), however, and a postoperative metastatic evaluation indicated that the intracranial tumor was the only lesion.

Case Report

History and Examination. This 79-year-old woman presented to the hospital for a dementia workup. At her base-

line, she was an effervescent, jovial individual who was very particular about her hygiene. During the course of the past few months, she had become anhedonic, unhygienic, and abulic and had recently developed severe watery diarrhea and urinary incontinence. Her recent medical history was significant for resection of both a right scalp basal cell carcinoma and a colon polyp. A review of her systems was negative for nausea, vomiting, headaches, weight loss, flushing, wheezing, or signs of cardiac conditions characteristic of carcinoid syndrome.

Neurological examination demonstrated fluent speech when prompted and a flat affect. She was unkempt and smelled of urine. A left-sided extinction to light touch was present without hemisensory neglect. No focal motor or sensory deficits could be elicited; her neurological and non-neurological examinations were unremarkable. These examination findings were consistent with frontal lobe dysfunction.

The initial noncontrast-enhanced head CT scan demonstrated a heterogeneous, dural-based, extraaxial mass with surrounding edema compressing the right frontal lobe (images not shown). A T₁-weighted MR image demonstrated an isolated, heterogeneous, Gd-enhancing, extraaxial mass measuring approximately 5 × 5 × 5 cm with a prominent dural-based tail and compressing the right frontal lobe (Fig. 1 *left* and *center*). A T₂-weighted MR image demonstrated the heterogeneity of the mass and surrounding edema as well as multiple cystic components (Fig. 1 *right*). These radiographic studies were indicative of a high-grade meningioma.

Clinical Course. The mass was resected via a right frontal craniotomy. Intraoperatively, the skull overlying the le-

Abbreviations used in this paper: CNS = central nervous system; CT = computerized tomography; MR = magnetic resonance.

A carcinoid tumor mimicking an isolated intracranial meningioma

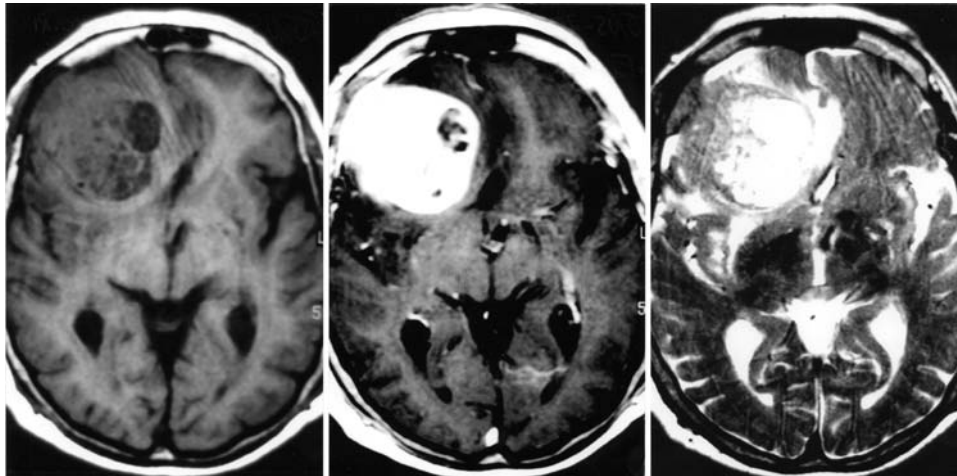


FIG. 1. Axial T₁-weighted MR images without (*left*) and with (*center*) Gd enhancement demonstrating an extraaxial mass. *Right*: Axial T₂-weighted MR image.

sion was hyperostotic and the mass was rubbery, well circumscribed, and olive brown. The tumor was resected and the dural-based vascular pedicle was ligated. Postoperatively, a contrast-enhanced CT scan of the chest, abdomen, and pelvis and an octreotide scintigraphy study demonstrated neither a primary carcinoid tumor nor any evidence of metastatic carcinoid disease. An isolated colonic lesion was found by colonoscopy, however, and histopathological studies confirmed that this lesion was a primary adenocarcinoma with no carcinoid features (not shown).

After resection of the intracranial carcinoid tumor, the patient's copious watery diarrhea resolved and she received octreotide chemotherapy for any residual carcinoid tumor not detected during the metastatic workup. She died 6 weeks later from unknown complications and the family refused an autopsy.

Histopathological Study and Immunostaining Techniques. A brain biopsy specimen was routinely processed and stained with H & E. The carcinoid tumor (low-grade neuroendocrine carcinoma) consisted of variable-sized nests and groups of tumor cells. Invasion of brain parenchyma in the form of irregular fingerlike projections was evident at the brain-tumor interface (Fig. 2A). Tumor cells were relatively uniform with inconspicuous nucleoli and "salt-and-pepper" chromatin (Fig. 2B). There was no significant nuclear pleomorphism or mitotic activity. The epithelial nature of the tumor was indicated by staining positive for cytokeratin Cam5.2 (Fig. 2C), whereas the neuroendocrine nature was demonstrated by staining positive for synaptophysin (Fig. 2D). The tumor also stained positive for cytokeratin AE1/AE3, epithelial membrane antigen, chromogranin, and neuron-specific enolase (not shown), further supporting the diagnosis of a carcinoid tumor.

Discussion

There have been reported cases of carcinoid tumors metastasizing to the brain parenchyma^{1-5,7-10,12-21,23,24} and of an identified primary carcinoid lesion elsewhere in the body metastasizing to an existing meningioma.²² Case reports, however, of carcinoid tumors metastasizing to the lepto-

ninges are sparse. In 1986 Patchell and Posner¹⁷ reviewed the cases of 219 patients with carcinoid tumors at Memorial Sloan-Kettering Cancer Center and found that 33 patients had developed neurological sequelae from metastatic lesions to the brain (13 patients), spinal epidural space (14 patients), leptomeninges (one patient), and peripheral nerves (five patients). The authors also showed that in patients with metastatic carcinoid tumors, approximately 29% have CNS lesions.

Prior to this present case report, there had been only one reported case of a carcinoid tumor metastatic to the CNS without a detectable extracranial primary lesion² and another case of a primary meningioma.⁶ The rare occurrence of a carcinoid tumor mimicking a meningioma indicates that the index of suspicion should be high for an indolent carcinoid tumor in patients presenting with radiographic evidence of a dural-based mass and a concurrent history of carcinoid-like symptoms. In the patient in the present case, her

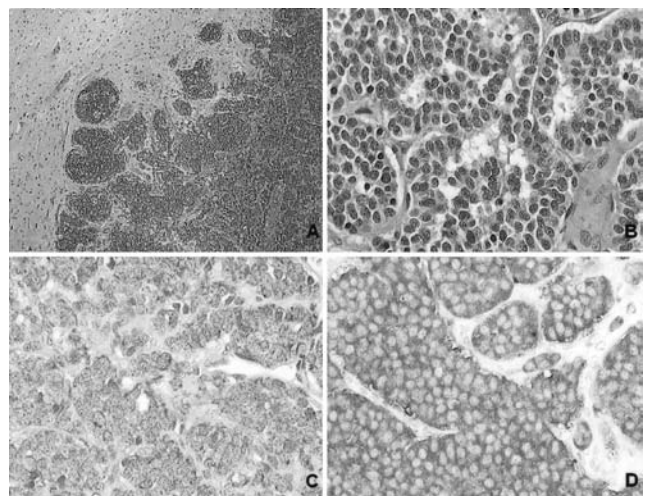


FIG. 2. Photomicrographs of a dural-based carcinoid tumor. A: Low-power view. B: High-power view. Tumor cells stained immunohistochemically. H & E (A and B), cytokeratin Cam5.2 (C), synaptophysin (D). Original magnification $\times 5$ (A), $\times 40$ (B-D).

symptoms could be explained by a large frontal lobe mass with the exception of the watery diarrhea; she did not exhibit any other symptoms consistent with carcinoid syndrome. We had expected the lesion to be a convexity meningioma based on the presence of a prominent dural-based tail on Gd-enhanced MR imaging studies. The diarrhea ceased postoperatively, presumably because the resected intracranial lesion had been the primary source of serotonin and biogenic amine secretion. These chemicals cause diarrhea and other symptoms characteristic of carcinoid syndrome.

Postoperative evaluation for metastatic carcinoid disease included urine 5-hydroxyindoleacetic acid and serum 5-hydroxytryptophan levels (both of which are serotonin metabolites produced by carcinoid tumors) and an octreotide study. Results of both the serotonin metabolites study and the octreotide study were normal postoperatively, indicating that the intracranial dural lesion was the primary carcinoid tumor rather than a metastatic lesion from elsewhere in the body. We did not conduct preoperative serotonin metabolite studies because a carcinoid tumor was not suspected at the time.

Once a diagnosis of carcinoid tumor has been established, appropriate treatment includes resection, radiotherapy, and chemotherapy with octreotide analogs. There are only a few cases concerning the prognosis of metastatic carcinoid tumors in the CNS, but in a report by Danikas, et al.,³ they described a 5-week survival in a patient with a poorly differentiated rectal carcinoid tumor that had diffusely metastasized to the lungs, pancreas, kidney, and brain. The direct cause of this patient's death was cardiac arrhythmia, most likely associated with abnormally high levels of biogenic amines from the heavy tumor burden. As with most other tumors, a better prognosis is associated with lower-grade carcinoid tumors, earlier detection, and surgical debulking followed by octreotide chemotherapy.

Conclusions

In summary, this case demonstrates the importance of maintaining a high index of suspicion for an intracranial carcinoid tumor in any patient who presents with carcinoid-like symptoms or who has a history of carcinoid syndrome and radiographic evidence of an intracranial mass consistent with a meningioma or a dural-based lesion. In such situations, the neurosurgeon may be the first to diagnose this indolent and deadly metastatic neuroendocrine cancer.

References

- Borowska-Lehman J, Rzepko R, Chrostowski L, et al: Metastatic carcinoid tumour in the brain. *Folia Neuropathol* 32:265–268, 1994
- Butler EG, Stark RJ, Siu K, et al: Cerebral deposits of carcinoid tumour. *Clin Exp Neurol* 26:213–217, 1989
- Danikas D, Theodorou SJ, Matthews WE, et al: Unusually aggressive rectal carcinoid metastasizing to larynx, pancreas, adrenal glands, and brain. *Am Surg* 66:1179–1180, 2000
- Gowitt GT, Mirra SS: Malignant carcinoid causing spinal cord compression. *Neurosurgery* 17:801–806, 1985
- Huang MC, Lee LS, Ho DM, et al: A metastatic pituitary carcinoid tumor successfully treated with gamma knife radiosurgery. *Zhonghua Yi Xue Za Zhi* 64:414–418, 2001
- Huang PS, Oz M: Malignant carcinoid tumor metastatic to the dura mater simulating a meningioma. *Neurosurgery* 29:449–452, 1991
- Hussein AM, Feun LG, Savaraj N, et al: Carcinoid tumor presenting as central nervous system symptoms. Case report and review of the literature. *Am J Clin Oncol* 13:251–255, 1990
- Kanda H, Hachisuka K, Yamaguchi A, et al: [Two cases of carcinoid tumor of the stomach and a collective review of the Japanese literature.] *Gan No Rinsho* 32:819–825, 1986 (Jpn)
- Karkos J: [Morphological picture of intestinal carcinoid metastasis to the cerebellum.] *Neuropatol Pol* 9:231–237, 1971 (Pol)
- Kon T, Hara N, Su M, et al: [Multiple brain metastasis of bronchial atypical carcinoid: unusual MR imaging, case report.] *No Shinkei Geka* 25:815–818, 1997 (Jpn)
- Kovachev D, Ruseva V: [Carcinoid of the stomach with metastases into the dura mater.] *Vutr Boles* 15:98–103, 1976 (Bul)
- Martinez Martinez B, Juarez Alonso S, Alba Losada J, et al: Carcinoides de timo con metastasis multiples. A proposito de un caso. *Med Clin* 75:207–210, 1980
- Nakamura Y, Shimokawa S, Ishibe R, et al: Pulmonary carcinoid found in a patient who presented with initial symptoms of brain metastasis: report of a case. *Surg Today* 31:510–512, 2001
- Nida TY, Hall WA, Glantz MJ, et al: Metastatic carcinoid tumor to the orbit and brain. *Neurosurgery* 31:949–952, 1992
- Ohnsmann A, Sachsenheimer W: Intrazerebrale Metastasierung eines Bronchuskarzinoids. *Neurochirurgia* 35:160–162, 1992
- Ozawa T, Terabayashi T, Takahashi H, et al: Metastatic intracranial carcinoid with immunohistochemical observation. Case report. *J Neurosurg* 73:130–134, 1990
- Patchell RA, Posner JB: Neurologic complications of carcinoid. *Neurology* 36:745–749, 1986
- Raymond PL, Balaa MA: Diplopia and diarrhea: ileal carcinoid metastatic to the central nervous system. *Am J Gastroenterol* 87:240–243, 1992
- Sakamoto K, Masuzaki H, Fujimura N, et al: [A case of Cushing syndrome caused by ACTH producing atypical lung carcinoid tumor.] *Nippon Naibunpi Gakkai Zasshi* 68:743–751, 1992 (Jpn)
- Schiffman FJ, Barnard NJ: Carcinoid tumor of the gastrointestinal tract with metastases to the brain. *Arch Intern Med* 142:1717–1719, 1982
- Smets G, Warson F, Dehou MF, et al: Metastasizing neuroendocrine carcinoma of the larynx with calcitonin and somatostatin secretion and CEA production, resembling medullary thyroid carcinoma. *Virchows Arch A Pathol Anat Histopathol* 416:539–543, 1990
- Smith TW, Wang SY, Schoene WC: Malignant carcinoid tumor metastatic to a meningioma. *Cancer* 47:1872–1877, 1981
- Takano S, Saitoh M, Miyasaka Y, et al: [Bronchial carcinoid tumor with multiple brain metastasis.] *No Shinkei Geka* 22:343–348, 1994 (Jpn)
- Valli M, Fabris GA, Dewar A, et al: Atypical carcinoid tumour of the thymus: a study of eight cases. *Histopathology* 24:371–375, 1994

Manuscript received March 15, 2004.

Accepted in final form June 6, 2004.

Address reprint requests to: Eric M. Deshaies, M.D., Division of Neurosurgery, Albany Medical Center, Suite A300, 47 New Scotland Avenue, MC61, Albany, New York 12208. email: deshaie@mail.amc.edu.