

V. Lucivero • D.M. Mezzapesa • M. Petruzzellis • A. Carella • P. Lamberti • F. Federico

Ischaemic stroke in progressive systemic sclerosis

Received: 2 April 2004 / Accepted in revised form: 24 July 2004

Abstract Progressive systemic sclerosis (PSS) or scleroderma is a multisystem disease affecting the skin, lungs, myocardium, kidneys and gastrointestinal tract. Primary involvement of cerebral arteries in PSS has been reported but is very rare. A 61-year-old woman suffering from scleroderma for six years was hospitalised for two subsequent episodes of transient acute dysarthria and left hemiparesis. After five hours from the first onset of symptoms, she was submitted to brain magnetic resonance (MR) protocol that showed a right subinsular ischaemic lesion and whole right middle cerebral artery (MCA) territory hypoperfusion. Intracranial and epiaortic MR angiography reported a focal stenosis in the M2 portion of MCA. She was immediately treated with i.v. high dose steroids and oral acetylsalicylic acid. At one-month follow up, MR findings were confirmed. We have documented a cerebral infarct in a PSS patient. In our opinion, the ischaemic stroke was caused by a localised autoimmune angiopathy.

Key words Stroke • Progressive systemic sclerosis • Scleroderma • Magnetic resonance imaging

Introduction

Progressive systemic sclerosis (PSS) is a multisystem disorder characterised by inflammatory, vascular and fibrotic changes of the skin (scleroderma) and a variety of internal organs, most notably the gastrointestinal tract, lungs, heart and kidney. Unlike other collagen diseases, the nervous system is rarely involved in PSS and the real incidence and prevalence of nervous system dysfunction in PSS are unknown. Reviewing the literature data, neurological manifestations mainly consist of peripheral neuropathy and muscle changes ranging from 0.8% to 5.6% [1–4]. TIA or stroke are uncommon complications of PSS and have been associated to renal failure and severe hypertension [5]. The pathogenesis of PSS is not completely understood, although vascular or and dysimmune mechanisms are hypothesised. According to the vascular hypothesis, endothelial changes, probably an abnormal proliferation of endothelial cells in the intima [6] with subsequent microangiopathy, may increase the platelet aggregation and cause peripheral neuropathy or cerebrovascular disease.

Primary involvement of Willis cerebral arteries in PSS has been reported but is very rare, and is probably due to the paucity of adventitial fibrous tissue and limited fibrous elements in normal media [7]. Nevertheless, vascular and dysimmune mechanisms may produce cerebral ischaemia in the absence of systemic atherosclerosis or any vascular risk factors [4, 8].

Case description

A 61-year-old right-handed white woman was admitted to our department for three hours after the onset of transient acute dysarthria and left hemiparesis. At admission, three hours later, the neurological examination was normal. Past

V. Lucivero • D.M. Mezzapesa • M. Petruzzellis • A. Carella
P. Lamberti • F. Federico (✉)
Department of Neurological and Psychiatric Sciences
University of Bari
Piazza G. Cesare 12, I-70124 Bari, Italy
e-mail: francescofederico@neurol.uniba.it

medical history was significant for headache and PSS. PSS was diagnosed six years before because of sclerodactyly, Raynaud’s phenomenon, oesophageal dysmotility and interstitial pulmonary fibrosis. She was taking 5 mg oral prednisone daily. After five hours from symptoms onset, although symptom-free, she was submitted to brain magnetic resonance imaging (MRI), diffusion weighted imaging (DWI) and perfusion weighted imaging (PWI) that showed a right subinsular ischaemic lesion on DWI and whole right middle cerebral artery (MCA) territory hypoperfusion (Fig. 1a,c,d). Intracranial and epiaortic magnetic resonance angiography (MRA) reported a severe stenosis in the M2 portion tract of right of MCA (Fig. 1b). Transcranial Doppler (TCD) showed decreased mean flow velocity (25 cm/s) at 40 mm depth compatible with the right M2. Three hours later she again developed dysarthria and left hemiparesis, and so underwent a second MR examination, that evidenced another ischaemic lesion in right parietal lobe on DWI (Fig. 2a,b). She immediately received i.v. high dose methyl prednisolone (1 g for 5 days) and 325 mg oral acetylsalicylic acid (ASA) with clinical remission within 24 h. On the third day she under-

went to lumbar puncture with normal cerebrospinal fluid (CSF) examination findings (cell count, glucose, protein, lactate and virology). Isoelectric focusing of CSF evidenced G paraproteinemia. Transthoracic echocardiography showed left ventricle hypertrophy. The chest X-rays confirmed the interstitial pulmonary involvement. The epiaortic duplex ultrasound was normal. After seven days she was still asymptomatic and the FLAIR images (Fig. 2c,d) and DWI examination confirmed the right fronto-insular and right parietal ischaemic lesions. On PWI whole right MCA territory hypoperfusion was still present, as the M2 severe stenosis on MRA. At TCD the mean velocity of the MCA was slightly increased compared with the first examination, passing from 30 cm/s to 50 cm/s. She was taking 50 mg oral prednisone and 325 mg oral ASA. Serum chemistry evidenced only hypercholesterolaemia. Scl 70, ANA and c-ANCA were present. Antiphospholipid antibodies were absent. Homocysteine and VDRL were normal. After one month, she was still asymptomatic, and the MR examination confirmed the ischaemic lesions and the focal M2 stenosis. The home therapy was 325 mg oral ASA and 10 mg prednisone.

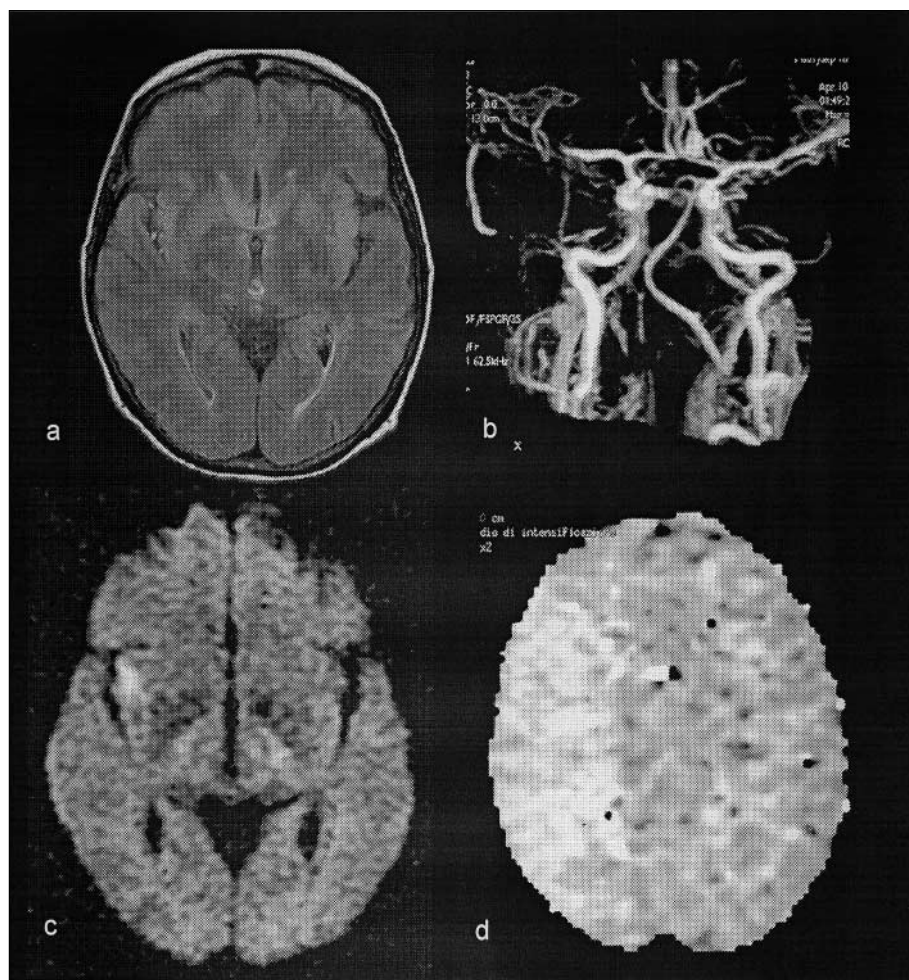


Fig. 1 MR examination 5 hours after symptoms onset: (a) FLAIR images were normal; (b) MR angiography revealed a severe stenosis in the M2 portion of MCA; (c) DWI showed acute subinsular ischaemic lesion; and (d) PWI showed a whole right MCA territory hypoperfusion

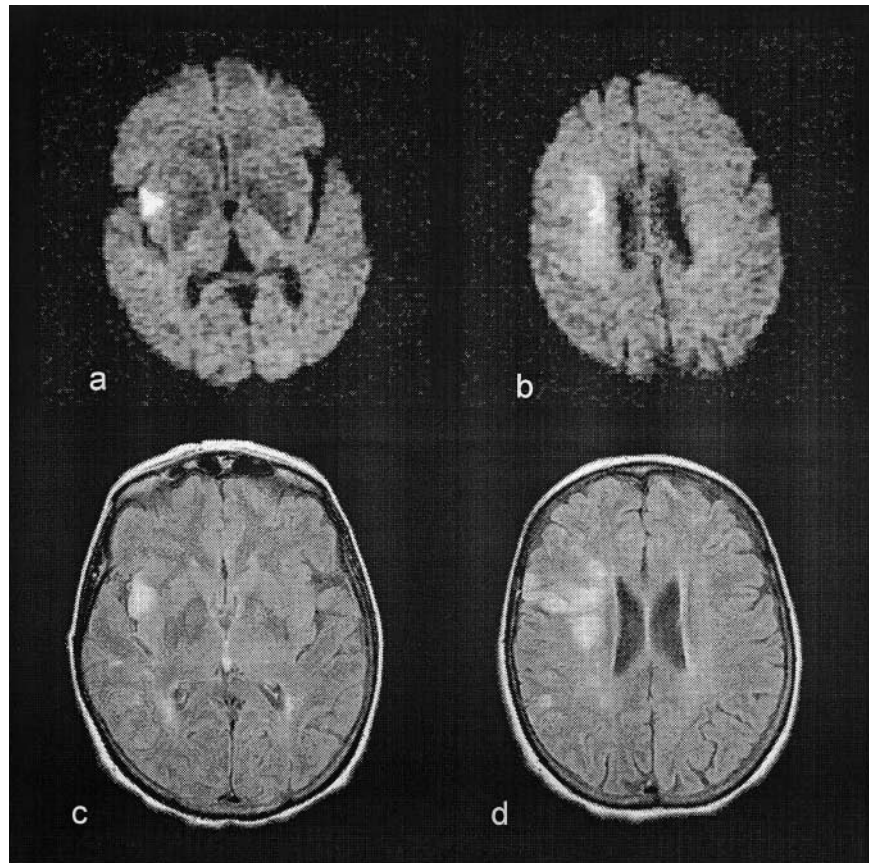


Fig. 2 DWI examination 8 hours after symptoms onset evidenced another parietal ischaemic lesion (**a, b**); FLAIR images 7 days after symptoms onset confirmed the subinsular and parietal lesions (**c, d**)

Discussion

The cerebral infarct is a rare complication of PSS. It is generally associated with clear vascular risk factors as severe hypertension and with prothrombotic diseases such as chronic renal failure. To date we have found only a few reports of cerebrovascular disease in subjects with PSS [1, 5–10]. Two of these have been published in a pre-CT scan era and only one was supported by pathology showing cerebral infarction and carotid arteritis [1]. Estey et al. have reported a PSS patient presenting subacute encephalopathy with diffuse narrowing of the branches of middle cerebral arteries on angiography and lumbar puncture suggestive for an inflammatory state [6]. In a recent publication Das et al. described a case of a PSS female patient who suffered of right hemiparesis and aphasia with MRI showing multiple infarcts; she was not hypertensive and renal function was normal, but neither a study of the cerebral vasculature nor rachicentesis were performed [10]. Kanzato et al. have described a case of localised scleroderma associated with an ischaemic stroke which progressed over a few months; MRI evidenced a large lesion in the territory of right MCA and MRA showed a focal stenosis of the M2 insular portion of the same artery [7]. In few published reports there are evidences in favour of a

vasculitic genesis of cerebral infarcts in PSS patients without vascular risk factors [1, 5–7].

We present the first report of this complication in a PSS patient almost certainly due to Willis cerebral artery involvement, well documented with non-conventional MR techniques. In our patient the cerebral infarct occurred acutely as a transitory and mild neurological deficit. The MR examination evidenced a partial infarct of MCA artery secondary to a stenosis of the M2 tract. Symptoms completely reversed with high dose corticosteroids treatment. The CSF examination performed three days after the onset was normal. The presence of two ischemic lesions was clearly demonstrated with MR examination. The infarcts were secondary to a severe hypoperfusion in the territory of the MCA. In our opinion MCA stenosis was caused by a localised autoimmune angiopathy. The evidence supporting this hypothesis is: (a) no vascular risk factor was present except for hypercholesterolaemia that was firstly documented during the hospitalisation; (b) the M2 stenosis of right MCA was not associated to MRA atherosclerotic abnormality in the extracranial and intracranial cerebral arteries; (c) echocardiography was unable to detect embolic sources, only showing left ventricular hypertrophy directly due to PSS; and (d) an apparent good response to high-dose corticosteroid treatment as suggested by the clinical and ultrasonographic improvement. On the contrary, some ele-

ments disagree with the vasculitic hypothesis: (a) the intracranial MRA findings, were not typical of inflammatory angiopathy; (b) normal CSF analysis disagree with the vasculitic hypothesis. Nevertheless we hypothesise the primary involvement of a single cerebral artery, which explains the normal CSF examination and the atypical MRA findings. In conclusion we have documented a cerebral infarct in a sclerodermic patient due to severe MCA stenosis probably of autoimmune aetiology.

Sommario *La sclerodermia (SD) è una malattia multisistemica che colpisce la pelle, i polmoni, i reni, il miocardio e il sistema gastroenterico. Il coinvolgimento primario delle arterie cerebrali è stato descritto, ma è molto raro. Riportiamo il caso di una donna di 61 anni, affetta da sclerodermia dall'età di 6 anni, ricoverata per due episodi transitori di disartria ed emiparesi sinistra insorti acutamente. L'esame di risonanza magnetica (RM) ha evidenziato nelle sequenze pesate in diffusione una lesione subinsulare destra ed una ipoperfusione nell'intero territorio della arteria cerebrale media (ACM) destra. L'angio-RM ha mostrato una stenosi del tratto M2 dell'ACM destra. È stata trattata con steroidi ad alte dosi e acido acetilsalicilico. Al follow-up dopo 30 giorni i reperti di RM erano confermati. Abbiamo, quindi, documentato un infarto cerebrale in una paziente con SD. Secondo la nostra ipotesi l'ictus è stato determinato da un'angiopatia autoimmune localizzata.*

References

1. Lee JE, Haynes JM (1967) Carotid arteritis and cerebral infarction due to scleroderma. *Neurology* 17:18–22
2. Gordon RM, Silverstein A (1970) Neurologic manifestations in progressive systemic sclerosis. *Arch Neurol* 22:126–134
3. Hietarinta M, Lassila O, Hietaharju A (1994) Association of anti-U1RNP and anti-Scl-70-antibodies with neurological manifestations in systemic sclerosis (scleroderma). *Scand J Rheumatol* 23:64–67
4. Averbuch-Heller L, Steiner I, Abramsky O (1992) Neurologic manifestations of progressive systemic sclerosis. *Arch Neurol* 49: 1292–1295
5. Pathak R, Gabor AJ (1991) Scleroderma and central nervous system vasculitis. *Stroke* 22:410–413
6. Estey E, Lieberman A, Pinto R, Meltezer M, Ransohoff J (1979) Cerebral arteritis in scleroderma. *Stroke* 10:595–597
7. Kanzato N, Matsuzaki T, Komine Y, Saito M, Yoshio T, Suchara M (1999) Localized scleroderma associated with progressing stroke. *J Neurol Sci* 163:86–89
8. Chung MH, Sum J, Morrell MJ, Horoupian DS (1995) Intracerebral involvement in scleroderma en coup de sabre: report of a case with neuropathologic findings. *Ann Neurol* 37:679–681
9. Nishida A, Kaiya H, Uematsu M, Maeda M, Mori S, Wakabayashi S (1990) Transient global amnesia and Raynaud's phenomenon in scleroderma. *Acta Neurol Scand* 81:550–552
10. Das CP, Prabhakar S, Lal V, Kharbanda PS (2002) Scleroderma, stroke, optic neuropathy: a rare association. *Neurol India* 50:504–507