

Nonmyeloablative Allogeneic Bone Marrow Transplantation for Treatment of Myelodysplastic Syndrome Complicated by Recent Intracerebral Hemorrhage

Korenori Ohtsubo,¹ Ken Takase,¹ Koji Nagafuji,^{1*} Hideho Henzan,¹ Tetsuya Tanimoto,¹ Takahiro Fukuda,¹ Toshihiro Miyamoto,¹ Shoichi Inaba,² and Mine Harada¹

¹Medicine and Biosystemic Science, Kyushu University Graduate School of Medical Sciences, Fukuoka, Japan

²Blood Transfusion Service, Kyushu University Hospital, Fukuoka, Japan

A patient with intracerebral hemorrhage is considered ineligible for hematopoietic stem cell transplantation (HSCT). We report a 49-year-old woman with myelodysplastic syndrome (MDS) complicated by refractoriness to platelet transfusion and intracerebral hemorrhage, who underwent allogeneic bone marrow transplantation from an HLA-identical unrelated male donor. Nine days before the scheduled transplantation, she developed dysarthria and right hemiparesis; computed tomography (CT) of the brain disclosed an acute hematoma in the left parietal lobe exceeding 3 cm in diameter. She underwent conditioning with reduced-intensity, including fludarabine (30 mg/m²/day on days –8 to –3), busulfan (4 mg/kg/day on days –6 and –5), and total body irradiation (4 Gy on day –2). Two weeks after transplantation, dysarthria and right hemiparesis began to resolve, and CT showed spontaneous resolution of the hematoma. Simultaneously, engraftment was confirmed. Thus, recent stroke may be not an absolute contraindication for HSCT. *Am. J. Hematol.* 77:400–404, 2004. © 2004 Wiley-Liss, Inc.

Key words: bone marrow transplantation; intracerebral hemorrhage; myelodysplastic syndrome; MDS; refractoriness to platelet transfusion

INTRODUCTION

Cerebrovascular complications give rise to significant morbidity and mortality after allogeneic hematopoietic stem cell transplantation (HSCT). These include intracranial hemorrhage reflecting severe thrombocytopenia and infarction or hemorrhage secondary to fungal infection. Bone marrow transplant patients with stroke have shown over 50% mortality, and surviving patients have shown serious disability [1]. Because conventional myeloablative pre-transplant conditioning increases the tendency toward bleeding, patients with acute or recent cerebrovascular complications are not considered to be eligible for allogeneic HSCT. However, for thrombocytopenic patients with malignant hematologic disease who are refractory to platelet transfusion, HSCT probably is the only potentially curative therapeutic option irrespective of the presence of stroke.

A new approach to conditioning, nonmyeloablative stem cell transplantation (NST) can reduce regimen-related toxicity (RRT) and transplant-related mortality (TRM). NST, which has been used increasingly for treatment of hematologic malignancies, can be used in elderly patients and patients with major organ dysfunctions who are at high risk for TRM after conventional HSCT [2].

We describe herein our experience with allogeneic NST from an HLA-matched unrelated donor for a patient

*Correspondence to: Dr. Koji Nagafuji, Medicine and Biosystemic Science, Kyushu University Graduate School of Medical Sciences, 3-1-1 Maidashi, Higashi-ku, Fukuoka 812-8582, Japan.
E-mail: nagafuji@intmed1.med.kyushu-u.ac.jp

Received for publication 5 April 2004; Accepted 27 June 2004

Published online in Wiley InterScience (www.interscience.wiley.com).
DOI: 10.1002/ajh.20213

with myelodysplastic syndrome (MDS), who developed refractoriness to platelet transfusions and had an intracerebral hemorrhage (ICH), shortly before NST.

CASE REPORT

A 49-year-old woman with MDS was referred to us in September 2003 for allogeneic bone marrow transplantation (BMT) from an HLA-matched unrelated donor. She had been thrombocytopenic since 1980. In November 2000, she was diagnosed with refractory anemia (RA) and then became dependent on transfusions of red blood cells and platelets. Subsequent secondary hemochromatosis resulted in congestive heart failure, liver dysfunction, and diabetes mellitus. She developed a persistent bleeding tendency caused by severe thrombocytopenia refractory to platelet transfusions. She had developed multispecific anti-HLA antibodies, necessitating transfusions of HLA-matched platelets to maintain her platelet count above critical level. In August 2003, she was found to have spontaneous subdural hematomas in the parietal, subtentorial, and lumbosacral regions. At the time of admission, the lumbosacral subdural hematoma impaired the patient's mobility. Her performance status was 3 according to the Eastern Cooperative Oncology Group (ECOG) scale. Her peripheral blood examination showed pancytopenia: hemoglobin, 4.8 g/dL; white blood cell (WBC) count, $0.86 \times 10^9/\text{L}$ including 29% mature neutrophils; and platelet count, $2.0 \times 10^9/\text{L}$. Her prothrombin time and activated partial thromboplastin time were 13.0 sec (normal range, 11–14 sec) and 33.8 sec (normal range, 24–38 sec), respectively. Serum ferritin concentrations greatly increased (9,229 ng/mL). In an attempt to improve the response to platelet transfusion, high-dose intravenous immunoglobulin (20 g/day) was administered for 5 consecutive days, but refractoriness showed no abatement. Just before starting pre-transplant nonmyeloablative conditioning, at –9 days preceding the scheduled BMT, she

suddenly developed dysarthria. Computed tomography (CT) scans of the brain revealed an acute intracranial hematoma over 3 cm in diameter in the left parietal lobe (Fig. 1). More than 10 units of platelets from random donors as well as HLA-matched donors were transfused, but post-transfusion augmentation of platelets was inadequate. Dysarthria and right hemiparesis gradually worsened, and performance status was deteriorated to 4. After considering whether the patient could tolerate the pre-transplant conditioning, we decided upon perform allogeneic BMT preceded by a reduced-intensity conditioning regimen including fludarabine ($30 \text{ mg}/\text{m}^2$ daily for 6 days (day –8 to day –3), busulfan ($4 \text{ mg}/\text{kg}$ daily for 2 days (day –6 to day –5), and total body irradiation (TBI) (4 Gy in 2 fractions of 2 Gy, both on day –2). Tacrolimus (FK506) and short-term methotrexate were used for prophylaxis against graft-versus-host-disease (GVHD). Bone marrow cells (2.68×10^8 nucleated cells/kg) from an unrelated male donor matched at HLA-A, -B, and -DR loci were infused on day 0. Beginning on day +5, filgrastim ($300 \text{ }\mu\text{g}/\text{day}$) was administered until the WBC count exceeded $5 \times 10^9/\text{L}$. On day +14, the WBC count exceeded $1.0 \times 10^9/\text{L}$. Full chimerism was confirmed by a 100% donor-derived male karyotype in a bone marrow aspirate obtained on day +36. Final transfusions of platelets and red blood cells were given on day +36 and day +39, respectively. Neurologically, the patient began to recover from dysarthria and right hemiparesis about 2 weeks after transplantation. CT (on day +15) disclosed spontaneous resolution of the hematoma (Fig. 1).

The post-transplant course was complicated by *Staphylococcus epidermidis* bacteremia on day +3; this was managed successfully with teicoplanin and meropenem. On day +13, the patient developed respiratory distress. Chest radiography and CT disclosed pulmonary edema, considered a component of the “engraftment syndrome,” which responded to administration of high-dose methylprednisolone. On day +25, she presented stage 1 skin

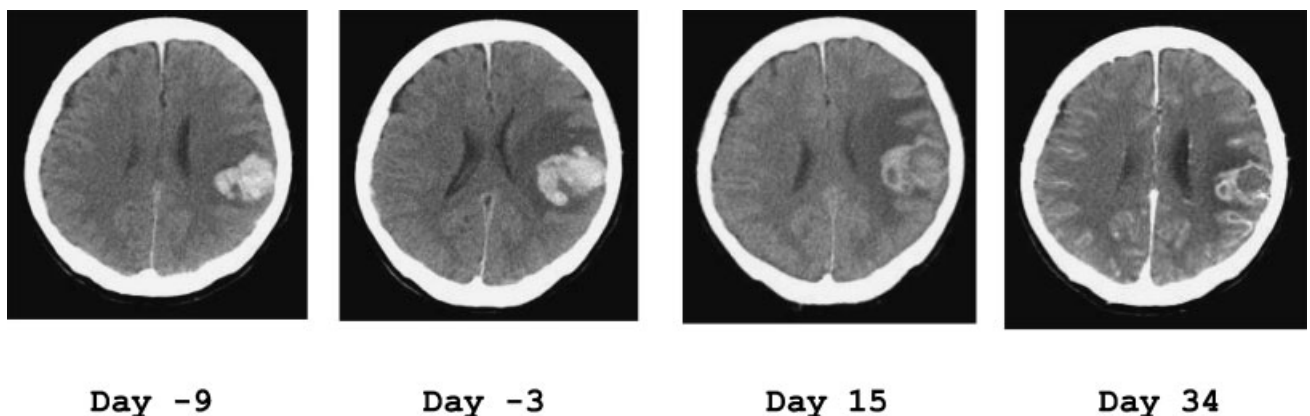


Fig. 1. Serial cranial computed tomography.

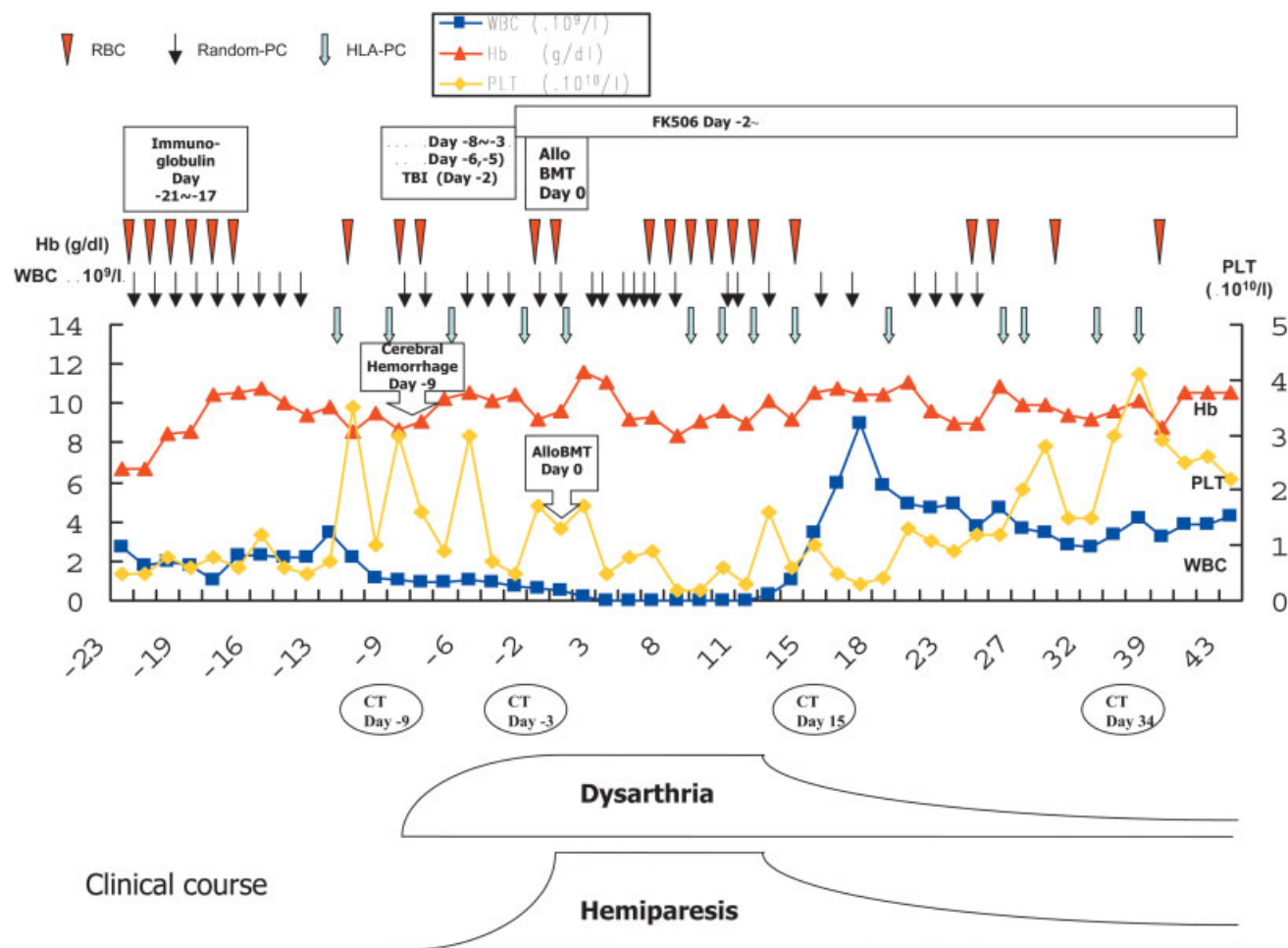


Fig. 2. Time line of the patient's clinical course. Abbreviations: RBC, red blood cells; Random-PC, platelet concentrate from random donors; HLA-PC, platelet concentrate from HLA-matched donors; Flu, fludarabine; BU, busulfan; TBI, total body irradiation; FK506, tacrolimus; CT, computed tomography. [Color figure can be viewed in the online issue, which is available at www.interscience.wiley.com.]

rashes on the upper limbs and anterior chest wall, representing acute GVHD. These resolved with a slight dose escalation of FK506. On day +47, the patient was discharged from the hospital in a wheelchair (Fig. 2).

DISCUSSION

A variety of neurologic complications have been reported after allogeneic BMT. While subdural hematoma has been reported to have a relatively benign outcome [3], ICH has ominous prognostic implications [4].

Reported occurrence rates of ICH in patients with leukemia and neurologic complications following BMT have varied widely. Graus et al. noted ICH in 11% of 425 patients [5], while Antonini et al. encountered only one case among 115 [6]. In a large series of 1,402 BMT patients at the Johns Hopkins Hospital [7], 2% of patients developed ICH within 100 days following BMT. Several factors have been reported to be associated

with ICH, including a low platelet count or refractoriness to platelet transfusion [5,6,8–11], underlying disease [5,6,9,12], veno-occlusive disease [13], coagulopathies [3,14,15], infections [10,11,14,16,17], and irradiation [9]. Although thrombocytopenia is considered the most important among risk factors for ICH, considerable disagreement exists. Morhmann et al. [8] and Pomeranz et al. [4] have mentioned that thrombocytopenia and/or coagulopathies alone often are insufficient to produce cerebral hemorrhage. In transplant recipients, most bleeding has been associated with additional complications including fever and veno-occlusive disease [13]. Since nonmyeloablative conditioning causes less RRT than myeloablative conditioning, NST should cause less bleeding tendency than conventional HSCT. Clinical indications for HSCT have been expanding with respect to both disease categories and patient eligibilities [18]. With introduction of NST, the strict exclusion criteria for allogeneic HSCT have been questioned [2].

Our patient was refractory to platelet transfusion and had a history of central nervous system hemorrhage, including spontaneous parietal, subtentorial, and lumbosacral subdural hematomas. At the time of admission to our hospital, she had no documented infections and no history of lumbar puncture. We decided to perform unrelated donor BMT because her prognosis with conservative management was compromised by transfusion-related iron overload and by persistent refractoriness to platelet transfusions. One day before planned initiation of pre-transplant conditioning, she developed ICH. Most transplant centers maintain that allogeneic HSCT is not indicated during the acute phase of cerebrovascular events. However, the scheduled unrelated donor BMT would have been prohibitively difficult to postpone. After extensive discussion with the patient's family, we decided to perform unrelated donor BMT with nonmyeloablative pre-transplant conditioning. Our patient clearly was at high risk for enlargement or additional occurrence of ICH, even though her thrombocytopenia was treated maximally by transfusion. Despite persistent thrombocytopenia throughout much of the clinical course (Fig. 2), she did not develop further ICH.

In the post-transplant course, neurologic recovery paralleled hematologic recovery. About 2 weeks after transplantation, the patient started to recover from dysarthria and right hemiparesis; almost simultaneously, hematologic engraftment was confirmed. Several possible factors could have contributed to her neurologic functional improvement. FK506 and G-CSF are potent neuroprotectants in experimental models of stroke [19–21]. However, prompt administration is necessary to observe the neuroprotective effect. In our patient, FK506 and G-CSF were administered more than 1 week after the onset of her ICH. Although the time profile did not seem suitable, it remains possible that FK506 or G-CSF contributed to her neurologic recovery.

Recent evidence suggests that neural stem cells, fetal transplants, immortalized cell lines, and bone marrow stromal cells may be beneficial in experimental models of neurologic disease including stroke [22–24].

Our patient was infused with bone marrow cells from an HLA-matched unrelated donor 9 days after the onset of her stroke. In animal brain injury models, bone marrow cells usually are infused immediately after the insult [25]. In an experimental model of ICH, transplanted human neural stem cells were reported to enter the rat brain, survive, migrate, and promote functional recovery after 2 weeks. Despite difficulty of objective evaluation, neurologic recovery in our patient was more rapid than one ordinarily might expect, and the infused bone marrow cells

might have played some role in improving neurologic recovery, although it is highly speculative.

In conclusion, we report a patient with MDS who developed ICH but who was treated successfully by unrelated nonmyeloablative BMT during the acute phase of the stroke. This case suggests that the acute phase of ICH may not be an absolute contraindication for allogeneic BMT, if other clinical considerations require transplantation without delay.

REFERENCES

1. Coplin WM, Cochran MS, Levine SR, Crawford SW. Stroke after bone marrow transplantation: frequency, aetiology and outcome. *Brain* 2001;124(Pt 5):1043–1051.
2. Storb RF, Champlin R, Riddell SR, Murata M, Bryant S, Warren EH. Non-myeloablative transplants for malignant disease. *Hematology (Am Soc Hematol Educ Program)* 2001:375–391.
3. Colosimo M, McCarthy N, Jayasinghe R, Morton J, Taylor K, Durrant S. Diagnosis and management of subdural hematoma complicating bone marrow transplantation. *Bone Marrow Transplant* 2000;25(5):549–552.
4. Pomeranz S, Naparstek E, Ashkenazi E, et al. Intracranial haematomas following bone marrow transplantation. *J Neurol* 1994; 241(4):252–256.
5. Graus F, Saiz A, Sierra J, et al. Neurologic complications of autologous and allogeneic bone marrow transplantation in patients with leukemia: a comparative study. *Neurology* 1996;46(4): 1004–1009.
6. Antonini G, Ceschin V, Morino S, et al. Early neurologic complications following allogeneic bone marrow transplant for leukemia: a prospective study. *Neurology* 1998;50(5):1441–1445.
7. Nevo S, Swan V, Enger C, et al. Acute bleeding after bone marrow transplantation (BMT)- incidence and effect on survival. A quantitative analysis in 1,402 patients. *Blood* 1998;91(4):1469–1477.
8. Mohrmann RL, Mah V, Vinters HV. Neuropathologic findings after bone marrow transplantation: an autopsy study. *Hum Pathol* 1990; 21(6):630–639.
9. Patchell RA, White CL 3rd, Clark AW, Beschoner WE, Santos GW. Neurologic complications of bone marrow transplantation. *Neurology* 1985;35(3):300–306.
10. Mehta J, Powles R, Singhal S, et al. Early identification of patients at risk of death due to infections, hemorrhage, or graft failure after allogeneic bone marrow transplantation on the basis of the leukocyte counts. *Bone Marrow Transplant* 1997;19(4):349–355.
11. Oppenheim-Eden A, Glantz L, Eidelman LA, Sprung CL. Spontaneous intracerebral hemorrhage in critically ill patients: incidence over six years and associated factors. *Intensive Care Med* 1999; 25(1):63–67.
12. Tornebohm E, Lockner D, Paul C. A retrospective analysis of bleeding complications in 438 patients with acute leukaemia during the years 1972–1991. *Eur J Haematol* 1993;50(3):160–167.
13. Gil-Fernandez JJ, Alegre A, Fernandez-Villalta MJ, et al. Clinical results of a stringent policy on prophylactic platelet transfusion: non-randomized comparative analysis in 190 bone marrow transplant patients from a single institution. *Bone Marrow Transplant* 1996; 18(5):931–935.
14. Bleggi-Torres LF, de Medeiros BC, Werner B, et al. Neuropathological findings after bone marrow transplantation: an autopsy study of 180 cases. *Bone Marrow Transplantation* 2000;25(3): 301–307.
15. Bleggi-Torres LF, de Medeiros BC, Ogasawara VS, et al. Iatrogenic Wernicke's encephalopathy in allogeneic bone marrow trans-

- plantation: a study of eight cases. *Bone Marrow Transplant* 1997; 20(5):391–395.
16. de Medeiros BC, de Medeiros CR, Werner B, et al. Central nervous system infections following bone marrow transplantation: an autopsy report of 27 cases. *J Hematother Stem Cell Res* 2000; 9(4):535–540.
17. Bleggi-Torres LF, de Medeiros BC, Werner B, Pasquini R, de Medeiros CR. Unusual presentation of cerebral toxoplasmosis after BMT. *Bone Marrow Transplant* 1999;23(8):855–856.
18. Bolwell BJ. Are predictive factors clinically useful in bone marrow transplantation? *Bone Marrow Transplant* 2003;32(9):853–861.
19. Arai T, Kamiya T, Arai K, et al. Neuroprotective effect of immunosuppressant FK506 in transient focal ischemia in rat: therapeutic time window for FK506 in transient focal ischemia. *Neurol Res* 2001; 23(7):755–760.
20. Kelly JS, Sharkey J. Immunosuppressants-ligands as neuroprotectants. *Transplant Proc* 2001;33(3):2217–2219.
21. Schabitz WR, Kollmar R, Schwanninger M, et al. Neuroprotective effect of granulocyte colony-stimulating factor after focal cerebral ischemia. *Stroke* 2003;34(3):745–751.
22. Wechsler LR, Kondziolka D. Cell therapy: replacement. *Stroke* 2003; 34(8):2081–2082.
23. Howells D. Stem cells: do they replace or stimulate? *Stroke* 2003; 34(8):2082–2083.
24. Fisher M. Stem cell transplantation for stroke: does it work, and if so, how? *Stroke* 2003;34(8):2083.
25. Jeong SW, Chu K, Jung KH, Kim SU, Kim M, Roh JK. Human neural stem cell transplantation promotes functional recovery in rats with experimental intracerebral hemorrhage. *Stroke* 2003;34(9): 2258–2263.