

CASE REPORT

Hemianopic visual field loss as the first clinical evidence of occipital arteriovenous malformation

Clin Exp Optom 2004; 87: 6: 394–399

Ian F Gutteridge* MScOptom LOSc
FVCO FAAO

Robert A McDonald† MBBS FRANZCO
FRACS

* Department of Optometry and Vision
Sciences, The University of Melbourne,
Australia

† Department of Ophthalmology,
Monash Medical Centre, Australia

Submitted: 21 April 2004

Revised: 2 July 2004

Accepted for publication: 9 August 2004

A 43-year-old patient presenting with a highly congruous homonymous hemianopia was shown by neuro-imaging to have a very large arteriovenous malformation of the brain. The significance of finding this visual field defect, its unusual cause and the absence of symptoms other than longstanding migraine with aura are discussed.

Key words: arteriovenous malformation of the brain, homonymous hemianopia

Arteriovenous malformations (AVM) of the brain are important cranial vascular lesions capable of causing significant morbidity. Clinicians probably place AVMs very low in a list of differential diagnoses of neurological disorders, such as hemianopia, in part due to a relatively low prevalence. They are more likely to expect mass lesions, such as tumours, or cerebrovascular events, such as intracranial haemorrhage or infarction of major cerebral arteries. In younger patients, there may be consideration of multiple sclerosis¹ or migrainous infarction.^{2,3}

AVMs are believed to arise from congenital maldevelopment of intracranial vessels.⁴ Embryological shunts persist after the failure of capillaries to develop between

arteries and veins. These shunts invaginate into brain tissue by following vessels into fissures. AVMs are composed of vessels of varying calibre, thickness and structure, which may undergo thrombosis, haemorrhage, hyaline degeneration and calcification.² They are found throughout the central nervous system and depending on their location, may cause sensory visual symptoms and more rarely, ocular motor symptoms.

This report discusses the presentation of a patient with symptomatic loss of peripheral vision. Subsequent imaging studies identified a very large AVM. Difficult management decisions ensued for the neurologists, neurosurgeons and the patient following this discovery.

CASE REPORT

A 43-year-old female presented to one of the authors (IFG) after becoming increasingly aware of decreased peripheral vision, especially on her left side, over approximately 12 months. She reported bumping into objects on the left side and used the term 'tunnel vision' to describe her visual difficulties. Three weeks previously, she had presented with similar symptoms to another optometrist, who prescribed new spectacles for low myopia. She did not recall any visual field testing being carried out or recommended. She remained concerned and sought a second opinion.

She had a long history of migraine with right-sided headache and left-sided

positive visual phenomena, suffered from about 13 years of age, although these migraines had become less frequent of late. Recently, she had also experienced regular headaches of the right occipital/upper cervical region. Her medical history was significant as she had undergone surgery for hysterectomy with general anaesthesia one month before ocular examination. Several years earlier, she had had bilateral lower lid blepharoplasty.

Visual acuities were R 6/6- (-0.50/-0.25 x 90) and L 6/6- (-0.75 D). There were no anterior segment abnormalities. Cover test, pupil reactions and eye movements were normal. In the posterior segment, both discs had cup/disc ratio of 0.7 with some pallor of the inferior neuro-retinal rim in the right eye. There was no optic disc oedema. Venous pulsation was visible on both optic discs. Intraocular pressures were 15 mmHg. There were no peripheral retinal pigmentary changes suggestive of diseases such as retinitis pigmentosa.

Dense left homonymous hemianopic defects were evident on confrontation. They affected predominantly the inferior quadrants but the lower parts of the superior quadrant were also involved. Automated perimetry (Medmont M600 full screening) confirmed a highly congruous maximum luminance defect in both left hemifields (Figure 1).

The patient was informed that these visual field defects were highly significant, with a causative lesion likely to be in the right occipital region, and imaging techniques would be necessary for differentiation. She was referred for ophthalmological opinion and examined by one of the authors (RAM) the next day. The hemianopic defects were confirmed, as were the other features of the initial examination.

Computerised tomography (CT) was carried out the same day and showed the presence of a large arteriovenous malformation (AVM) involving the parieto-occipital region of the right cerebral hemisphere. Following intravenous injection of contrast, multiple serpiginous vessels were evident in the posterior portion of the right cerebral hemisphere. There was no evidence of recent haemorrhage (Figure 2).

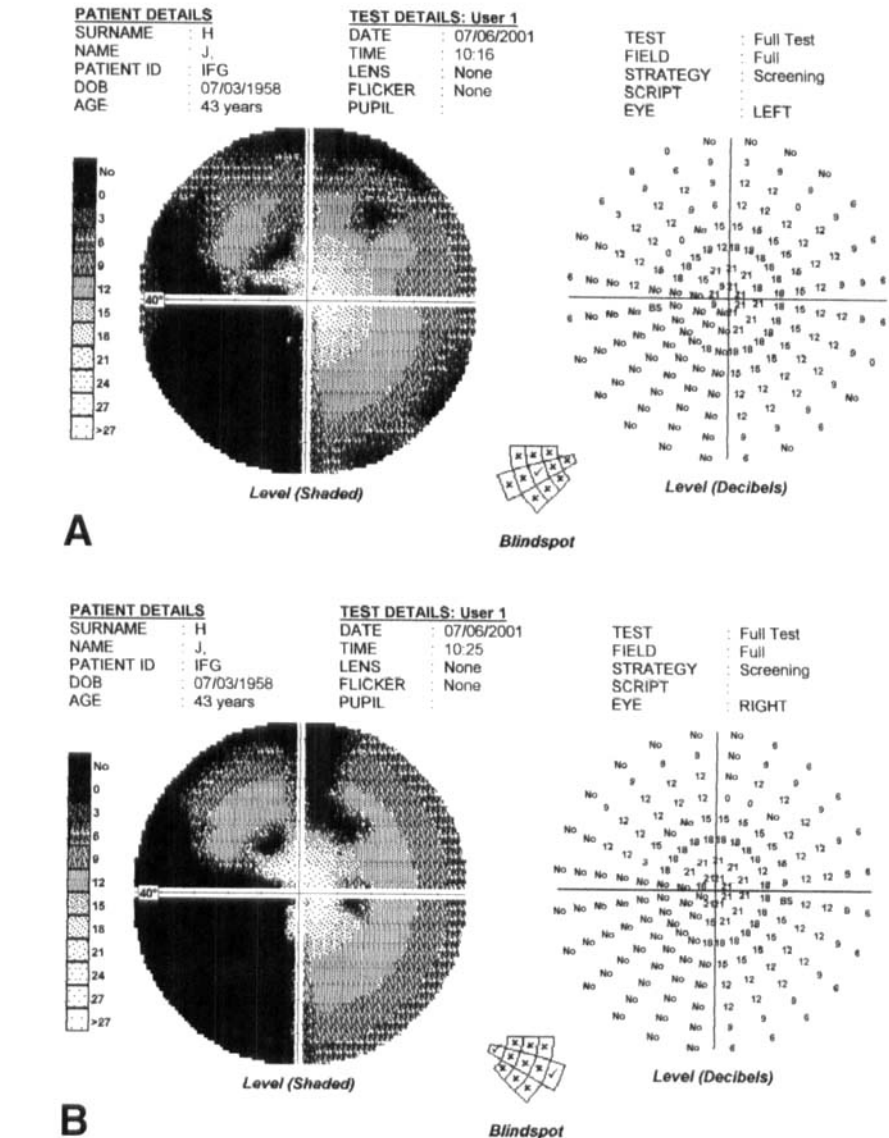


Figure 1. Automated perimetry (Medmont M600 full screening) at initial presentation showing a highly congruous maximum luminance left homonymous hemianopia affecting inferior and superior quadrants

A neurological opinion was obtained. No further symptoms of relevance were elicited. Apart from the field defects and the presence of a bruit over the right occiput and neck, the neurological examination was normal. Magnetic resonance imaging (MRI) and cerebral angiography were undertaken (Figures 3a, 3b and 4).

MRI showed a large vascular malformation in the right occipital lobe extending

into the inferior and medial cortex, the nidus measuring 4 x 3 x 3.5 cm. There was no evidence of ischaemia or recent haemorrhage. The AVM had multiple supplying arteries, including:

1. right middle cerebral artery
2. right posterior cerebral artery
3. left posterior cerebral artery
4. branches of both the middle meningeal arteries

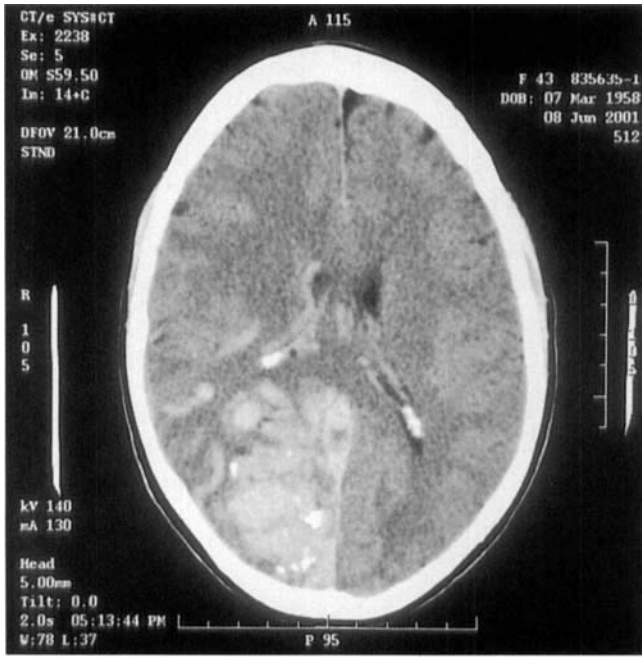


Figure 2. CT scan showing contrast material occupying most of the parieto-occipital region. Vermiform drainage veins are prominent. High signal areas (calcium) probably indicate areas of previous haemorrhage

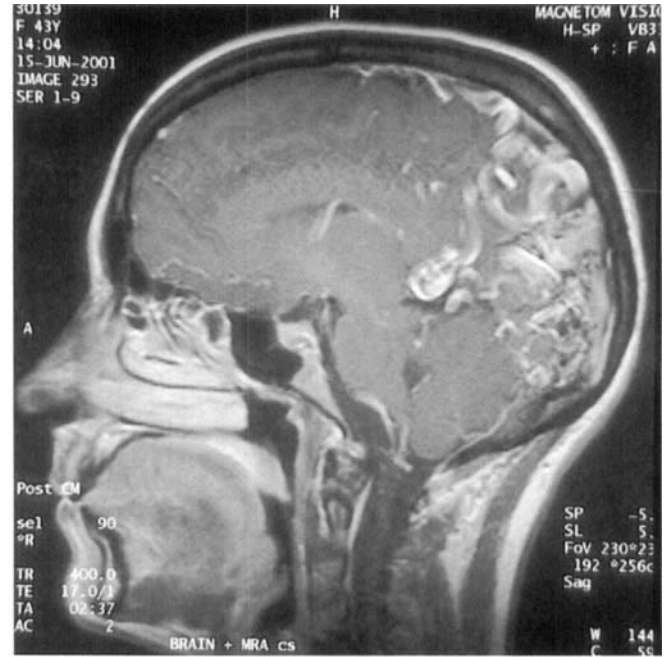


Figure 3a. Parasagittal MR section showing extensive dilated vessels over the surface of the cerebral hemisphere and occipital lobe

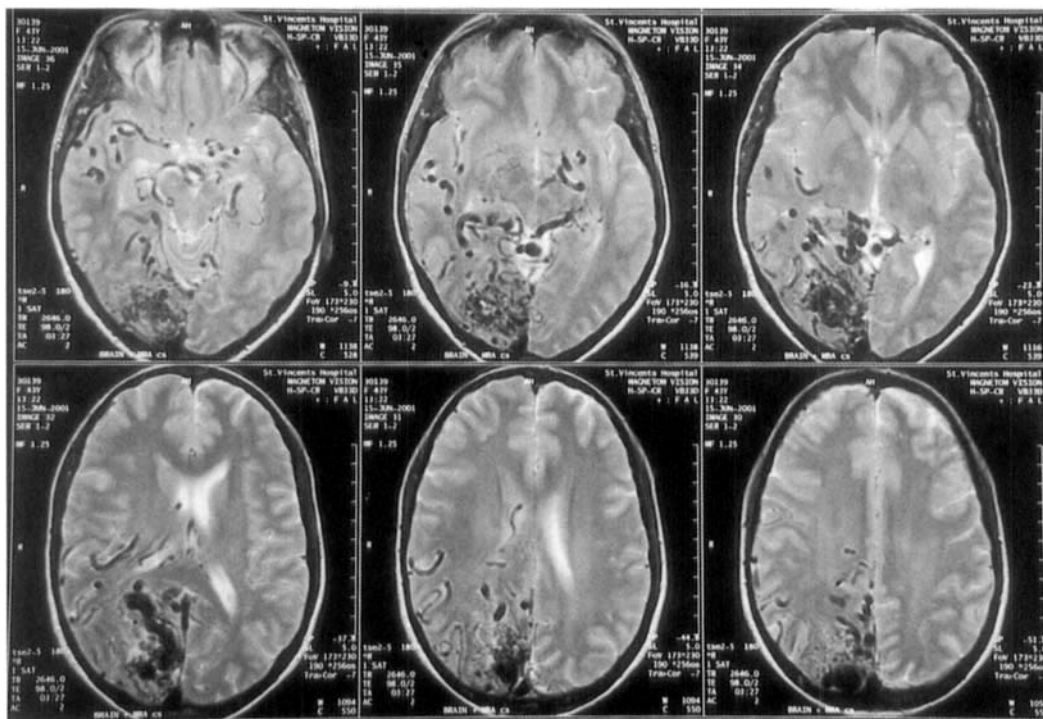


Figure 3b. Multiple axial T1 MR scans showing the extent of the lesion and bilateral damage

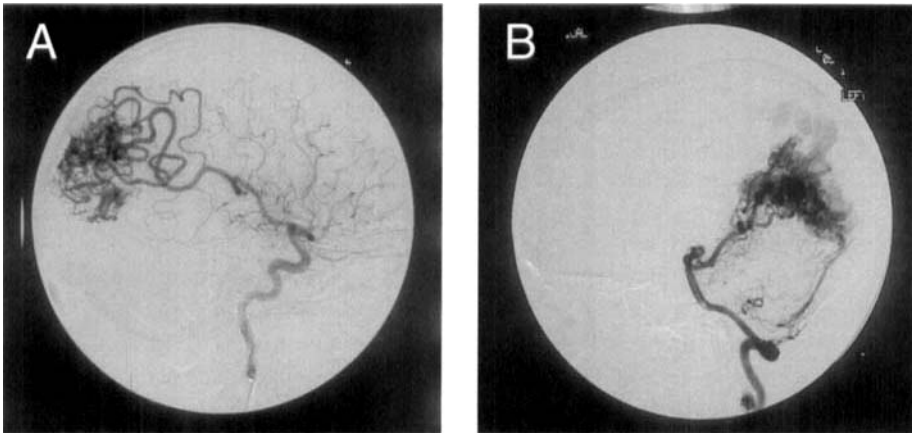


Figure 4. Cerebral angiography with selective injection of the middle cerebral (a) and vertebral (b) arteries showing dual supply of the AVM

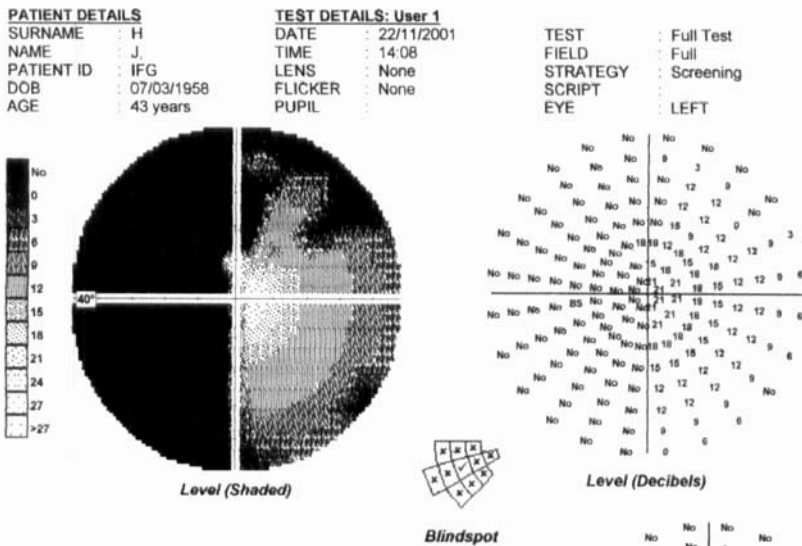


Figure 5. Post-operative visual field (left eye only) showing a complete and absolute left hemianopia with some involvement of the right superior hemi-field. A similar (homonymous) hemianopia was found in the right eye.

5. branches of both the right and left occipital arteries.

There were also multiple veins, draining mainly into the superior sagittal sinus but others indirectly draining into basal veins and eventually to the extracranial infra-temporal fossa.

The patient obtained several neuro-surgical opinions on the possible management of this lesion. Alternatives included

conventional or stereo-tactic radiotherapy, vessel embolisation, surgical removal following vessel embolisation and no intervention. Conservative management was associated with considerable risk. The risk of intracranial haemorrhage was estimated at three to four per cent per year by two neurosurgeons in letters and reports to the patient's various practitioners. This was expressed as 40 per cent over a 20 year

period by another, with no measure of how severe such a haemorrhage might be or when it might occur. There was also the risk of seizures developing, although the patient had not experienced any.

Embolisation alone was not considered likely to eliminate risk from the lesion, however, surgical excision of the lesion, preceded by embolisation, was considered the most promising form of intervention by reducing the number of blood vessels. A number of serious possible risks had to be assessed. Apart from cardio-pulmonary, thrombo-embolic and infective complications, there were significant neurological risks of death (estimated at three to five per cent), stroke (estimated at 15 per cent), paralysis and seizures. There was an almost certain risk of complete homonymous hemianopia following surgery due to the difficulty of delivering the embolic material to the feeding vessels of the AVM, without also occluding some cortical branches.

The patient opted for presurgical embolisation followed by excision. This was successfully completed without complication. Postoperative angiography showed complete removal of the AVM. A complete left homonymous hemianopia with macular splitting was now evident (Figure 5). There was some involvement of the right hemifield, suggesting that there may have been some haemodynamic effect of the lesion on the left occipital cortex. The patient's visual acuities were R 6/7.5 and L 6/7.5 but macular splitting caused slow reading of individual letters. Also, formed visual hallucinations in the blind hemifield were troublesome. These were considered to be epileptiform in nature and were treated with dilantin. The patient has since received mobility training but is now unable to drive and had considerable difficulties adapting to complete hemianopia after surgery.

DISCUSSION

Discovering a hemianopia in a relatively young patient is alarming. It raises the prospect of sinister causes, especially tumours or rarely demyelination.^{1,5} Unilateral occipital lesions in the older

patient are most commonly due to stroke.² Tumours in the occipital region include meningiomas, gliomas and metastatic lesions. Trauma or recent manipulation can be relevant. Complicated migraine can cause a permanent hemianopia.^{3,6} AVMs are relatively rare lesions and consequently, would not be readily considered in the differential diagnosis. One prevalence estimate is 0.01 to 0.50 per cent of the general population, generally presenting in patients aged 20 to 40 years.⁷ A non-selected, consecutive series of patients representing every diagnosed case of cerebral AVM in a population of one million over one decade found 12.4 *de novo* diagnosed AVMs per one million population per year.⁸ They occur significantly less frequently than intracranial aneurysms. One estimate of the ratio of AVM to aneurysm was 1:6.5.⁹

The usual clinical presentations in AVMs are haemorrhage, seizures, progressive neurological deficit or headache.⁷ This patient's hemianopic field defects could be described as a progressive neurological deficit. Haemorrhage is the initial manifestation of AVM in 69 per cent of cases.⁸ It is fortunate that this patient had not developed a major haemorrhage before the AVM was detected, as 10 per cent of haemorrhages have a fatal outcome⁴ and some survivors have a significant neurological deficit.⁴ Some minor haemorrhages may have occurred previously as evidenced by calcium seen in CT scan images.

This case is noteworthy for several reasons:

1. The patient's hemianopias were likely to have been developing for a considerable time as the AVM was congenital. Presumably, it developed very slowly with the patient adapting to its presence. It is well known that, more often than not, patients with acquired scotomata and hemianopias are unaware of their field loss.¹⁰ AVMs, like other slowly developing lesions, may be discovered only when symptoms are sufficiently obvious, an acute event is superimposed or perhaps when neuro-imaging has been carried out for another reason. The patient was also slightly older than expected at first diagnosis. More than 70

per cent of AVM cases are evident before 40 years of age.^{4,7}

2. This patient volunteered the comment of 'bumping into objects'. This is a classical symptom for clinicians to seek but is rarely actually expressed by patients. It was overlooked or inadequately investigated by another optometrist. Confrontation testing immediately confirmed her symptom.

3. The underlying cause of the field loss is interesting to consider. Compression or infarction of the visual pathway is the usual cause of field loss in AVMs, although haemorrhage from an AVM can also cause hemianopic field loss.⁴ There was no evidence of recent haemorrhage or infarction detected with neuro-imaging in this patient. The opinion of one neurosurgeon was that the field loss was due to a 'steal' phenomenon. There may be significant circulatory disturbances in neighbouring brain areas and the malformation can tend to steal blood from normal vascular channels, leading to hypoperfusion and related functional defects.^{2,4}

4. The right optic disc appearance of cupping and inferotemporal pallor is not easily explained by occipital pathology. As the AVM is congenital, some trans-synaptic degeneration across the lateral geniculate nucleus may have occurred, causing loss of axons in the ipsilateral optic tract. On occasions, AVMs have been associated with distant optic nerve changes.⁴ Against this is the lack of a relative afferent pupillary defect, the more inferior pallor and the lack of bow tie atrophy of the left disc. Also, it is theoretically possible that the process could be responsible for damage to more than one area of the visual pathway although there is no evidence of this in our case.² There is a family history of glaucoma and the right disc may exhibit early glaucomatous optic neuropathy (normal tension type).

5. It is remarkable that such a large lesion caused so few neurological symptoms. The patient had experienced a new form of headache (differing from previously experienced migraine), which may have been the result of the AVM. The change in headache quality in our patient may represent a change in the haemodynamic state of the

AVM. The clinical value of confrontation and visual field testing in unexplained headache is clearly reinforced by this case. Episodic headache is a common presenting symptom in AVM and is often migrainous in nature. The incidence of headache as the presenting symptom in AVM cases is the same as that of migraine in the general population.⁴ Headache is part of the clinical picture in over half of AVM cases, especially occipital AVMs. It is nearly always on the side of the lesion⁴ and migraine-like positive visual phenomena are generally seen in the opposite hemifield. However, the photopsiae may follow the headache rather than precede it, as in migraine. These phenomena may represent a vasomotor occurrence or a localised seizure. In some cases, headache is associated with minor cerebral haemorrhage from the AVM. Perhaps this patient's migraine with aura was secondary to the AVM and mistaken as typical/normal migraine.^{4,11}

The very low prevalence of AVMs in the general population suggests a complaint of headache is unlikely to be caused by an AVM. Routine neuro-imaging for AVMs in unexplained headache is therefore inappropriate. Small lesions that are asymptomatic and detected fortuitously (the so-called silent AVM) seem unlikely to cause significant neurological events.² A visual field examination, at least by confrontation, should be undertaken as part of the examination of a patient with a new or altered symptom of headache. Abnormal perimetry results may direct the subsequent investigation, as occurred in this patient.

SUMMARY

This case demonstrates hemianopic visual field losses related to arteriovenous malformation in the occipital region of the brain, which was an unusual and unexpected cause. It highlights that relatively young patients can present with highly significant conditions and minimal symptoms. Primary care practitioners must be prepared to conduct visual field testing, at least by confrontation, on subtle indications.

ACKNOWLEDGEMENT

We are very grateful to Dr Owen White, Melbourne, for his assistance in the interpretation of the neuro-imaging in this case.

REFERENCES

1. Harrington DO. The Visual Fields. A Textbook and Atlas of Clinical Perimetry, 5th Ed. St Louis: CS Mosby; 1981.
2. Miller NR. Walsh and Hoyt's Clinical Neuro-Ophthalmology, 4th ed. Baltimore: Williams & Wilkins; 1988.
3. Lewis RA, Vijayan N, Watson C, Keltner J, Johnson CA. Visual field loss in migraine. *Ophthalmology* 1989; 96 : 321-326.
4. Kupersmith MJ. Neuro-vascular Neuro-ophthalmology. New York: Springer-Verlag; 1993.
5. Gutteridge IF. An unusual ocular presentation of multiple sclerosis. *Am J Optom Phys Optics* 1985; 62: 69-71.
6. Wakakura M, Ichibe Y. Permanent homonymous hemianopias following migraine. *J Clin Neuro-ophthalmol* 1992; 12: 198-202.
7. Fleetwood IG, Steinberg GK. Arteriovenous malformations. *Lancet* 2002; 359: 863-873.
8. Hillman J. Population-based analysis of arteriovenous malformation treatment. *J Neuro-surg* 2001; 95: 633-637.
9. Mohr JP, Caplan LR, Melski JW, Goldstein RJ, Duncan GW, Kistler JP, Pessin MS, Bleich HL. The Harvard co-operative stroke registry: a prospective registry. *Neurology* 1978; 28: 754-762.
10. Feinberg TE, Roane DM. Visual aspects of anosognosia, confabulation and misidentification. In: Behrmann M, ed. Handbook of Neuro-psychology, 2nd ed. Vol. 4. Amsterdam: Elsevier; 2001: p 144.
11. Troost BT, Newton TH. Occipital lobe arteriovenous malformations. *Arch Ophthalmol* 1975; 93: 250-256.

Author's address:

Ian F Gutteridge
Department of Optometry and Vision
Sciences
The University of Melbourne
374 Cardigan Street
Carlton VIC 3053
AUSTRALIA

ERRATUM

Correction to: Joel Pokorny. The evolution of knowledge: trichromasy as theory and in nature. *Clin Exp Optom* 2004; 87: 4-5: 203-205.

The caption to Figure 1 in the editorial by Dr Pokorny incorrectly stated that Arthur König was the first to propose that dichromasy is the result of an absence of one of the cone pigments and was the first to derive the three cone fundamentals by transforming colour mixture data. Dr Pokorny advises that 'the idea that dichromasy was the result of an absence of one of the cone photopigments was alluded to by Seebeck (Über den bei manchen Personen vorkommenden Mangel an Farbesinn. *Pogg Ann Phys Chem* 1837; 42: 177-233) and made explicit by Maxwell (Experiments on colour, as perceived by the eye, with remarks on colour-blindness. Transactions of the Royal Society, Edinburgh 1855; 21: 275-298)'.

He further advises that 'Maxwell (On the theory of compound colors and relations of the colors of the spectrum. *Philosophical Transactions* 1860; 150: 57-84) and Donders (New researches on the systems of colour-sense. *Onderzoekingen gedaan in het Physiologisch Laboratorium der Utrechtsche Hoogeschool, Derde Reeks* 1882; 7: 95-109) preceded König in deriving the three cone fundamentals of human colour vision from a transformation of colour mixture data. König is acknowledged to be the first to get things correct quantitatively'.

A topic editor, not Dr Pokorny, wrote the caption.