

Spontaneous Intracerebral Hemorrhage Related to Methamphetamine Abuse

Autopsy Findings and Clinical Correlation

Shawn M. McGee, MD,* Deanna N. McGee, PharmD, BCPS,† and Michael B. McGee, MD‡

Abstract: A healthy 31-year-old male abstinent from drug abuse during his recent incarceration developed slurred speech, a severe headache, and left-sided hemiparesis prior to his eventual death 9.5 hours after inhalation of methamphetamine. On postmortem examination, inspection of the brain revealed bilateral subarachnoid hemorrhage, with a prominent intralobar hemorrhage centered within the right frontal cerebral hemisphere. No evidence of vasculitis, infarction, intraventricular hemorrhage, or ruptured aneurysm could be observed. While this is not the first report of a methamphetamine-related stroke, this report describes the autopsy findings of an intracerebral hemorrhage secondary to methamphetamine abuse on autopsy and compares the findings and antemortem history to previously reported methamphetamine cerebral vascular deaths.

Key Words: methamphetamine, autopsy, cerebral vascular accident, hemorrhagic stroke, ischemic stroke

(*Am J Forensic Med Pathol* 2004;25: 334–337)

Methamphetamine (MA) is the most commonly abused drug of patients presenting to emergency departments in the western United States,¹ with MA-related deaths having a greater than 2-fold increase in several US cities since the early 1990s.² Consequently, the results of MA abuse have become important entities to understand clinically and pathologically. A problem seen with the abuse of MA is spontaneous cerebral vascular accidents (CVAs), illustrated by an increasing amount of case reports and case series described in the last decade. Overall, CVAs make up a smaller percentage of MA-

related deaths as compared with homicides, poisonings, and accidents due to the drug.^{3,4} Nonetheless, the incidence of MA abuse is growing, especially in younger age groups, and identification of CVAs secondary to MA in emergency departments and at autopsy has an increasing significance.

The majority of previous reports discussing MA-related CVAs have emphasized and studied the clinical and/or the radiographic findings, with less attention paid to pathologic findings on autopsy. This report follows the progression of a cerebral hemorrhage in a distinct timeframe within an otherwise healthy male with an unremarkable history of abusing MA.

CASE REPORT

A 31-year-old male smoked and then snorted MA (“crank”) with 2 of his male acquaintances at approximately 5:00 PM. Statements later provided to the police estimated the amount of drug ingested to be between 0.25 and 0.50 g. Ten to fifteen minutes after ingesting the drug, the subject began to complain of a “mean headache,” followed by nausea and vomiting. Upon arrival at a second residence, the subject elected to “sleep off” the effects of the drug in the back of an automobile. An acquaintance monitored his welfare throughout the evening hours. During these visits, the subject complained that the left side of his body felt numb, his speech was noted to be slurred, and he repeatedly fell from the seat upon which he was lying onto the floor. When an offer was made to take him to a nearby medical facility, the subject declined, stating that he had been released from a correctional facility earlier that week and a condition of his parole was to abstain from using controlled substances. He was subsequently discovered dead within the automobile at 2:30 AM the following morning, approximately 9.5 hours after ingestion of MA. Police and paramedics were summoned to the scene of death.

Scene investigation revealed the subject lying supine in a parked automobile, with only the left side of the body clothed. The subject’s right arm and right leg had been pulled out of his shirt and pants, respectively. Examination of the body at the scene revealed no evidence of trauma. The body was cool to the touch, with rigor present and fixed. Livor was appropriate in its distribution.

Manuscript received November 15, 2003; accepted February 4, 2004.

From the *University of Minnesota School of Medicine, Minneapolis, Minnesota; the †Department of Pharmacy, Hennepin County Medical Center, Minneapolis, Minnesota; and the ‡Ramsey County Medical Examiner’s Office, St. Paul, Minnesota.

Reprints: Michael B. McGee, MD, Ramsey County Medical Examiner’s Office, 300 E. University Ave., St. Paul, MN 55101. E-mail: mmcgeel@mn.rr.com.

Copyright © 2004 by Lippincott Williams & Wilkins

ISSN: 0195-7910/04/2504-0334

DOI: 10.1097/01.paf.0000137206.16785.2f

At postmortem examination, the body of a 31-year-old male was observed. No evidence of acute traumatic injuries was noted at the time of the external or internal examination. Inspection of the heart revealed a normal coronary vasculature system with no evidence of coronary vessel disease. On examination of the brain, cerebral edema was observed, with a weight of 1480 g. The cerebral hemispheres appeared asymmetric with a right to left midline shift. Subarachnoid hemorrhage (SAH) was present over the cerebral convexities bilaterally. On sectioning of the cerebral hemispheres, an intracerebral hemorrhage (ICH) was noted lateral to the basal ganglia and extending to involve the lateral aspect of the putamen, as well as the claustrum, external capsule, insula, and into the superior longitudinal fasciculus of the right cerebral hemisphere, covering an area that measures 3.5 cm by 4.5 cm (Fig. 1). No evidence of intraventricular hemorrhage, infarction, aneurismal rupture, or arterial venous malformation could be appreciated. Microscopic sections revealed fresh appearing hemorrhage, with no evidence of inflammation or vasculitis noted.

Toxicology analysis performed on specimens collected at the time of the postmortem examination revealed a negative blood ethanol and serum screen. A urine screen was positive for MA, amphetamine, and THC. Confirmatory testing revealed a blood MA level of 300 ng/mL, with a blood amphetamine level of 30 ng/mL.

DISCUSSION

There are limited reports of autopsy findings in patients with CVAs secondary to MA abuse.^{5,6} Postmortem examination in these reports describes either an ICH or cerebral infarction (Table 1). In the literature, amphetamine and MA-related CVAs are predominantly hemorrhagic strokes.^{5,7-12} Paradoxically, hemorrhagic strokes account for less than one

fourth of CVAs in the general population.¹³ MA-related ICHs have been reported in all cerebral lobes, with the majority involving the frontal lobe, as seen in our case. Grossly, these ICHs are indistinguishable from those caused by other amphetamines and cocaine.¹⁴⁻¹⁶ As in our case, a proportion of amphetamine- and MA-related ICHs have also been found to have a SAH.^{5,8,17} In some cases, MA-related ICHs have been attributed to the disturbance of arterial venous malformations¹⁸ or ruptured cerebral aneurysms,¹⁹ resulting in an ICH seen in the distribution of the affected cerebral artery.

Ischemic strokes attributed to MA abuse are described in the literature as having infarctions involving the cerebral hemispheres, the brainstem, or both.^{6,20,21} The majority of infarctions are described as secondary to acutely organized thrombus in cerebral vessels affected by necrosis associated with vasculitis. Cerebral vasculitis is the most commonly described histologic and radiologic finding in abusers of MA with either hemorrhagic or ischemic strokes.^{5,6,10,11,17,22} Histologic analysis of persons suffering from CVAs associated with MA-related cerebral vasculitis shows necrotic lesions seen in small and large cerebral arteries, with moderate to extensive medial necrosis with the presence of minimal inflammatory cells.^{5,6} Citron et al²² noted that amphetamine-related vasculitis could be histologically characterized as necrotizing angiitis in multiple organs, including the neurologic system, with a resemblance to periarteritis nodosa. Radiographically, cerebral vasculitis associated with MA is best described on arteriography of cerebral vessels, which shows a diffusely pronounced irregularity of flow with arterial narrowing and cerebral artery beading.^{6,11,12,21}

The anatomic and histologic description of MA-related CVAs may lend knowledge about the physiology behind the type of stroke that results. Vasculitis and subsequent arterial narrowing secondary to long-term exposure to MA with an acute vascular spasm have frequently been postulated to have led to a cerebral ischemic event.^{6,21} In the case of patients suffering a spontaneous ICH without vasculitis or vessel malformations, few theories have been proposed about its pathophysiology. Studies have indicated that spontaneous nontraumatic ICHs are most commonly secondary to hypertensive disease.²³ With MA known to increase both systolic and diastolic blood pressures with dosages slightly higher than the therapeutic dose (5–25 mg),²⁴ it is quite probable that an ICH secondary to hypertension can occur acutely at very elevated doses of MA, as in the case of our patient (250–500 mg; Table 1). More often, the advent of spontaneous MA-related ICHs is most likely secondary to gradual vessel weakening with repeated drug abuse and an acute elevated blood pressure at the time of ingesting MA.

Etiologic differentiations between hemorrhagic and ischemic strokes have been previously examined by the method of MA ingestion. CVAs have occurred with all modes of MA ingestion, including oral intake, inhalation, and

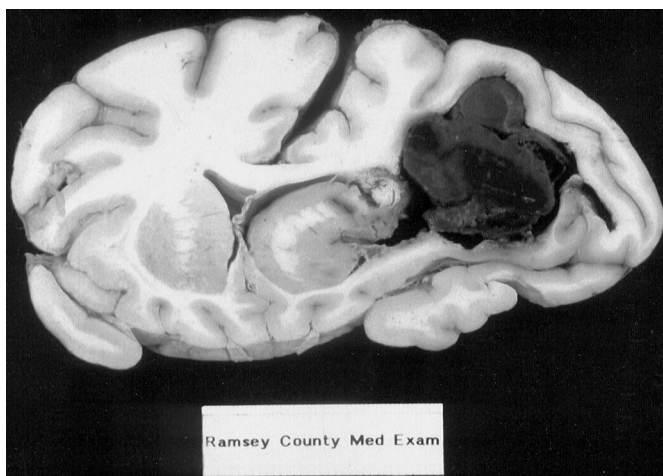


FIGURE 1. Intracerebral hemorrhage measuring 3.5 × 4.5 cm in the right cerebral hemisphere.

TABLE 1. Autopsy Findings and Clinical History of Reported Methamphetamine (MA)-Related Cerebral Vascular Accidents

Report/Series, Year	Autopsy Findings	Mode of MA Ingestion	Length of MA Abuse	Dosage Used	Time to Death
Bostwick et al., 1980 ⁶	Cerebral infarction with vasculitis	intravenous injection	multiple years	not given	9 days
Shibata et al., 1991 ⁵	Intracerebral hemorrhage (ICH) & subarachnoid hemorrhage (SAH) with vasculitis	intravenous injection	1 year	not given	51 hours; respiratory arrest at 13 hours
McGee et al., 2003	ICH & SAH without vasculitis	inhaled	under 1 year	up to 0.5 gram	9.5 hours

intravenous injection.^{17,20,21,25} Reports have contemplated whether ischemic strokes are associated to the inhalation of MA, while oral and intravenous injection show a predilection for cerebral hemorrhage.^{6,8,14,21} The deceased in our case inhaled MA and suffered from a fatal ICH and SAH without evidence of infarction or vasculitis (Table 1). Although our findings do not correlate with previous reports, Yen et al²⁵ have shown that MA inhalers may be susceptible to either hemorrhagic or ischemic strokes.

The longevity of MA abuse prior to a stroke may indicate the type of CVA that results. Few reports and series have detailed the patient's past medical history to include long-term illicit drug abuse. The majority of patients with long-term abuse of MA in these reports are described as having vasculitic changes demonstrated on cerebral angiography. Similar to the inflammatory changes described in animal studies with long-term exposure to increased levels of cocaine,²⁶ the examiner would expect a patient to develop vasculitis over an extended period of time secondary to another sympathomimetic, such as MA. In the 2 previous reports describing autopsy findings, both deceased had vasculitis, with one suffering from a subsequent cerebral infarct after abuse of MA for close to a decade.⁶ The second deceased had an ICH with an indeterminate history of MA abuse until 1 year previously (Table 1).⁵ The deceased described in our report had no acute history of abusing MA and suffered from an ICH, without histologically appreciating vasculitis (Table 1). Although more studies are needed, within these 3 patients the duration of MA abuse seems to have an impact on the formation of vessel inflammation and subsequently the type of CVA secondary to the drug.

Patients suffering from MA-related ICHs and a concomitant SAH have a decreased time to death when compared with ischemic strokes. This may seem inherent since ICHs, regardless of their cause or association, end in death 45% of the time compared with 12% for cerebral infarcts.¹³ Still, the mortality of MA-related ICHs is even greater when a concomitant SAH is taken into consideration. Studies have shown that up to 15% of patients die before they receive medical attention and another 10% die within 24 hours after

the onset of a SAH.²⁷⁻²⁹ With the majority of MA-related CVAs attributed to ICHs and the deceptively low average age of patients presenting with stroke symptoms secondary to MA (approximately 30 years old), information is needed regarding the time to death. The 2 previous case reports describing autopsy findings have calculated the time span from MA ingestion to death in a hospital as 2 and 9 days (Table 1).^{5,6} In these reports, both patients had a deterioration of neurologic status proceeding to a comatose state, with eventual respiratory arrest or brain death. The deceased in our case showed acutely deteriorating physical and neurologic findings consistent with the location of the ICH, which progressed to fatality 9.5 hours after MA inhalation (Table 1). The deceased previously described by Shibata et al,⁵ suffering an ICH, died 51 hours after MA injection with appropriate medical intervention, but respiratory arrest was reported to have occurred at 13 hours after MA ingestion. Both the deceased in our case and the deceased described in this report suffered a fatal arrest secondary to an ICH and SAH in a shorter time span (9.5 and 13 hours) when compared with an ischemic stroke without a SAH (9 days).

Death secondary to a CVA in young persons are tragic and sometimes misleading due to the relative infrequency of strokes in a younger age group. With the resurgence of MA abuse, CVAs related to MA as the cause of nontraumatic neurologic deficits and respiratory distress in younger patients have become higher on the differential diagnosis in emergency departments³⁰ and need to be correctly identified on postmortem examinations. In this case, the deceased suffered from a fatal spontaneous ICH and SAH without evidence of vasculitis less than 10 hours after inhalation of MA. Although the etiology of the CVA cannot be deduced by method of ingestion alone, our deceased's short-term exposure to MA, decreased time to death, and dosage of MA may help to suggest an ICH on to postmortem examination. Further understanding of spontaneous ICHs related to MA abuse will require diligent surveillance and detailed anatomic description on further postmortem examinations with clinical correlation.

REFERENCES

1. Centers for Disease Control and Prevention. Increasing mortality and morbidity associated with abuse of methamphetamine-United States, 1991–1994. *MMWR Morb Mortal Wkly Rep.* 1995;44:882–886.
2. US Department of Justice, Drug Enforcement Agency. Methamphetamine situation in the United States. *Drug Intelligence Rep.* 1996;DEA-96012:3–19.
3. Zhu B, Oritani S, Shimotouge K, et al. Methamphetamine-related fatalities in forensic autopsy during 5 years in the southern half of Osaka City and surrounding areas. *Forensic Sci Int.* 2000;113:443–447.
4. Logan B, Fligner C, Haddix T. Cause and manner of death in fatalities involving methamphetamine. *J Forensic Sci.* 1998;43:28–34.
5. Shibata S, Mori K, Sekine I, et al. Subarachnoid and intracerebral hemorrhage associated with necrotizing angiitis due to methamphetamine abuse: an autopsy case. *Neurol Med Chir (Tokyo).* 1991;31:49–52.
6. Bostwick D. Amphetamine induced cerebral vasculitis. *Hum Pathol.* 1980;12:1031–1033.
7. Salanova V, Taubner R. Intracerebral haemorrhage and vasculitis secondary to amphetamine use. *Postgrad Med J.* 1984;60:429–430.
8. Delaney P, Estes M. Intracranial hemorrhage with amphetamine abuse. *Neurology.* 1980;30:1125–1128.
9. Harrington H, Heller A, Dawson D, et al. Intracerebral hemorrhage and oral amphetamine. *Arch Neurol.* 1983;40:503–507.
10. NG L, Hamilton D, Chalmers T. Intra-cranial haemorrhage from drug abuse. *Br J Clin Pract.* 1986;40:255–256.
11. Yu Y, Cooper D, Wellenstein D, et al. Cerebral angiitis and intracerebral hemorrhage associated and methamphetamine abuse. *J Neurosurg.* 1983;58:109–111.
12. Yarnell P. “Speed”: headache and hematoma. *Headache.* 1977;17:69–70.
13. Thrift A, Dewey H, Macdonnell R, et al. Incidence of major stroke subtypes: initial findings from the North East Melbourne Stroke Incidence Study (NEMESIS). *Stroke.* 2001;32:1732–1738.
14. Caplan L, Hier D, Banks G. Current concepts of cerebrovascular disease-stroke: stroke and drug abuse. *Stroke.* 1982;13:860–872.
15. Kase C. Intracerebral hemorrhage: non-hypertensive causes. *Stroke.* 1986;17:590–595.
16. Olsen E. Intracranial hemorrhage and amphetamine usage. *Angiology.* 1977;28:464–471.
17. Matick H, Anderson D, Brumlik J. Cerebral vasculitis associated with oral amphetamine overdose. *Arch Neurol.* 1983;40:253–254.
18. Lukes S. Intracerebral hemorrhage from an arteriovenous malformation after amphetamine injection. *Arch Neurol.* 1983;40:60–61.
19. Davis G, Swallow C. The incidence of acute cocaine or methamphetamine intoxication in deaths due to ruptured cerebral (berry) aneurysms. *J Forensic Sci.* 1996;41:626–628.
20. Sachdeva K, Woodward K. Caudal thalamic infarction following intranasal methamphetamine use. *Neurology.* 1989;39:305–306.
21. Rothrock J, Rubenstein R, Lyden P. Ischemic stroke associated with methamphetamine inhalation. *Neurology.* 1988;38:589–592.
22. Citron B, Halpern M, McCarron M, et al. Necrotizing angiitis associated with drug abuse. *JAMA.* 1970;283:1003–1011.
23. Mohr J, Caplan L, Melski J, et al. The Harvard Cooperative Stroke Registry: a prospective registry. *Neurology.* 1978;28:754–762.
24. Hardman J, Gilman A, Goodman L. *Goodman and Gilman's: The Pharmacological Basis of Therapeutics.* 7th ed. New York, NY: MacMillan Publishing Co; 1985.
25. Yen D, Wang S, Ju T, et al. Stroke associated with methamphetamine inhalation. *Eur Neurol.* 1994;34:16–22.
26. Barroso-Moguel R, Villeda-Hernandez J, Mendez-Armenta M, et al. Brain capillary lesions produced by cocaine in rats. *Toxicol Lett.* 1997;92:9–14.
27. Bonita R, Thomson S. Subarachnoid hemorrhage: epidemiology, diagnosis, management, and outcome. *Stroke.* 1985;16:591–594.
28. Inagawa T, Tokuda Y, Ohbayashi N, et al. Study of aneurysmal subarachnoid hemorrhage in Izumo City, Japan. *Stroke.* 1995;26:761–766.
29. Inagawa T, Shibukawa M, Inokuchi F, et al. Primary intracerebral and aneurysmal subarachnoid hemorrhage in Izumo City, Japan, part II: management and surgical outcome. *J Neurosurg.* 2000;93:967–975.
30. Perez J, Arsur E, Strategos S. Methamphetamine-related stroke: four cases. *J Emerg Med.* 1999;17:469–471.