

## Chagas' Disease: Another Cause of Cerebral Mass in the Acquired Immunodeficiency Syndrome

DANIEL GLUCKSTEIN, M.D., FLAVIO CIFERRI, M.D., M.P.H., JOEL RUSKIN, M.D.,  
Los Angeles, California

**We report the first case of Chagas' disease causing a brain mass in the acquired immunodeficiency syndrome (AIDS). The illness occurred in a patient living outside a traditional chagasic endemic area and represented reactivation of long dormant *Trypanosoma cruzi* infection. A Salvadoran-born resident of the United States with diagnosed AIDS developed hemiparesis due to a brain mass. Histopathologic examination and culture of a brain biopsy specimen established that *T. cruzi* infection produced the lesion. The patient's epidemiologic history excluded newly acquired trypanosomal infection. Thus, cerebral Chagas' disease must now be considered another potential opportunistic infection in AIDS. This is of particular concern as the pandemic spreads to large Latino populations previously exposed to infection with the parasite.**

Intracranial mass lesions pose a difficult diagnostic problem in patients with the acquired immunodeficiency syndrome (AIDS). While AIDS-associated brain masses commonly result from toxoplasmosis or lymphoma, the list of differential diagnostic possibilities encompasses diverse conditions, such as progressive multifocal leukoencephalopathy and infections with fungi, bacteria, and mycobacteria [1,2]. In this communication, we describe another cause of a brain lesion in AIDS: infection with the protozoan agent of Chagas' disease, *Trypanosoma cruzi*. To our knowledge, this is the first description of this unusual manifestation of Chagas' disease in AIDS. Moreover, it occurred outside an endemic area for *T. cruzi* infection.

### CASE REPORT

A 32-year-old Hispanic man initially presented with a 2-month history of watery diarrhea. Examination of his stool revealed cysts of *Isoospora belli*. The patient was treated with trimethoprim-sulfamethoxazole and his diarrhea gradually resolved. Enzyme-linked immunosorbent assay and Western blot tests for antibody to human immunodeficiency virus (HIV) were positive and a diagnosis of AIDS was made [3].

The patient was a homosexual and denied any other risk factors for HIV infection. He had never used intravenous drugs and had not received blood transfusions. He had spent his childhood in a rural village in El Salvador but had lived continuously in Los Angeles for 6 years before he became ill.

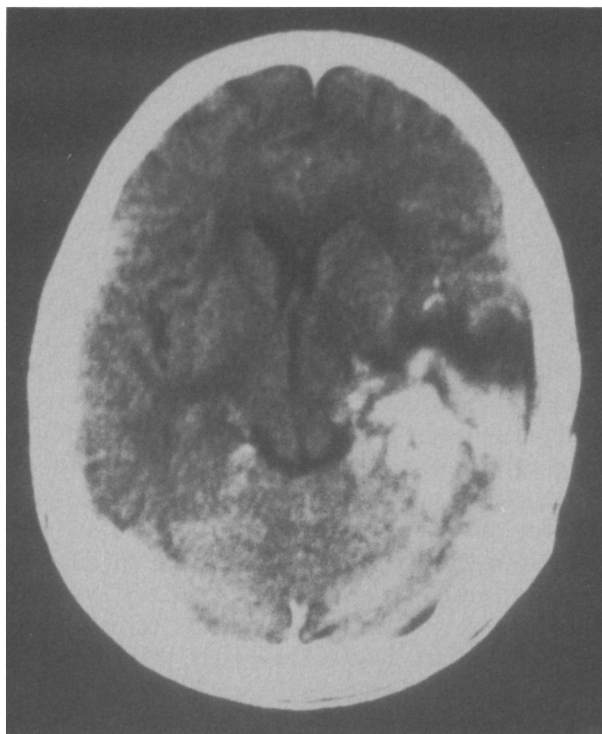
Three months after his first evaluation, he was admitted to the hospital with the acute onset of fever, right-sided weakness, aphasia, and decreased visual acuity. On physical examination, he was cachectic and lethargic with a right hemiparesis. The blood pressure was 122/70 mm Hg, pulse 112 beats/minute, respiratory rate 18/minute, and rectal temperature 38.8°C. Thrush was present on the tongue and mucous membranes of the mouth. Papilledema without retinitis was noted on direct funduscopy. The remainder of the examination was normal. Laboratory studies showed a white blood cell count of 4,900/mm<sup>3</sup> with 60% neutrophils, 20% band forms, 12% lymphocytes, and 8% monocytes. The hematocrit was 34.7% and the platelet count was

From the Divisions of Infectious Diseases (DG, JR) and Parasitology (FC), Department of Internal Medicine, Kaiser Permanente Medical Center, Los Angeles, California.

Presented in part at the 28th Interscience Conference on Antimicrobial Agents and Chemotherapy, Los Angeles, 1988.

Requests for reprints should be addressed to Joel Ruskin, M.D., Infectious Diseases Service, Kaiser Permanente Medical Center, 1505 North Edgemont Street, Los Angeles, California 90027.

Manuscript submitted February 20, 1991, and accepted March 20, 1991.



**Figure 1.** Cranial computerized tomographic scan (with contrast) showing enhancing left temporal lobe mass.

254,000/mm<sup>3</sup>. Serum chemistry values were within normal limits except for a serum glutamic oxaloacetic transaminase level of 125 IU/L and an albumin level of 3.2 g/dL. The CD4 lymphocyte count was 45/mm<sup>3</sup>. The chest roentgenogram was unremarkable; a tuberculin skin test (5TU) done 1 month earlier was negative.

A cranial computed tomographic scan demonstrated an irregular contrast-enhancing lesion of the left temporal lobe with edema and mass effect (**Figure 1**). Cultures of blood and urine yielded no bacteria, mycobacteria, fungi, or viruses. Serologic tests for infection with *Toxoplasma gondii*, *Cryptococcus neoformans*, and *Treponema pallidum* were negative.

The patient was empirically treated with dexamethasone, ampicillin, cefotaxime, metronidazole, acyclovir, and pyrimethamine and sulfadiazine. On this regimen, he became more obtunded, and his overall clinical condition worsened. A stereotactic brain biopsy was performed on the 12th hospital day. Frozen section of the tissue biopsy revealed chronic inflammation and intracellular forms resembling *Histoplasma capsulatum*. Therapy with amphotericin B was begun, but the patient died 48 hours later. An autopsy was not obtained.

The permanent sections of the brain showed that the numerous intracellular forms were, in fact, protozoan amastigotes (**Figure 2**). Epimastigotes and

other morphologic stages characteristic of *T. cruzi* developed over 72 hours in a homogenate of the brain biopsy specimen maintained at 4°C (**Figure 3**). Culture of the biopsy material in Novy-MacNeal-Nicolle media yielded epimastigote forms that stained intensely with monoclonal antibody to *T. cruzi* but did not fluoresce with monoclonal antibody to *Trypanosoma rangeli* (**Figure 4**). (These studies were kindly performed by Dr. M. Grögl, Walter Reed Army Institute of Research, Washington, D.C., using a modification of a method previously described [4].) Serologic tests for infection with *T. cruzi* done at the Centers for Disease Control revealed immunofluorescent antibody in a titer of 1:32 and absent complement-fixing antibody. Trypomastigotes were not seen on white blood cell differential smears. Cultures of the brain were negative for bacteria, mycobacteria, fungi, and viruses.

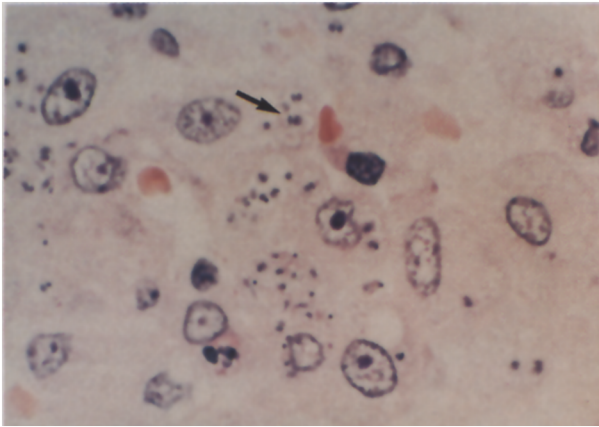
## COMMENTS

This case study confirms that a resident of the United States with AIDS developed a brain abscess due to infection with *T. cruzi*. That the infection represented reactivation of latent Chagas' disease is apparent from the patient's history. Almost certainly he was initially infected as a child in rural El Salvador where *T. cruzi* infection is endemic [5]. He spent most of his adult life in California, where only one autochthonous case of Chagas' disease has ever been recorded [6]. Also, he had no exposure to blood products. Thus, he could not have experienced transfusion-associated Chagas' disease, a recently reported complication in other immunocompromised patients in North America [7,8].

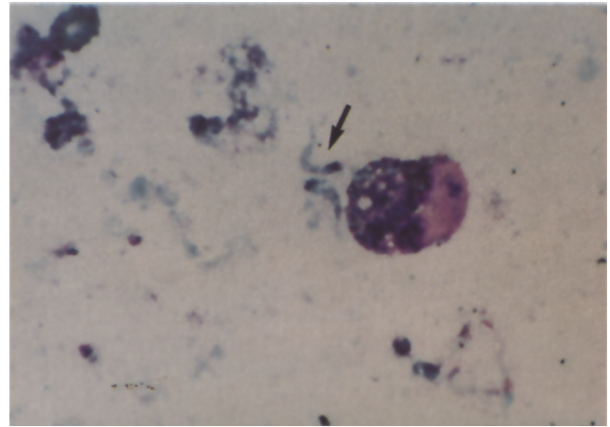
The classic syndromes associated with chronic Chagas' disease, namely, cardiomyopathy, megacolon, and megaesophagus, are well known [9]. In contrast, we are aware of only five reports of tumor-like brain lesions caused by the parasite [10–14]. These have occurred solely in immunosuppressed patients in South America with underlying mycosis fungoides, acute lymphocytic leukemia, renal transplantation, and congenital immunodeficiency.

It is noteworthy that asymptomatic seeding of the brain with trypanosomes is common in acute Chagas' disease [15] and that in experimental infection an intact cellular immune system (specifically, CD4 lymphocytes) is required to limit replication of the parasite [16]. Conceivably, therefore, dormant foci of *T. cruzi* in brain could "reactivate" in patients with impairment of cell-mediated immune function.

The potential for interaction of HIV disease and trypanosomiasis merits systematic study. In Brazil, where an estimated 6 million persons are infected with the parasite [17], no evidence of Chagas' dis-



**Figure 2.** Brain tissue with many intracellular amastigote forms (arrow) (hematoxylin and eosin; 1,000X).



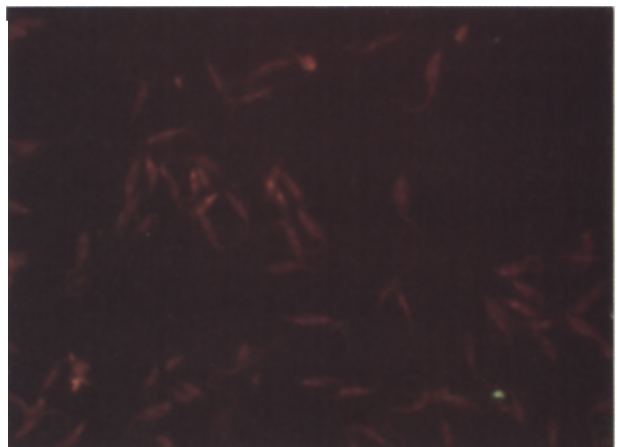
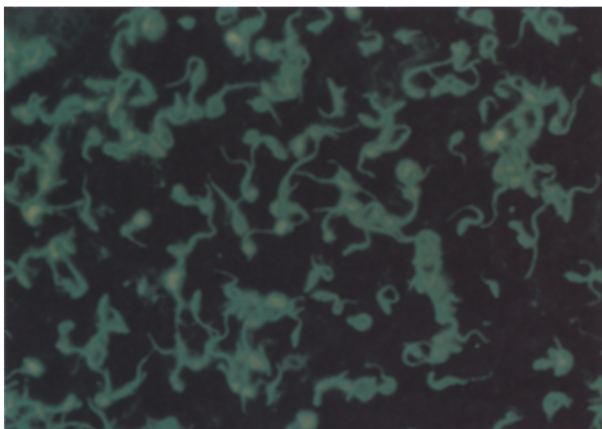
**Figure 3.** Brain tissue homogenate showing epimastigotes and other intermediate forms of *T. cruzi* (arrow) (Wright; 1,000X, original magnification  $\times 3$ ).

ease was detected in an autopsy series of 15 patients with AIDS [18]. There is, however, one recent report of an HIV-seropositive hemophiliac in Argentina who did appear to have cerebral *T. cruzi* infection [19]. The patient had a frontal lobe mass that on histopathologic examination showed intracellular amastigotes. Unfortunately, unequivocal identification of *T. cruzi* was not possible since brain specimens were not cultured.

Even if this were a chagasic brain mass, its relation to the patient's HIV infection was uncertain. The precise extent of his immune dysfunction was not noted, and his likely exposure to blood products and residence in a chagasic endemic region were confounding etiologic factors. By contrast, the brain abscess in our patient clearly developed in a setting of profound immunodeficiency caused by pre-existing AIDS and could only have resulted from reactivation of previously quiescent *T. cruzi* infection acquired years earlier.

The therapy of Chagas' disease has been problematic at best. Drugs usually employed, such as nifurtimox or benznidazole, possess significant toxicity and do not consistently afford parasitologic cure [20]. However, a few immunocompromised patients with cerebral Chagas' disease have clinically improved while receiving nifurtimox [13,14,19]. Furthermore, recent investigations suggest that interferon- $\gamma$  and allopurinol may prove to be less toxic therapeutic alternatives [7,21,22]. Given the possibility of increasingly effective antitrypanosomal treatment, a strategy of early brain biopsy would appear to be indicated in AIDS patients suspected of having intracranial infection with the parasite. Screening HIV-positive patients from chagasic areas for antibody to *T. cruzi* may identify those at risk for this complication.

In conclusion, our case report demonstrates that Chagas' disease can reactivate in patients with



**Figure 4.** Epimastigotes from Novy-MacNeal-Nicolle media culture of brain tissue stained with monoclonal fluorescent antibodies to *T. cruzi* (left) and *T. rangeli* (right) (1,000X, original magnification  $\times 3$ ). (Performed courtesy of Dr. M. Grögl, Walter Reed Army Institute of Research, Washington, D.C.)

**AIDS and present as a brain mass indistinguishable from other opportunistic infectious or neoplastic processes. This finding raises the disturbing prospect that atypical and severe infection with *T. cruzi* may well become a substantial problem in both indigenous and immigrant Latin American populations affected by the HIV pandemic.**

## ACKNOWLEDGMENT

We thank Max Grögl, Ph.D., Department of Parasitology, Division of Experimental Therapeutics, Walter Reed Army Institute of Research, Washington, D.C., for his invaluable assistance and technical expertise in performing the immunofluorescence studies.

## REFERENCES

1. Snider WD, Simpson DM, Nielson S, Gold JWM, Metroka CE, Posner JB. Neurological complications of the acquired immunodeficiency syndrome: analysis of 50 patients. *Ann Neurol* 1983; 14: 403-18.
2. Elder GA, Sever JL. Neurologic disorders associated with AIDS retroviral infection. *Rev Infect Dis* 1988; 10: 286-302.
3. Centers for Disease Control. Revision of the CDC surveillance case definition for acquired immunodeficiency syndrome. *MMWR* 1987; 36 Suppl 1: 3S-15S.
4. Camargo ME. Fluorescent antibody test for the serodiagnosis of American trypanosomiasis. Technical modification employing preserved culture forms of *Trypanosoma cruzi* in a slide test. *Rev Inst Med Trop Sao Paulo* 1966; 8: 227-34.
5. Cedillos RA. Chagas' disease in El Salvador. *Bull Pan Am Health Organ* 1975; 9: 135-41.
6. Schiffler RJ, Mansur GP, Navin TR, Limpakarnjanarat K. Indigenous Chagas' disease (American trypanosomiasis) in California. *JAMA* 1984; 251: 2983-4.
7. Grant IH, Gold JWM, Wittner M, et al. Transfusion-associated acute Chagas disease acquired in the United States. *Ann Intern Med* 1989; 111: 849-51.
8. Nickerson P, Orr P, Schroeder ML, Sekla L, Johnston JB. Transfusion-associated *Trypanosoma cruzi* infection in a non-endemic area. *Ann Intern Med* 1989; 111: 851-3.
9. Kirchhoff LV. *Trypanosoma* species (American trypanosomiasis, Chagas disease): biology of trypanosomes. In: Mandell GL, Douglas RG Jr, Bennett JE, editors. Principles and practice of infectious diseases. 3rd ed. New York: Churchill Livingstone, 1990; 2077-84.
10. deQueiroz AC. Tumor-like lesion of the brain caused by *Trypanosoma cruzi*. *Am J Trop Med Hyg* 1973; 22: 473-6.
11. Pizzi TP, Acosta de Croizet V, Smok G, Diaz MA. Enfermedad de Chagas en un paciente con trasplante renal y tratamiento inmunosupresor. *Rev Med Chil* 1982; 110: 1207-11.
12. Sevelever G, Taratuto AH, de las Carreras MC, Leiguarda R, Nogués M. Catatonia secondary to acute Chagas' encephalitis [letter]. *J Neurol Neurosurg Psychiatry* 1987; 50: 1244.
13. Silvana Corona S, Amanales C, de Los Angeles Avaria MB, et al. Granuloma chagásico del cerebro en un paciente con leucemia linfoblástica. *Rev Med Chil* 1988; 116: 676-80.
14. Leiguarda R, Roncoroni A, Taratuto AL, et al. Acute CNS infection by *Trypanosoma cruzi* (Chagas' disease) in immunosuppressed patients. *Neurology* 1990; 40: 850-1.
15. Hoff R, Teixeira RS, Carvalho JS, Mott KE. *Trypanosoma cruzi* in the cerebrospinal fluid during the acute stage of Chagas' disease. *N Engl J Med* 1978; 298: 604-6.
16. Ben Younés-Chennoufi A, Said G, Eisen H, Durand A, Hontebeyrie-Joskowicz M. Cellular immunity to *Trypanosoma cruzi* is mediated by helper T cells (CD4+). *Trans R Soc Trop Med Hyg* 1988; 82: 84-9.
17. Dias JCP. Control of Chagas' disease in Brazil. *Parasitology Today* 1987; 3: 336-41.
18. Michalany J, Mattos ALA, Michalany NS, Filie AC, Montezzo LC. Acquired immunodeficiency syndrome in Brazil: necropsy findings. *Ann Pathol* 1987; 7: 15-24.
19. Del Castillo M, Mendoza G, Oviedo J, Perez Bianco RP, Anselmo AE, Silva M. AIDS and Chagas' disease with central nervous system tumor-like lesion. *Am J Med* 1990; 88: 693-4.
20. Marr JJ, Docampo R. Chemotherapy for Chagas' disease: a perspective of current therapy and considerations for future research. *Rev Infect Dis* 1986; 8: 884-903.
21. Reed SG. *In vivo* administration of recombinant interferon-gamma induces macrophage activation, and prevents acute disease, immune suppression, and death in experimental *Trypanosoma cruzi* infections. *J Immunol* 1988; 140: 4342-7.
22. Gallerano RH, Marr JJ, Sosa RR. Therapeutic efficacy of allopurinol in patients with chronic Chagas' disease. *Am J Trop Med Hyg* 1990; 43: 159-66.