

Chun-Chi Huang · Yi-Ho Young

Vertigo with rebound nystagmus as an initial manifestation in a patient with basilar artery occlusion

Received: 1 June 2004 / Accepted: 7 September 2004 / Published online: 9 December 2004
© Springer-Verlag 2004

Abstract Basilar artery occlusion (BAO) is generally associated with a high mortality rate and a poor functional outcome in survivors. Recently, we encountered a patient with BAO, initially manifesting as vertigo and rebound nystagmus, subsequently followed by bilateral sudden deafness and dysarthria and terminating in a coma state within an interval of 6 h. A review of his history showed he had had two episodes of transient vertigo 2 weeks before the major stroke, and the neurological decline of BAO was heralded by the vertiginous symptoms. Restated, patients with BAO often have transient vertiginous attacks preceding fatal stroke. Therefore, those with vertigo and nystagmus may be signaling a forthcoming stroke event, something that should be considered for clinicians seeing vertiginous patients.

Keywords Basilar artery occlusion · Vertigo · Rebound nystagmus · Bilateral sudden deafness

Introduction

Vertigo and nystagmus as an initial or even the sole manifestation of posterior fossa ischemia is not uncommon [1, 2]. Of them, basilar artery occlusion (BAO) is generally associated with a high mortality rate and a poor functional outcome in survivors [3]. It may cause bilateral sudden deafness, representing a warning of impending brainstem infarction, usually accompanied by multiple brainstem and cerebellum signs [4, 5, 6, 7, 8]. Compared to unilateral sudden deafness, bilateral

simultaneous sudden deafness is a rare condition, representing 0.44–2.78% of sudden deafness [9, 10].

Strokes in the territory of the anterior inferior cerebellar artery (AICA) are usually associated with BAO, possibly because of an atheromatous plaque within the basilar artery extending into the AICA ostia, thus decreasing the blood flow and leading to bilateral sudden deafness. In addition to the latter, vertigo associated with nystagmus presents an early sign for BAO, whereas dysarthria and oculomotor deficits manifest as late signs, heralding a major impending neurological event [11]. Recently, we encountered a patient with BAO initially manifesting as vertigo and rebound nystagmus, subsequently as bilateral sudden deafness and dysarthria and terminating in a coma state, within an interval of 6 h. Herein, we present this case.

Case report

A 51-year-old man had been rather healthy in the past, without smoking or drinking alcohol. He denied any systematic disease such as diabetes mellitus, hypertension or coronary artery disease. On 17 March 2004, he had a transient vertiginous episode for the first time, which lasted for 20 to 30 s and resolved spontaneously. A second episode accompanied by nausea and vomiting occurred on March 25, which caused him to be brought him to a local hospital, where he stayed at the emergency service for 6 h until he had relief from the vertigo. He was treated with some anti-vertigo medication, but no definite conclusion about his condition was reached. Unfortunately, the third vertiginous episode occurred on the morning of April 1, and he was sent to our hospital and admitted to our ward at 12:30 p.m.

On admission, he was alert and bed-ridden. A vestibular functional test revealed bilateral gaze nystagmus, but no hearing loss, tinnitus or aural fullness was experienced, except for facial numbness on the left side. Electronystagmography (ENG) showed bilateral gaze nystagmus and rebound nystagmus from the right lat-

C.-C. Huang · Y.-H. Young (✉)
Department of Otolaryngology, National Taiwan University
Hospital and National Taiwan University College of Medicine,
1 Chang-Te St., Taipei, Taiwan
E-mail: youngyh@ha.mc.ntu.edu.tw
Tel.: +886-2-23123456/5221
Fax: +886-2-23946674

eral gaze to the forward gaze, with its fast phase beating toward the left side (Fig. 1). Both eye tracking and optokinetic nystagmus tests revealed abnormality. An ice water caloric test indicated hyporeflexia in the right ear with loss of visual suppression and an absent response in the left ear. Oculomotor deficits such as conjugate deviation to the right side were disclosed at 2:30 p.m., manifested as right gaze palsy in both eyes. In the meantime, his consciousness remained alert, and he could follow order for performing eye movement and doing mental arithmetic.

Under the suspicion of posterior fossa stroke, an emergent MRI scan was performed at 4:00 p.m., which demonstrated acute ischemic infarction at both sides of the cerebellum, with more on the left (Fig. 2). Thereafter, he was administered hydroxyethyl starch and osmotic agents, intravenously. At 5:00 p.m., this patient suddenly shouted loudly that he could not hear anything; subsequently, dysarthria and agitation occurred. Neurological examination revealed bilateral total deafness, but the bilateral pupils were isocoric with light reflexes preserved. His condition descended into unconsciousness at 6:30 p.m. After endotracheal intubation, he was transferred to the intensive care unit with the coma scale of $E_1M_1V_1$.

Tracing his laboratory data on admission, the biochemical profile was within normal limits, except high cholesterolemia (serum level of total cholesterol: 346 mg/dl). The extracranial Doppler ultrasonography showed basilar artery occlusion without visualization of the left posterior cerebral artery. One month later, he was transferred to a sanitarium in a state of coma and tetraplegia.

Fig. 1 Electronystagmography shows bilateral gaze nystagmus and rebound nystagmus from right lateral gaze (RG) to forward gaze (F), with its fast phase beating toward the left side. Upper trace is nystagmus movement. Lower trace is differentiated eye movement indicating eye velocity. LG left lateral gaze

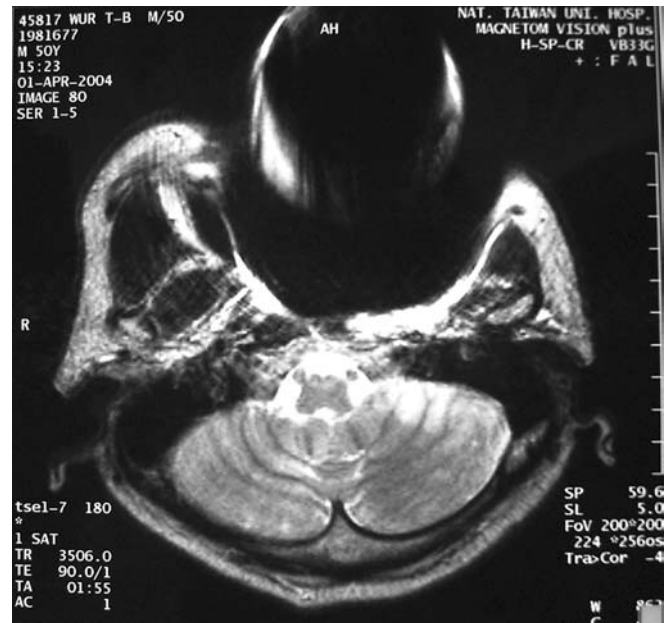
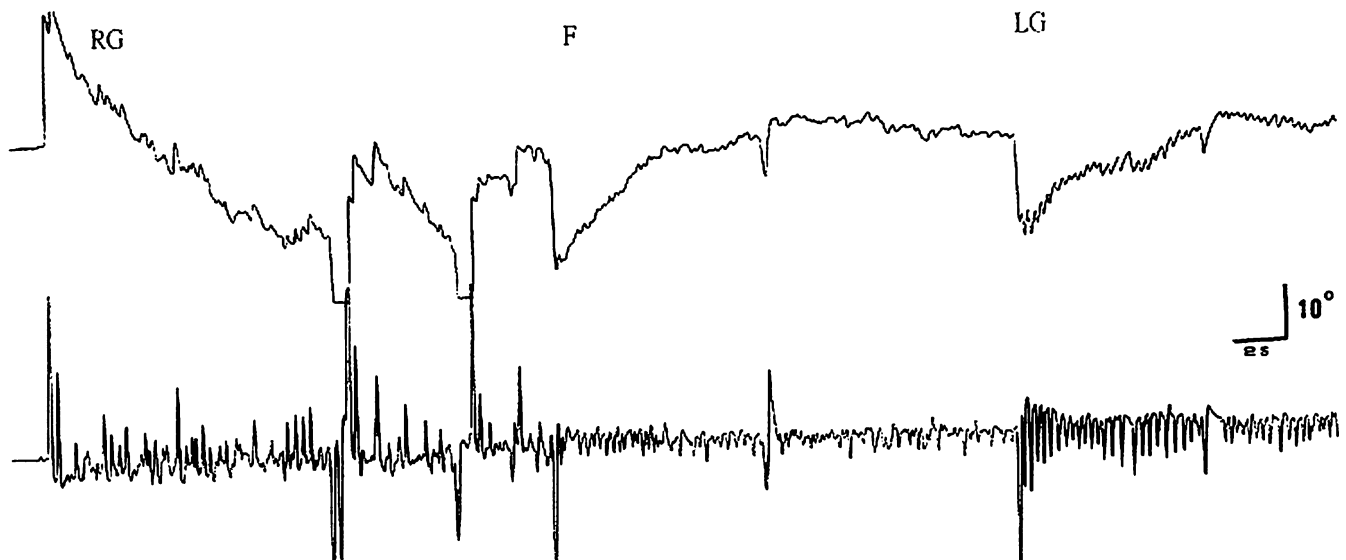


Fig. 2 T2-weighted MRI scan, axial view, demonstrates acute ischemic infarction at both sides of cerebellum, more on the left side

Discussion

Slightly more than one-third of patients with posterior fossa stroke have had a transient ischemic attack (TIA) of the vertebrobasilar artery preceding the stroke [3]. In contrast, TIAs preceding stroke caused by BAO have been reported in approximately 60% [12, 13]. In this patient, two episodes of transient vertigo (TIAs) had occurred 2 weeks before the major stroke [11, 12, 13]. Restated, the neurological decline of BAO was heralded by several warning episodes of waxing and waning vertiginous symptoms. Hence, repeated transient vertigo warrants concern. Awareness of the neurological evaluation of BAO could allow treatment to be directed more effectively and improve its outcome [11].

The scenario in this patient consisted of vertigo and rebound nystagmus initially, bilateral sudden deafness and dysarthria subsequently, and terminated in a coma state. The whole course occurred within only 6 h. This is consistent with the literature, which states that once the neurological decline has begun, it takes at least 6 h and up to 3 days to reach the final neurological features [11].

In the absence of diabetes mellitus, hypertension or coronary artery disease, the etiology of BAO in this patient was attributed to an atherosclerotic basilar artery since the serum level of the total cholesterol was up to 346 mg/dl. Restated, the primary mechanism of stroke in this patient was due to thrombo-embolism in the basilar artery.

BAO has been shown to be associated with strokes in the territory of the AICA, possibly because an atheromatous plaque within the basilar artery extends into the AICA ostia. Bilateral AICA territory is thought to be a terminal zone for retrograde collateral flow from the circle of Willis after an occlusion of basilar origin. Furthermore, the internal auditory artery (IAA) usually arises from the AICA and supplies the inner ear with minimal collaterals. Hence, occlusion of bilateral AICAs or IAAs led to bilateral sudden deafness in this patient.

Nevertheless, bilateral simultaneous sudden deafness is exceptional in focal lesions of the brainstem. The reason is that an extensive brainstem lesion is required to interrupt the crossed and uncrossed auditory fibers at the level of the lateral lemniscus or inferior colliculus. Compared with brainstem injury, it rarely induces bilateral total deafness, because the crossed and uncrossed auditory fibers would be totally disrupted [14].

In addition to bilateral sudden deafness, characteristic abnormal eye movements such as rebound nystagmus (Fig. 1) were disclosed at the very beginning of the major stroke attack. Rebound nystagmus is a type of nystagmus that occurs when a patient returns the eyes to the primary position after a prolonged attempt at an eccentric gaze [15]. During eccentric fixation, the cerebellum participates in the velocity bias that opposes drift eye movements [16, 17], whereas during central fixation, through gaze stabilization systems (i.e., smooth pursuit and fixation), the cerebellum mediates the rapid discharge of the rebound nystagmus velocity bias. Clinically, rebound nystagmus is most frequently encountered in patients with cerebellar lesions involving the flocculus and paraflocculus, compatible with the loss of visual suppression in caloric nystagmus, as was the case for our patient [18]. Furthermore, conjugate deviation was attributed to the dysfunction of the pons and the midbrain, especially the paramedian and tegmental portions [19], consistent with multiple brainstem infarcts. Other manifestations, e.g., lower cranial nerve deficits (dysarthria), bilateral extensor plantar responses and prominent motor deficits with a paucity of sensory findings also suggest brainstem involvement [11, 20].

Clinically, a large extent of brainstem infarct, rapid course, long duration of BAO and embolic origin were

correlated with a worse prognosis. Devuyst et al. [3] suggested that four clinical features, e.g., dysarthria, pupillary disorders, bulbar symptoms and consciousness disorder present on admission are highly significantly associated with a poor outcome ending in death or a major disability such as tetraplegia and coma, as was the case for our patient. Hence, patients with BAO often have transient vertiginous attacks preceding fatal stroke. Restated, those with vertigo and nystagmus may be signaling a forthcoming stroke event, something that should be considered by clinicians seeing vertiginous patients.

Acknowledgements This study was supported by grant no. NSC 93-2314-B002-114 from the National Science Council, Taipei, Taiwan

References

- Norrving B, Magnusson M, Holtas S (1995) Isolated acute vertigo in the elderly; vestibular or vascular disease? *Acta Neurol Scand* 91:43–48
- Magnusson M, Norrving B (1991) Cerebellar infarctions as the cause of ‘vestibular neuritis.’ *Acta Otolaryngol [Suppl]* 481:258–259
- Devuyst G, Bogousslavsky J, Meuli R, Moncayo J, Freitas G, Melle G (2002) Stroke or transient ischemic attacks with basilar artery stenosis or occlusion: clinical patterns and outcome. *Arch Neurol* 59:567–573
- Huang M-H, Huang C-C, Ryu S-J, Chu N-S (1993) Sudden bilateral hearing impairment in vertebrobasilar occlusive disease. *Stroke* 24:132–137
- Sunose H, Toshima M, Mitani S, Suzuki M, Yoshida F, Takasaka T (2000) Sudden bilateral hearing loss and dizziness occurred with cerebellar infarction. *Otolaryngol Head Neck Surg* 122:146–147
- Lee H, Yi HA, Baloh RW (2003) Sudden bilateral simultaneous deafness with vertigo as a sole manifestation of vertebrobasilar insufficiency. *J Neurol Neurosurg Psychiatry* 74:539–541
- Toyoda K, Hirano T, Kumai Y, Fujii K, Kiritoshi S, Ibayashi S (2002) Bilateral deafness as a prodromal symptom of basilar artery occlusion. *J Neurol Sci* 193:147–150
- Sauvaget E, Kici S, Petelle B, Kania R, Chabriet H, Herman P, Tran Ba Huy P (2004) Vertebrobasilar occlusive disorders presenting as sudden sensorineural hearing loss. *Laryngoscope* 114:327–332
- Fetterman BL, Luxford WM, Saunders JE (1996) Sudden bilateral sensorineural hearing loss. *Laryngoscope* 106:1347–1350
- Yanagita N, Murahashi K (1987) Bilateral simultaneous sudden deafness. *Arch Otorhinolaryngol* 244:7–10
- von Campe G, Regli F, Bogousslavsky J (2003) Heralding manifestations of basilar artery occlusion with lethal or severe stroke. *J Neurol Neurosurg Psychiatry* 74:1621–1626
- Ferbert A, Bruckmann H, Drummen R (1990) Clinical features of proven basilar artery occlusion. *Stroke* 21:1135–1142
- Brandt T, PessinMS, Kwan ES, Caplan LR (1995) Survival with basilar artery occlusion. *Cerebrovasc Dis* 5:182–187
- Vitte E, Tankere F, Bernat I, Zouaoui A, Lamas G, Soudant J (2002) Midbrain deafness with normal brainstem auditory evoked potentials. *Neurology* 58:970–973
- Lin CY, Young Y-H (1999) Clinical significance of rebound nystagmus. *Laryngoscope* 109:1803–1805
- Chung ST, Bedell HE (1995) ‘Dumping’ of rebound nystagmus and optokinetic afternystagmus in human. *Exp Brain Res* 107:306–314

17. Shallo-Hoffman J, Schwarze Hm Simonsz H, Muhlendyck H (1990) A reexamination of end-point and rebound nystagmus in normals. *Invest Ophthalmol Vis Sci* 31:388–392
18. Takemori S, Aiba T, Schizawa R (1981) Visual suppression of caloric nystagmus in brain-stem lesions. *Ann NY Acad Sci* 374:846–854
19. Cohen B, Komatsuzaki A (1972) Eye movements induced by stimulation of the pontine reticular formation: evidence for integration in oculomotor pathways. *Exp Neurol* 36:101–117
20. Fisher CM (1988) The ‘herald hemiparesis’ of basilar artery occlusion. *Arch Neurol* 45:1301–1303