

Departments of ¹Internal Medicine II (Gastroenterology), ²IV (Rheumatology), and ³I (Medical ICU), Center of Internal Medicine, University of Leipzig, Leipzig, Germany

A severe case of systemic lupus erythematosus with cerebral involvement

M. Wiedmann¹, W. Seidel², L. Mende³, S. Petros³ and L. Engelmann³

Summary

We describe an 18-year-old girl who presented with severe systemic lupus erythematosus with multiple organ involvement. The disease was further complicated by recurrent seizures and intracerebral left parieto-occipital bleeding that required neurosurgical treatment. Postoperative rebleeding occurred due to disseminated intravascular coagulation and platelet dysfunction. Catastrophic antiphospholipid syndrome was suspected, but could not be confirmed during follow-up. Additional treatment with plasmapheresis and intravenous pulse cyclophosphamide in combination with corticosteroids was started. Liquor drainage via a ventriculo-peritoneal (vp)-shunt was necessary because of a hydrocephalus malresorptivus. The patient's recovery was slow and incomplete (cachexia and amaurosis persisted). Follow-up was further complicated by an intraperitoneal vp-shunt cyst, which was initially treated conservatively, but finally had to be revised operatively.

Key words

Systemic lupus erythematosus, antiphospholipid syndrome, vasculitis

Zusammenfassung

Ein schwerer Fall eines systemischen Lupus erythematoses mit zerebralem Befall
Wir beschreiben den Fall einer 18-jährigen Patientin mit schwerem systemischem Lupus erythematoses mit Multiorganbeteiligung. Die Erkrankung war weiterhin durch wiederholte zerebrale Krampfanfälle und eine intrazerebrale, linksseitig lokalisierte, parieto-okzipitale Blutung kompliziert, die eine neurochirurgische Behandlung erforderte. Postoperativ trat wegen einer disseminierten intravaskulären Koagulation und einer Thrombozytendysfunktion eine erneute Blutung auf. Ein katastrophales Antiphospholipidsyndrom wurde vermutet, konnte aber nicht bestätigt werden. Eine zusätzliche Therapie mit Plasmapherese und intravenöser Zylophosphamidpulstherapie in Kombination mit Kortikosteroiden wurde begonnen. Eine Liquordrainage mittels ventrikulo-peritonealem (vp)-Shunt wurde wegen eines Hydrocephalus malresorptivus erforderlich. Die Genesung der Patientin verlief nur sehr langsam und inkomplett (eine Kachexie und Amaurose persistierten). Der weitere Verlauf wurde zusätzlich verkompliziert durch eine intraperitoneale vp-Shunt Zyste, die zunächst konservativ behandelt wurde, aber letztendlich einer operativen Revision bedurfte.

Introduction

Systemic lupus erythematosus (SLE) is a disease of unknown origin in which tissue damage is induced by pathogenic autoantibodies and immune complexes. The incidence of SLE is rising over the past four decades [16]. Its prevalence in Northern Europe and the United States is about 40 per 100,000 population, commonly affecting women of childbearing age [10].

Patients with both SLE and antiphospholipid antibodies may develop "antiphospholipid syndrome" in 50 to 70% after 20 years of follow-up. There is an association between antiphospholipid antibodies and a syndrome of hypercoagulability [2, 13]. Although venous thrombosis is the most common manifestation of this syndrome, arterial thromboses can also occur and most commonly manifest with features consistent with ischemia or infarction [2, 4, 18]. In addition, DIC, which is not a feature of primary or sec-

ondary antiphospholipid syndrome, occurs in approximately 25% of patients with catastrophic antiphospholipid syndrome, which is defined as the clinical involvement of at least three different organ systems over a period of days or weeks with histopathological evidence of multiple occlusions of large or small vessels [3]. The brain is the most common site for arterial thromboses in antiphospholipid syndrome and also affected in 56% of all catastrophic antiphospholipid syndromes.

Although antiphospholipid syndrome and catastrophic antiphospholipid syndrome are therefore important causes of brain infarction in patients with SLE, the differential diagnosis of SLE vasculitis has to be considered [19]. As our case report demonstrates, the differentiation between the three entities is often difficult in an acute clinical setting.

Abbreviations: BMI, body mass index; DIC, disseminated intravascular coagulation; ICP, intracranial pressure; ICU, intensive care unit; IVCYC, intravenous pulse cyclophosphamide; SLE, systemic lupus erythematosus

Case report

In April 2002, an 18-year-old girl was referred to the department of Hematology of our university hospital for a suspected lymphoma. The patient complained of fatigue, malaise and fever for four weeks. Past medical, social and family history were unremarkable. On admission, the girl was alert and oriented, but in a reduced general (Karnofsky 70%) and nutritional state (BMI 18.3). She was pale, and bilateral basal pulmonary rales as well as hepatosplenomegaly were detected on clinical examination. The remaining physical examination including neurological status was unremarkable.

A CT scan demonstrated an intraabdominal tumour, hepatosplenomegaly, pericardial and left pleural effusion, and unclear infiltration in the left lower lobe of the lung. Initial routine blood chemistry was normal apart from mild anemia (hemoglobin of 8.5 g/dl [normal 11.7–15.5]), thrombocytopenia ($117 \times 10^9/l$ [normal 150–300]), and hypoproteinemia (62.2 g/l [normal 66–87]), as well as a slight elevation of ASAT, GGT, LDH, and CK. CRP was 109.7 mg/l (normal < 5). A bone marrow biopsy showed a hypercellular marrow with increased granulo- and megakaryopoiesis, a slight plasmocytosis, but no sign of lymphoma. Cells were positive for CD20 in 10%, negative for CD30, and positive for CD3 in 3% by immunohistochemistry. Bronchoscopy, bronchial lavage and pleural fluid analyses were negative.

The patient was transferred to the department of Surgery for explorative minilaparotomy the second day after admission. This revealed an unclear retroperitoneal process with enlarged lymph nodes of up to 3 cm diameter. Lymph node histology showed a moderate inflammation and sinus histiocytosis. Peritoneal biopsy showed proliferation of mesothelial cells, fibrin deposits, calcifications and giant cell reaction. There was no sign of malignancy or granulomatous inflammation reaction. On the first post-operative day the general condition of the patient rapidly deteriorated with dyspnea, somnolence and tachycardia. She was transferred to the ICU (intensive care unit) and an

intravenous therapy with ciprofloxacin and methylprednisolone was started. Initial ANA-titer was 1:10240 and anti-dsDNA-titer > 2000 U/ml (Table I). Together with a proteinuria of 0.75 g/l, five of the eleven criteria for the diagnosis of SLE were fulfilled. This was consistent with a reduced level of C3 and C4 complement. A pericardial effusion (600 ml) had to be drained and antimicrobial treatment was extended with piperacillin, beta-lactamase inhibitor, and difluconazole. Low-dose low molecular weight heparin was also started. The patient reported pain in her knee, finger, and elbow joints. During the afternoon of the same day she developed several grand mal seizures requiring sedation, intubation and mechanical ventilation. Valproic acid and diazepam were started. In addition, 800 mg cyclophosphamide was administered i.v. because neurologic manifestation of SLE was suspected. CT scan and MRI of the brain were unremarkable (Fig. 1A).

Two days later the patient could be extubated. A skin biopsy showed superficial and deep perivascular dermatitis with linear deposits of IgA and IgM at the basal membrane including several blood vessels. Based on these findings SLE vasculitis was considered very likely. A control CT scan of the thorax depicted a regression of the pulmonary infiltrate and the pleural effusion. Anticardiolipin antibodies were 35 GPL/ml for IgG (normal < 12) and 7.3 MPL/ml for IgM (normal < 6) with a negative lupus anticoagulant (Table I). The next day, the patient developed anisocoria and Cheyne Stokes breathing pattern. Because of retention of secretion, reintubation was required. Cerebrospinal fluid (CSF) analysis was normal, but a repeat CT scan revealed a left-sided cerebral mass bleeding (Fig. 1B). A craniotomy was carried out, with removal of hematoma and insertion of an intracranial pressure (ICP) probe. Antifibrinolytic treatment was started due to DIC-associated wound bleeding. Flow cytometry for GMP-140 (p-selectin) expression showed reduced platelet activation after stimulation with ADP and TRAP-6. Microbiological investigation of tracheal secretion revealed enterococcus faecium, which was managed accordingly. Thirteen days after the operation, the patient could be weaned off the

Table I: Antibody screening during the course of disease.

Antibodies	Date (2002)				
	April	May	June	September	November
ANA	1:10240	1:1280	1:320	1:1280	1:640
Anti-dsDNA (IU/ml)	12100	5175	109	negative	negative
Anticardiolipin (IgG/IgM)	positive	negative	negative		
Lupus Anticoagulant	negative		negative		negative
Anti-Ro (SSA)	positive	positive	positive	negative	positive
Anti-La (SSB)	positive	negative	negative	negative	negative
Anti-RNP	positive	positive	positive	negative	negative
Anti-Sm (IU/ml)	760	433	169	negative	negative
Anti-Jo-1	negative	negative	negative	negative	
Anti-Scl-70	negative	negative	negative	negative	
Anticentromere	borderline	negative	positive	negative	
Antihistone		positive	negative	negative	negative
Antinucleosome		positive			
c-ANCA		negative			negative
x-ANCA		negative			negative
p-ANCA		negative			negative
Anti- β -2-glycoprotein I					negative

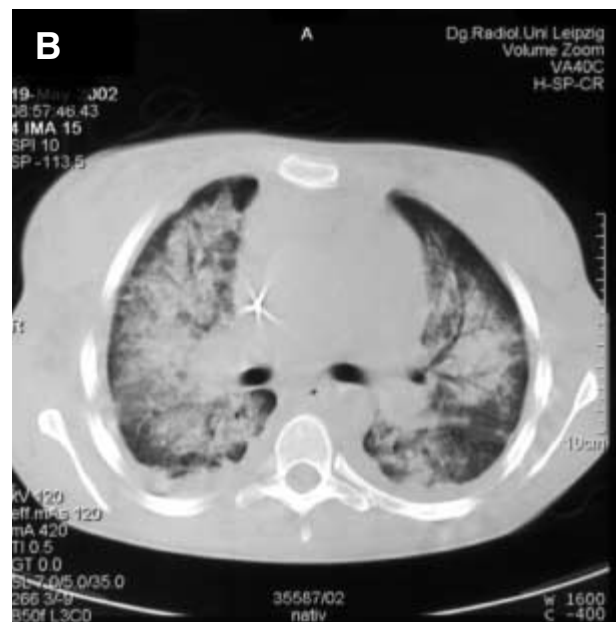
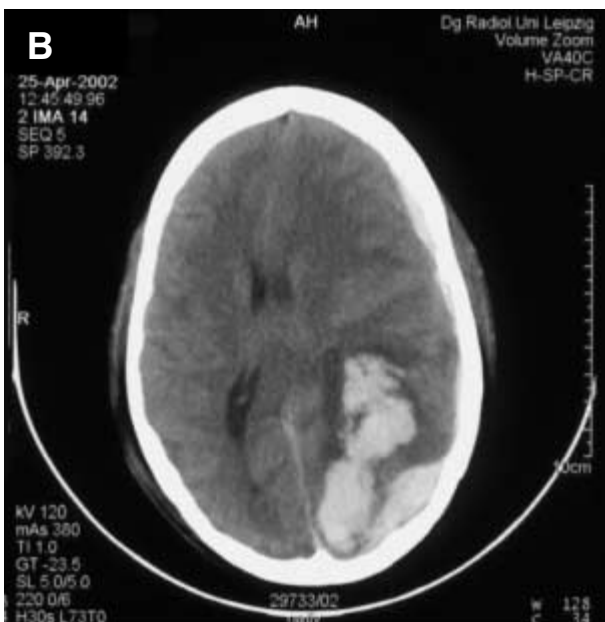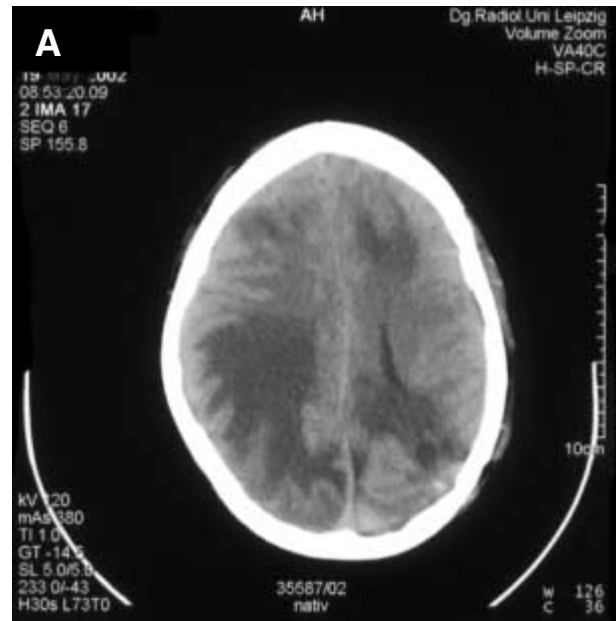
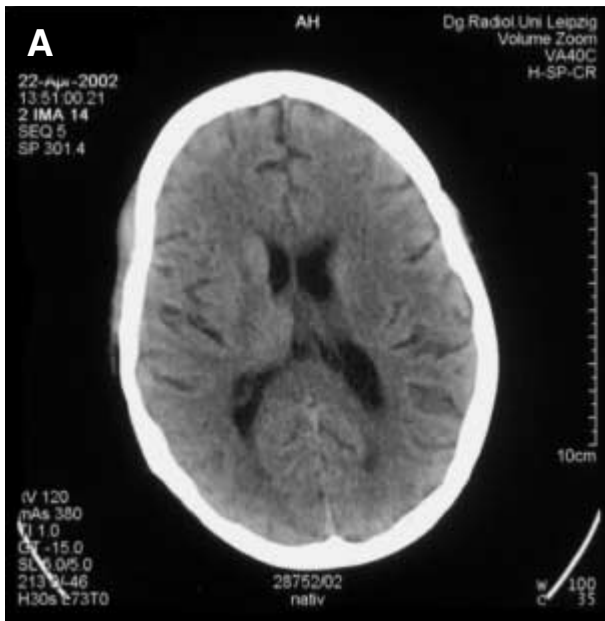


Fig. 1: CT scans of the brain. On the third day after admission to ICU the patient developed several grand mal seizures, but CT of the brain was unremarkable (A). Three days later a repeat scan revealed a left-sided parieto-occipital cerebral mass bleeding (B).

Fig. 2: CT scans of the brain and thorax 24 days after the initial operation or 4 days after wound revision, respectively. New hypodense bilateral frontal and parieto-occipital lesions appeared causing a shift of the middle line to the left (A). Massive confluent interstitial infiltrations of both lungs excluding the periphery (B).

ventilator and steroids were tapered off. A repeat skin biopsy proved SLE vasculitis. A right sided incomplete paresis, sensoric and motoric aphasia, and blurred vision, with the visual field limited to the left side, persisted.

On the 20th postoperative day, surgical wound revision was required due to a subgaleal liquor deposit. The next day, the patient became unconscious, combined with another grand mal seizure, with the need for reintubation and mechanical ventilation. A CT scan of the brain revealed new hypodense bilateral frontal and parieto-occipital lesions (Fig. 2A). Massive confluent interstitial infiltrations of both lungs excluding the periphery were detected on CT scan of the lungs (Fig. 2B). This was interpreted as a progressive SLE, so that plasmapheresis (3×) and intravenous pulse cyclophosphamide (IVCYC) in combination with

corticosteroids were initiated and an ICP probe reinserted. The patient could be weaned off the respirator two days later, but a new minor right frontal cerebral bleeding (2.7×2.7 cm) was detected (Fig. 3B). Because it was not progressive, no further neurosurgical intervention was deemed necessary. A new subgaleal liquor deposit was also drained the same day. Another two days later, ICP probe could be removed and the liquor fistula was treated by lumbar liquor drainage for a total of seven days (Fig. 3A). The patient was then transferred to a general ward where phenprocoumon therapy was initiated and continued until antiphospholipid and catastrophic antiphospholipid syndromes were ruled out. She stayed there for another five weeks receiving two more cycles of IVCYC (intravenous pulse cyclophosphamide).

A dura plastic and reimplantation of the skull bone were carried out. Ventriculo-peritoneal (vp)-shunt had to be installed due to a hydrocephalus malresorptivus. Because of recurrent epileptic attacks, valproic acid dose was increased and phenytoin added to the regimen. The patient's further recovery was slow and incomplete, complicated by an intraperitoneal vp-shunt cyst (15.6×7.9 cm), which was initially treated conservatively, but finally had to be revised operatively in October 2003. Cachexia and amaurosis persisted. The patient was put on a regimen of IVCYC every month, and prednisolone dose was reduced to 5 mg per day.

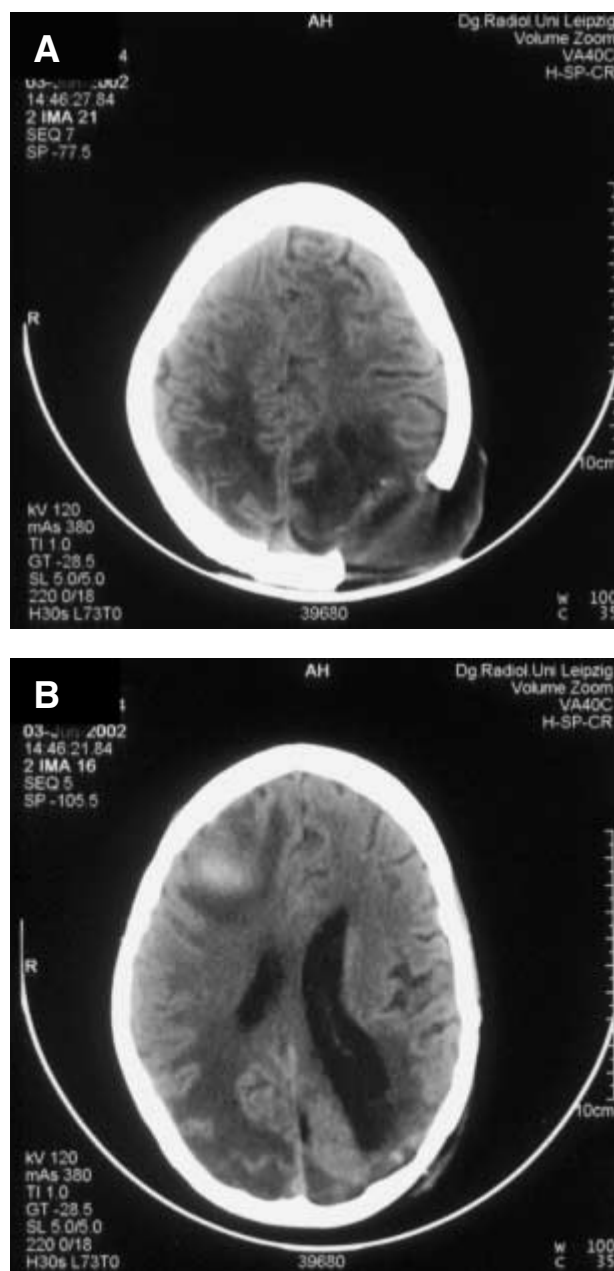


Fig 3: CT scans of the brain 39 days after the initial operation or 19 days after wound revision, respectively. Although a left occipital subgaleal liquor deposit was treated locally and drained for a total of seven days with a lumbar access, it was still present (A). Panel (B) depicts the remnants of a minor right frontal cerebral bleeding (2.7×2.7 cm) which had first occurred 6 days after wound revision.

Discussion

A 1999 consensus document has defined the neurological and psychiatric manifestations of SLE [1], which include a plethora of syndromes. Our patient suffered grand mal seizures and intracerebral bleeding. Seizures of any type occur in about 20% of patients during the course of disease. Focal brain infarctions and intracerebral bleeding are less frequent manifestations. The left parieto-occipital infarction that had occurred in our patient, followed by DIC-associated wound bleeding after craniotomy, was first interpreted as part of a catastrophic antiphospholipid syndrome. Although anticardiolipin antibodies were initially positive, control evaluations were negative (Table I), so that the criterion for the diagnosis of antiphospholipid syndrome was not fulfilled [11]. Lupus anticoagulant was always negative. In addition, a test for β -2-glycoprotein I antibodies (Table I), which are currently not included in the laboratory criteria for antiphospholipid syndrome, was also negative. As a differential diagnosis, lupus vasculitis is described in up to 56% of patients with SLE [6]. In our patient, skin biopsies were indicative of this manifestation. However, there was no definite proof for the involvement of the intracerebral blood vessels. Smith et al. described two patients who developed a fatal neurological involvement with perivascular hemorrhages in one case [15]. Brain stem infarction [17] as well as cerebral infarction and hemorrhage [9] are also reported in the literature.

Only ten randomised controlled trials on the treatment of complicated SLE have been published during the last 5 years, most of which included small numbers of patients [14]. The treatment of cerebral lupus is empiric due to a lack of randomized studies. High doses of glucocorticoids are rated beneficial for severely disabling manifestations of SLE. Cyclophosphamide in combination with glucocorticoids is probably beneficial in controlling the active disease, reducing the rate of recurrences and steroid requirements [7]. Intravenous pulse doses (10 to 15 mg/kg) once every 4 weeks have less urinary bladder toxicity than daily doses. In addition, although not proven, plasmapheresis might be beneficial in patients with acute life-threatening disease, for which high-dose immunosuppressive therapy may not be possible, or as an adjunct in patients not responding to conventional therapy [12]. Rather than the unselective removal of plasma, adsorption procedures allow the selective or specific removal of immunoglobulins, which seems to be a more reasonable approach especially in lupus nephritis. Plasmapheresis was used in our patient since her condition worsened dramatically 21 days after the initial neurosurgical operation. This was interpreted as progressive SLE and a more intense treatment regimen was considered necessary. Mycophenolate mofetil may be a promising alternative in patients who do not respond to high doses of cyclophosphamide or azathioprine [5]. Immunoablative therapy with and without autologous marrow stem-cell transplantation and some recently developed monoclonal antibodies such as anti-CD40L, anti-CD154 or anti-IL-10, or other molecules such as LJP394 may prove useful in the near future [8, 14]. Anticoagulation is mandatory for prevention of thrombotic complications. Several authors recommend oral anticoagulation with a tar-

get international normalized ratio (INR) of 3–3.5, especially if antiphospholipid syndrome is suspected.

In addition, infections are the leading cause of morbidity and mortality in patients with SLE. Meticulous exclusion of infection is mandatory, because this may masquerade as exacerbation of the underlying disease. In such a case, immunosuppressive treatment can have catastrophic consequences.

In summary, SLE causes significant morbidity and mortality by multisystem organ involvement and neurological and psychiatric manifestations have always to be considered.

References

- 1 The American College of Rheumatology nomenclature and case definitions for neuropsychiatric lupus syndromes. *Arthritis Rheum* 1999; 42: 599–608.
- 2 Alarcon-Segovia D, Perez-Vazquez ME, Villa AR, Drenkard C, Cabiedes J. Preliminary classification criteria for the antiphospholipid syndrome within systemic lupus erythematosus. *Semin Arthritis Rheum* 1992; 21: 275–86.
- 3 Asherson RA, Cervera R, Piette JC, Font J, Lie JT, Burcoglu A, Lim K, Munoz-Rodriguez FJ, Levy RA, Boue F, Rossert J, Ingelmo M. Catastrophic antiphospholipid syndrome. Clinical and laboratory features of 50 patients. *Medicine (Baltimore)* 1998; 77: 195–207.
- 4 Asherson RA, Khamashta MA, Ordi-Ros J, Derksen RH, Machin SJ, Barquinero J, Outt HH, Harris EN, Vilardell-Torres M, Hughes GR. The “primary” antiphospholipid syndrome: major clinical and serological features. *Medicine (Baltimore)* 1989; 68: 366–74.
- 5 Chan TM, Li FK, Tang CS, Wong RW, Fang GX, Ji YL, Lau CS, Wong AK, Tong MK, Chan KW, Lai KN. Efficacy of mycophenolate mofetil in patients with diffuse proliferative lupus nephritis. Hong Kong-Guangzhou Nephrology Study Group. *N Engl J Med* 2000; 343: 1156–62.
- 6 Golan TD. Lupus vasculitis: differential diagnosis with antiphospholipid syndrome. *Curr Rheumatol Rep* 2002; 4: 18–24.
- 7 Gourley MF, Austin HA, 3RD, Scott D, Yarboro CH, Vaughan EM, Muir J, Boumpas DT, Klippel JH, Balow JE, Steinberg AD. Methylprednisolone and cyclophosphamide, alone or in combination, in patients with lupus nephritis. A randomized, controlled trial. *Ann Intern Med* 1996; 125: 549–57.
- 8 Grammer AC, Slota R, Fischer R, Gur H, Girschick H, Yarboro C, Illei GG, Lipsky PE. Abnormal germinal center reactions in systemic lupus erythematosus demonstrated by blockade of CD154-CD40 interactions. *J Clin Invest* 2003; 112: 1506–20.
- 9 Hirano A, Miyazaki S, Hashimoto Y, Hashi K. [A case of systemic lupus erythematosus associated with cerebral infarction and cerebral hemorrhage]. *No To Shinkei* 1995; 47 (10): 1003–7.
- 10 Hochberg MC. Systemic lupus erythematosus. *Rheum Dis Clin North Am* 1990; 16: 617–39.
- 11 Levine JS, Branch DW, Rauch J. The antiphospholipid syndrome. *N Engl J Med* 2002; 346: 752–63.
- 12 Mistry-Burchard N, Schonermarck U, Samtleben W. Apheresis in lupus nephritis. *Ther Apher* 2001; 5: 161–70.
- 13 Petri M. Epidemiology of the antiphospholipid antibody syndrome. *J Autoimmun* 2000; 15: 145–51.
- 14 Ruiz-Irastorza G, Khamashta MA, Castellino G, Hughes GR. Systemic lupus erythematosus. *Lancet* 2001; 357: 1027–32.
- 15 Smith RW, Ellison DW, Jenkins EA, Fallagher PJ, Cawley MI. Cerebellum and brainstem vasculopathy in systemic lupus erythematosus: two clinico-pathological cases. *Ann Rheum Dis* 1994; 53: 327–30.
- 16 Uramoto KM, Michet CJ, JR., Thumboo J, Sunku J, O’Fallon WM, Gabriel SE. Trends in the incidence and mortality of systemic lupus erythematosus, 1950–1992. *Arthritis Rheum* 1999; 42: 46–50.
- 17 Ushida H, Koizumi S, Katoh K, Okada Y. [Systemic lupus erythematosus presenting as a brainstem infarction and hemorrhage during treating retroperitoneal abscess: a case report]. *Nippon Hinyokika Gakkai Zasshi* 2001; 92: 579–82.
- 18 Vianna JL, Khamashta MA, Ordi-Ros J, Font J, Cervera R, Lopez-Soto A, Tolosa C, Franz J, Selva A, Ingelmo M, et al. Comparison of the primary and secondary antiphospholipid syndrome: a European Multicenter Study of 114 patients. *Am J Med* 1994; 96: 3–9.
- 19 Weiner DK, Allen NB. Large vessel vasculitis of the central nervous system in systemic lupus erythematosus: report and review of the literature. *J Rheumatol* 1991; 18: 748–51.

Marcus Wiedmann, M.D., Department of Internal Medicine II, University of Leipzig, Philipp-Rosenthal-Str. 27, 04103 Leipzig, Germany
E-mail: wiedm@medizin.uni-leipzig.de