



Case report

Chorea and Broca aphasia induced by diabetic ketoacidosis in a type 1 diabetic patient diagnosed as Moyamoya disease

Chizuru Watanabe^a, Tetsuya Oishi^a, Tunekiko Yamamoto^b, Kaori Sasaki^a, Maki Tosaka^a, Tosihiko Sato^b, Hiroko Kobayashi^a, Shinichiro Takayama^a, Asako Sato^a, Makoto Iwata^c, Yasuko Uchigata^{a,*}, Yasuhiko Iwamoto^a

^a Diabetes Center, Tokyo Woman's Medical University, School of Medicine, 1-8 Kawada-cho, Shinjuku-ku, Tokyo 162-8666, Japan

^b Department of Internal Medicine, Osaka City General Hospital, Osaka, Japan

^c Department of Neurology, Tokyo Women's Medical University School of Medicine, Tokyo, Japan
; received in revised form 12 April 2004; accepted 27 April 2004

Abstract

We here report one case of hemichorea and Broca aphasia occurred with diabetic ketoacidosis. A 20-year-old woman with type 1 diabetes mellitus had experienced diabetic ketoacidosis fourth time after the onset of diabetes. At the third ketoacidotic episode, the patient was admitted to our hospital for the first time to show hemichorea of the left extremities. Brain computed tomography (CT) demonstrated a high-density area in the right caudate head and low-density area in the right putamen. Magnetic resonance angiography (MRA) demonstrated a stenosis at the root of the bilateral middle and anterior cerebral arteries. The hemichorea disappeared within 3 days. At the fourth ketoacidotic episode, not hemichorea but unconsciousness was there for 2 days even after ketoacidosis disappeared. After the unconscious state, Broca aphasia was demonstrated for 15 days. The cerebral angiography showed a finding compatible to Moyamoya disease. These findings support that chorea and Broca aphasia induced by diabetic ketoacidosis was developed in addition to blood vessel abnormalities such as Moyamoya disease. We suggest that poorly controlled diabetic patients with hemichorea should undergo cerebral angiography.
© 2004 Elsevier Ireland Ltd. All rights reserved.

Keywords: Chorea; Broca aphasia; Diabetic ketoacidosis (DKA); Moyamoya disease

1. Introduction

Chorea is generally known to be caused by hereditary degenerative diseases, cerebrovascular disorders, and infections in the central nervous system, but

sometime caused by drugs, metabolic abnormalities, autoimmune disorders, and tumors in the central nervous system [1]. It is also known that poorly controlled diabetes mellitus at the aged people, which is a representative of metabolic abnormalities, can cause chorea or choreatic movement [2–8,10–12], most of which were reported to be reversible.

On the other hand, Broca aphasia is generally caused by cerebral infarction or space occupying le-

* Corresponding author. Tel.: +81-3-3353-8111;

fax: +81-3-3358-1941.

E-mail address: uchigata@dmc.twmu.ac.jp (Y. Uchigata).

sion of the cerebral hemisphere, but is supposed to be caused by metabolic abnormalities resulting from severe dehydration.

Here, we report a case of type 1 diabetic patient with reversible hemichorea and then Broca aphasia induced with hyperglycemia, resulting from Moyamoya disease.

2. Presentation of case

On 21 June 1999, a 20-year-old woman was admitted to our diabetes center because of coma induced by diabetic ketoacidosis (DKA) and hemichorea in her left extremities. She had developed type 1 diabetes mellitus at the age of 18 years, and started four-time insulin injection therapy. The diabetic control had kept being poor (HbA_{1c} around 11–12%), and she had developed diabetic ketoacidosis twice before the admission to our diabetes center. At those times, she had no neurological symptoms including involuntary movement.

Two weeks before the admission, she found a chorea-like movement on the left extremities and could not inject insulin to her left thigh by herself correctly. She stopped insulin injections the day before the admission. She first admitted to our diabetes center because of diabetic coma, which is the third diabetic ketoacidotic episode of her.

On admission, the respiration was 40/min with Kussmaul type. Her blood pressure was 130/70 mm Hg, the pulse was 146/min and regular, and the body temperature was 36.6 °C. She weighed 64.4 kg, and was 155 cm tall. Neurological examination revealed left hemichorea and left Babinski sign. No other neurological remarks were noted.

The following laboratory data were notable; random blood glucose, 46.8 mmol/l, 3-hydroxybutyrate, 9270 μmol/l, glycosylated hemoglobin (HbA_{1c}), 12.7%, and serum osmolarity, 1127 mOsm/kg. Blood gas analysis showed pH 6.923, which showed metabolic acidosis. In immunological findings, protein C, protein S, and anti-Cardiolipin β 2 GP1 antibody were all negative. Brain computed tomography (CT) scan on the first hospital day showed a high-density area in the right caudate head and low-density area in the right putamen (Fig. 1).

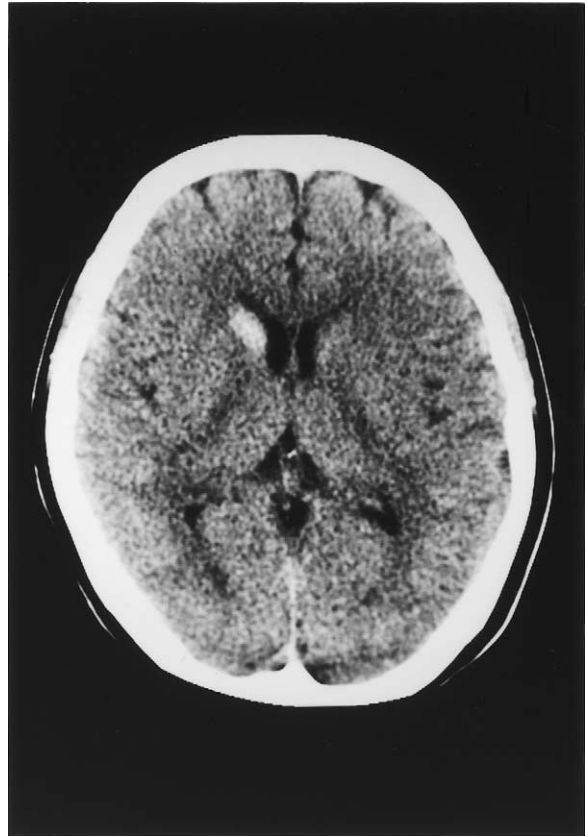


Fig. 1. Brain computed tomography scan on the first hospital day. A high-density area in the right caudate head and a low-density area in the right putamen are shown.

The extensive and urgent treatment for diabetic ketoacidosis was performed. The second hospital day, her mental status was gradually improved to be alert. The third day, metabolic acidosis almost disappeared, blood glucose remained under 11.5 mmol/l, and hemichorea disappeared completely.

Magnetic resonance imaging (MRI) was performed on the sixth day (Fig. 2). High-intensity and ring-shaped areas in the right caudate head and body and the putamen were shown on T2-weighted images and high- and low-intensity areas in the same regions were shown on T1-weighted images. We diagnosed that these brain CT and MRI images indicated hemorrhagic cerebral infarctions in the area. Enhanced MRI performed on the 15th hospital day showed that the right caudate and the putamen had an enhanced high-intensity ring-shaped area on T2-weighted im-

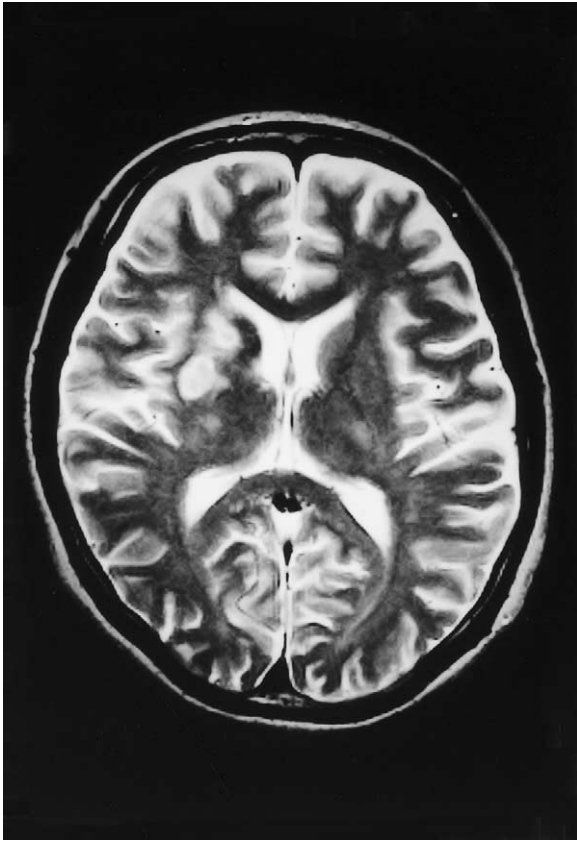

Fig. 2. T2-weighted magnetic resonance imaging on the sixth day. High-density and ring-shaped areas in the right caudate head and body and the putamen are shown.

ages, which seemed to change to slightly low-density areas. We thought that the severe dehydration caused by diabetic ketoacidosis induced ischemic brain infarction and the recovery modification from the dehydration induced hemorrhagic brain infarction at the right striatum. Magnetic resonance (MR) angiography was performed on the 19th hospital day. It showed a stenosis at the root of the bilateral middle and anterior cerebral arteries, but did not show a finding which supported a diagnosis of Moyamoya disease. Carotid artery echography and transesophageal echocardiography were performed on the 26th hospital day to clarify whether or not the hemorrhagic cerebral infarctions were induced by a thrombus and embolus. However, there were no remarkable findings. We did not support positively the anti-phospholipid antibody

syndrome, Moyamoya disease, or aortitis syndrome at that time.

Nine months after discharge, the brain CT scan was performed again at outpatient clinic at our diabetes center; the high-density area in the right caudate head on the admission had disappeared completely (Fig. 3). The metabolic control remained to be around 11% of HbA_{1c} level because of binge eating disorder.

One year later, she was re-hospitalized because of the treatment of diabetic ketoacidosis induced by excessive drinking, which supposed to contain about 60 g of ethanol, and insulin omission. At this time, there was no hemichorea. However, unconsciousness was remained for 2 days after ketoacidosis disappeared. After the unconscious state, Broca aphasia was demonstrated for 15 days. Brain CT on this admission showed old cerebrovascular lesions. There

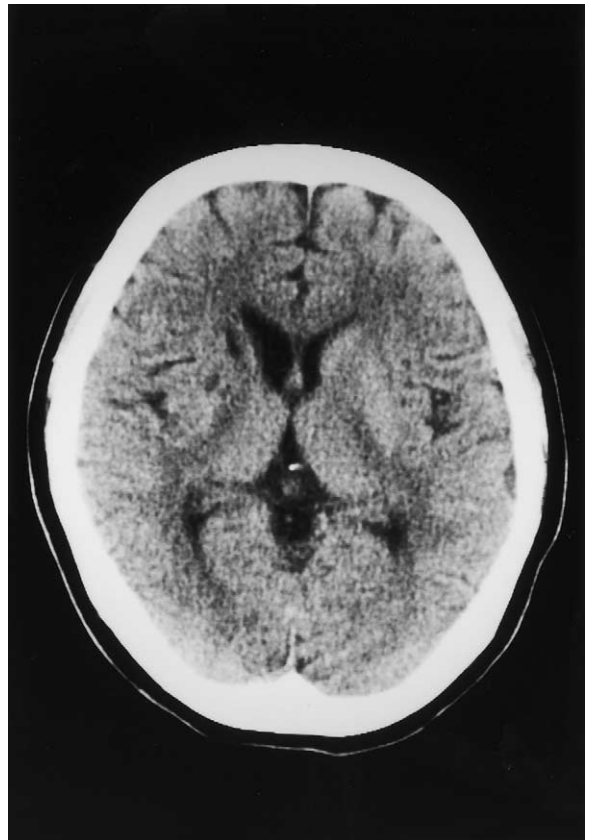

Fig. 3. Brain CT scan 9 months after discharge. The high-density area in the right caudate head on the admission had disappeared.

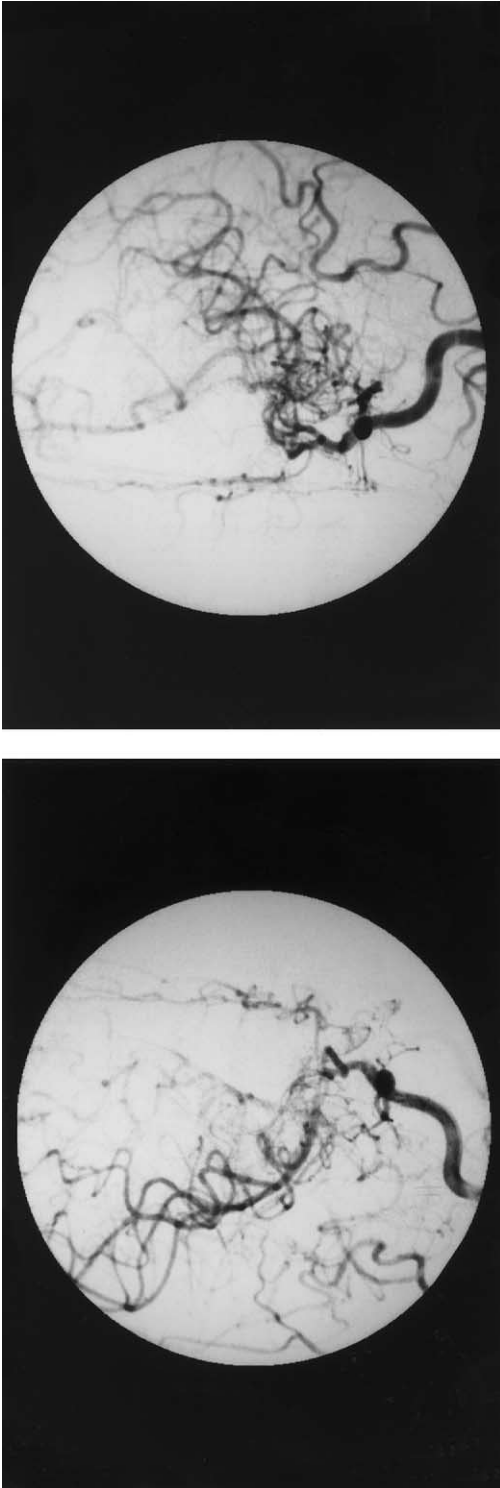

Fig. 4. Cerebral angiogram on the 20th hospital day at Osaka City General Hospital.

were no findings compatible to new hemorrhagic cerebral infarctions at the basal ganglia.

Although a high-intensity area was demonstrated at the bilateral frontal deep white matter to centrum semiovale on T2-weighted, flair, and diffusion weighted images (MRI), we thought that the area was caused by newly ischemic change or demyelination induced by diabetic ketoacidosis and dehydration on this episode. These findings were compatible with the diagnosis of Broca aphasia. Immunological findings of anti-cardiolipin antibody-IgG was 2.0 (normal range <1.0) and anti-cardiolipin antibody-IgM was <0.5 (normal range <1.0) did not strongly support Moyamoya disease. We considered to perform cerebral angiography for further examination, but could not proceed because of her condition.

One month later, she was transferred to Osaka City General Hospital which was near from her hometown for the continuous treatment of Broca aphasia. Lupus anticoagulant and anti-cardiolipin antibody-IgG were found to be positive in serum. Under the stable diabetic condition, cerebral angiography was performed on the 20th hospital day (Fig. 4). Moyamoya disease was diagnosed. Two months later, she was discharged from the hospital on condition that she would be readmitted to this hospital for superficial temporal artery-middle cerebral artery (STA-MCA) anastomosis.

3. Discussion

The 20-year-old woman had been diagnosed with type 1 diabetes mellitus 2 years before, and then the diabetic control had been poor, and she had developed diabetic ketoacidosis (DKA) four times during 2 years after the onset of diabetes. She did not have any neurological sign on the first and second DKA episode, although, she had hemichorea on the third DKA episode and Broca aphasia on the fourth DKA episode.

As Brain CT scan showed multiple cerebral infarctions at the third DKA by which she was admitted to our diabetes center for the first time, we needed to rule out congenital heart diseases, coagulation disorders and autonomic immunological disease as the causes of cerebral infarction in the young ages. Carotid artery echography and transesophageal echocardiography and anti-cardiolipin β 2 GPI antibody were all negative. We did not check out lupus anticoagu-

lant at this time. We considered to perform cerebral angiography for further examination, but could not proceed because of her serious condition and which we did not positively support the anti-phospholipid antibody syndrome, Moyamoya disease, or aortitis syndrome at that time. At the hospital transferred under the stable condition, Lupus anticoagulant and anti-cardiolipin antibody-IgG were found to be positive in serum. Cerebral angiography was performed, and then Moyamoya disease was diagnosed.

We guess that it could not explain as simple symptom of hemorrhagic cerebral infarctions for chorea. Probably, it was not occurred by only one cause, it was a matter of importance which metabolic disorder was overlap ischemic change in basal ganglia.

At third admission, in spite of being in existence hemorrhagic cerebral infarctions, hemichorea was disappeared after medication of DKA. This result was suggested relation of metabolic disorder not only ischemic change.

And hemichorea was not occurred at fourth admission for DKA, although there were new cerebrovascular damages, however, no new lesion in basal ganglia. For these reasons, we could not explain only metabolic disorder; it was a matter of importance which ischemic change was overlap metabolic disorder in basal ganglia.

The cases of diabetes mellitus with chorea were reported by Budwell [2] in 1960. After this report, several cases were observed [3–5]. The characteristic on CT and MRI in those reports was the presence of unusual homogeneous high-density or intensity area in the one-sided basal ganglia. The several causes were discussed; the relatively depletion of γ -aminobutylic acid (GABA) because of the increased utilization of GABA as the brain's energy source in hyperglycemic patients [6,7], the increased activity of dopaminergic neuron resulting in the development of chorea because of the activity over the threshold [8]. Others reported bleedings, hemorrhagic infarcts, cerebral infarcts, and demyelinations [9,13] for the cause of chorea. Nakamura et al. [14] carried out a brain biopsy at lentiform nuclei enhanced high-intensity on T1-weighted; and the specimen obtained from the putamen showed astrocytosis and vacuolization without deposition of hemosiderin. Iwata et al. [12] reported a case of diabetic hemichorea that showed enhancement in the globus pallidus with gadopentetate dimeglumine

(Gd-DTPA) on T1-weighted MRI. They suggested that diapedesis [12] was due to blood brain barrier destruction resulting from the hyperosmotic state caused by hyperglycemia. Taking together, hyperosmotic disturbance or disturbance of neuron activities in the brain induced by diabetic ketoacidosis may cause reversible chorea in case of no abnormalities of cerebral arteries.

Etiology of antiphospholipid antibody syndrome (APS) are basically thrombosis and vasculitis et al. There is another theory that a reaction of antigen-antibody by APS induce injuries especially for basal ganglia cells resulting in occurring chorea [15].

We have to discuss why she showed no neurological findings on first and second DKA episodes.

It is difficult to make clear whether Moyamoya arteries was congenital or acquired ones. We think so far that was developed by acquired vascular formation, because no symptoms of Moyamoya.

We suggest that at first and second DKA, stenosis by thrombus at the bilateral middle and anterior cerebral arteries by the anticardiolipin syndrome might be incomplete, therefore, she did not take chorea. At the fourth DKA, the thrombus may have grown more seriously, and have induced Moyamoya artery formation as collateral root in the globus pallidus. It is suggested that as the development of collateral root was immature for grade of stenosis at the third DKA, the compensation of circulation and metabolism under hyperglycemia showed reversible hemichorea. Hyperosmotic disturbance or disturbance of neuron activities in the brain induced by diabetic ketoacidosis have an additive effect against such vascular disturbances. We could not find Moyamoya disease even in the third admission, was diagnosed by angiography in other hospital, we think that Moyamoya arteries were developed gradually, and therefore we could not obviously find them by MRI and MRA in our hospital. It is supposed that co-lateral arteries were more growing after hemorrhagic cerebral infarctions.

Another interesting point is that this case was being monitored as autoimmune disease, because the etiologies of type 1 diabetes mellitus, and Moyamoya disease were somehow related with autoimmunity.

Although patients with type 1 diabetes are sometimes associated with autoimmune diseases, there are

few reports according to them associated with chorea. It is difficult to explain chorea development by autoimmune disorders. Actually, the patient in this report had not developed even collagen diseases.

We have to pay further attention to cerebral artery abnormalities induced by autoimmune disorders in choreic patients with type 1 diabetes mellitus.

References

- [1] P.G. Wheeler, et al., Benign hereditary chorea, *Pediatric Neurol.* 9 (1993) 337–340.
- [2] S.F. Budwell, Some observations on hemiballismus, *Neurology* 10 (1960) 619–622.
- [3] W.G. Rector Jr., H.F. Herlong, Nonketotic hyperglycemia appearing as choreoathetosis or ballism, *Arch. Intern. Med.* 142 (1982) 154–155.
- [4] J.J. Lin, M.K. Chang, Hemiballism-hemichorea and non-ketotic hyperglycemia, *J. Neurol. Neurosurg. Psych.* 57 (1994) 748–750.
- [5] J.A. Sanfield, J. Finkel, S. Lewis, S.G. Rosen, Alternating choreoathetosis associated with uncontrolled diabetes mellitus and basal ganglia calcification, *Diab. Care* 9 (1986) 100–101.
- [6] M. Shirasu, S. Aoki, H. Ohba, C. Araki, Z. Shiozawa, *Nichijiishi* 17 (1997) 105–109.
- [7] R. Guisado, A.I. Arieff, Neurologic manifestation of diabetic comas: correlation with biochemical alteration in the brain, *Metabolism* 24 (1975) 655–679.
- [8] H. Nabatame, K. Nakamura, M. Matuda, Hemichorea in hyperglycemia associated with increased blood flow in the contralateral striatum and thalamus, *Internal Med.* 33 (1994) 472–475.
- [9] G.M. De Courten-Myers, M. Kleinholz, P. Holm, G. Schmitt, K.R. Wagner, R.E. Myers, Hemorrhagic infarct conversion in experimental stroke, *Ann. Emerg. Med.* 21 (1992) 120–125.
- [10] P.H. Lai, R.D. Tein, M.H. Chang, M.M.H. Teng, C.F. Yang, H.B. Pan, C. Chen, J.F. Lirng, K.W. Kong, Choreo-ballismus with nonketotic hyperglycemia in primary diabetes mellitus, *AJNR* 17 (1996) 1057–1064.
- [11] J.P. Broderick, T. Hagen, T. Brott, T. Tomsick, Hyperglycemia and hemorrhagic transformation of cerebral infarcts, *Stroke* 26 (1995) 484–487.
- [12] A. Iwata, F. Koike, K. Arasaki, M. Tamaki, Blood brain barrier destruction in hyperglycemic chorea in a patient with poorly controlled diabetes, *J. Neurol. Sci.* 163 (1999) 90–93.
- [13] M.H. Chang, H.T. Chiang, P.H. Lai, et al., Putaminal petechial hemorrhage as the cause of chorea: a neuroimaging study, *J. Neurol. Neurosurg. Psych.* 63 (1997) 300–303.
- [14] K. Nakamura, T. Akamine, S. Makihara, N. Asami, Y. Yamakawa, Hemiballism presenting with high intensity at lentiform nuclei on short spin echo of serial MRI, *Neurol. Med. (Tokyo)* 36 (1992) 203.
- [15] R.A. Asherson, G.R.V. Hughes, Antiphospholipid antibodies and chorea, *J. Rheumatol.* 15 (1988) 377–379.