

- 3 Duthie SJ, Whalley LJ, Collins AR, *et al.* Homocysteine, B vitamin status and cognitive function in older adults. *Am J Clin Nutr* 2002;**75**:908–13.
- 4 Deary IJ, Whiteman MC, Starr JM, *et al.* The impact of childhood intelligence in later life: following up the Scottish Mental Surveys of 1932 and 1947. *J Pers Soc Psychol* 2004;**86**:130–47.
- 5 Clarke R, Grimley Evans J, Schneede J, *et al.* Vitamin B12 and folate deficiency in later life. *Age Ageing* 2004;**33**:34–41.

Stent assisted endovascular thrombolysis of internal carotid artery dissection

Spontaneous dissection of the extracranial internal carotid artery (ICA) is a major cause of stroke with severe residual handicap in young adults.¹ Recently, stent supported angioplasty has been used to treat intimal dissection in case of neurological symptoms while on anticoagulation or as an alternative to the traditionally accepted use of anticoagulation.^{2,3} We report a case of internal carotid artery dissection causing hemiplegia successfully treated with emergent endovascular stenting followed by intra-arterial thrombolysis.

Case report

A 44 year old right handed man was admitted to the emergency room after an acute episode of left side weakness, which resolved within three hours. The patient had been well until the onset of symptoms. There was no history of trauma, strenuous exercise, hypertension, or other medical problems. In the week prior to admission, he reported intermittent headaches and right sided neck pain after four days of diving. A cranial computed tomography (CT) scan was normal. Diffusion weighted imaging (DWI) of the brain performed six hours after the onset of symptoms while the patient was asymptomatic showed no evidence of infarction. T2-weighted magnetic resonance images and fat suppressed images showed a semilunar hypersignal of a mural haematoma in the infrapetrous segment of the right ICA suggestive of a dissection. Low molecular weight heparin treatment (enoxaparin sodium 1 mg/kg subcutaneously every 12 hours) was started to obtain true anticoagulation.

Three hours later, the patient had sudden left sided hemiplegia, hypaesthesia, hemianopia, and hemineglect. The National Institutes of Health Stroke Scale (NIHSS) score was 12. Transcranial Doppler ultrasound did not show any flow signal from the middle cerebral artery (MCA) pointing to an acute occlusion. Because of the likely poor

chance of revascularisation with intravenous thrombolytic therapy, emergent endovascular revascularisation followed by intra-arterial thrombolysis was planned. Angiography (fig 1A) performed within three hours and 30 minutes of onset of the new symptoms showed the typical narrowed aspect of the ICA with no opacification of the intracranial arteries. Right hemispheric circulation was analysed on the left carotid angiogram: the right anterior cerebral artery (ACA) filled via anterior communicating artery, and the distal branches of the right MCA were filled via pial collaterals from the right ACA. The right M1 and A1 segments were completely occluded. Proximal ICA recanalisation was achieved by implantation of two tandem self-expandable stents (Carotid Wall stent, Boston Scientific Inc, Natick, MA), covering the suprabulbar cervical portion of the ICA (fig 1B). Subsequent intracranial angiography showed a fresh thrombus in the right carotid siphon and confirmed the occlusion of the MCA. Intra-arterial tissue plasminogen activator (tPA) was infused directly into the thrombus four hours after the onset of the new symptoms (40 mg total). There was good proximal recanalisation with residual filling defects in some branches of the MCA (fig 1C) and immediate clinical improvement. The patient received a 5000 U heparin bolus during the procedure and then continuous 500 U/h infusion for 24 hours. Heparin therapy was then replaced by clopidogrel and aspirin, both 75 mg daily. On day 2, MRI showed brain infarct in the deep MCA territories with asymptomatic haemorrhagic transformation. The carotid artery and the MCA were fully patent at ultrasound examination with no evidence of restenosis. There were no periprocedural complications and the patient's symptoms improved gradually after the procedure. On day 7, he was discharged on aspirin and clopidogrel with no residual symptoms.

Discussion

Ischaemic stroke in patients with ICA dissection mainly results from thromboembolic, or, less frequently, haemodynamic mechanisms.⁴ Formation of a false channel in the vessel wall or endothelial damage may favour formation of a local thrombus, which becomes less adherent and prone to embolise distally.¹ Although no general agreement exists on the best management of extracranial carotid artery dissection, and because of the threat of an embolic complication, anticoagulation with heparin followed by oral warfarin is used in most institutions.⁵ In case of an embolic complication in a patient with

known carotid artery dissection revealed by local signs or a transient ischaemic attack, as in our patient, no recommendation exists about emergent therapy. Some reports suggest that intravenous thrombolysis might be safe and effective when given within three hours of onset of stroke without worsening the arterial wall tearing.⁶ However, in case of severe stenosis, near occlusion, or even occlusion of the ICA, regardless of the cause, intravenous or intra-arterial thrombolysis has had a poor recanalisation rate, less than 15%.⁷

Endovascular stenting in patients with carotid artery dissection has been successfully used in either selected cases with haemodynamically significant stenosis or when anticoagulation failed to prevent embolic stroke.^{2,3} It permitted resolution of the stenosis with immediate recanalisation of the artery. After the procedure, there was no need for anticoagulation and the patient was treated with antiplatelet agents. Our patient had acute hemiplegia with MCA occlusion despite adequate medical therapy. Intravenous thrombolysis given within three hours of onset of symptoms might be an alternative treatment,⁸ but it would have likely not been effective since ICA near occlusion would have been left in place; systemic thrombolysis was contraindicated because of the anticoagulation therapy.

We chose a new approach combining endovascular stenting and intra-arterial thrombolysis. Mechanical reopening of occluded large vessels is currently being explored only in carefully selected cases of acute stroke management to minimise the risk of haemorrhagic complications. By taking advantage of the immediate recanalisation of completely occluded vessels it permits delivery of thrombolytic agents directly in the clot, maximising the chance of total distal recanalisation.

Although so far no clinical trial has documented the efficacy of emergent revascularisation in the setting of acute stroke, accumulated anecdotal data show that endovascular mechanical revascularisation is likely to become an important alternative therapeutic approach in properly selected stroke patients. A potential disadvantage of mechanical reopening is the production of embolic debris.⁹ With stent deploying in dissected carotid artery, there is a theoretical risk of the intramural clot contained within the dissected segment breaking into the cerebral circulation leading to embolisation distally. In our case, the MCA emboli were demonstrated prior to stenting using transcranial Doppler ultrasound. Another alternative to intra-arterial thrombolysis could be the use of mechanical thrombectomy devices to remove the clot from the carotid siphon and MCA.

This case report is to our knowledge the first example of the potential use of stenting followed by intra-arterial thrombolysis to treat and cure symptomatic carotid artery dissection. However, no conclusions can be drawn about the safety of endovascular approach in this clinical setting. Further evaluation is needed to address its risk–benefit ratio.

H Abboud

Department of Neurology and Stroke Center, Bichat University Hospital and Medical School, Denis Diderot University-Paris VII, France

E Houdart

The Department of Interventional Neuroradiology, Lariboisiere Hospital, Denis Diderot University-Paris VII, France

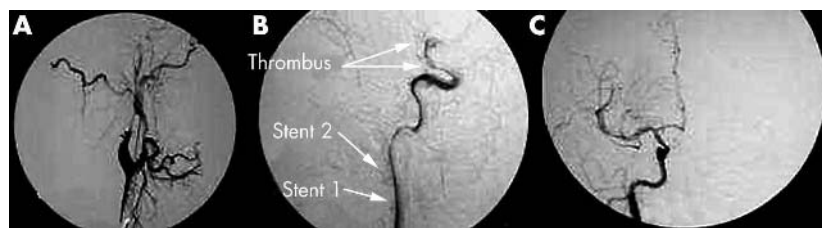


Figure 1 (A) Baseline right common carotid artery (CCA) angiogram shows near occlusion distal to the origin of the infrapetrous segment of the right internal carotid artery (ICA). (B) Post stenting right ICA angiogram demonstrates complete resolution of the ICA occlusion and shows the thrombus in the carotid siphon and in the MCA. (C) Right ICA angiogram after 40 mg of intra-arterial tissue plasminogen activator, recanalisation of the carotid siphon and of the M1 and M2 segment of the MCA and partial recanalisation of some branches of the MCA.

E Meseguer, P Amarenco

Department of Neurology and Stroke Center, Bichat University Hospital and Medical School, Denis Diderot University-Paris VII, France

Correspondence to: Halim Abboud, Department of Neurology and Stroke Center, Bichat Hospital, 46 rue Henri Huchard, F-75018 Paris, France; halim.abboud@bch.ap-hop-paris.fr

doi: 10.1136/jnnp.2004.041863

Competing interests: none declared

References

- 1 Schievink WI. Spontaneous dissection of the carotid and vertebral arteries. *N Engl J Med* 2001;**344**:898-906.
- 2 Malek AM, Higashida RT, Phatouros CC, et al. Endovascular management of extracranial carotid artery dissection achieved using stent angioplasty. *AJNR Am J Neuroradiol* 2000;**21**:1280-92.
- 3 Cohen JE, Leker RR, Gotkine M, et al. Emergent stenting to treat patients with carotid artery dissection: clinically and radiologically directed therapeutic decision making. *Stroke* 2003;**34**:e254-7.
- 4 Lucas C, Moulin T, Deplanque D, et al. Stroke patterns of internal carotid artery dissection in 40 patients. *Stroke* 1998;**29**:2646-8.
- 5 Lyrer P, Engelter S. Antithrombotic drugs for carotid artery dissection. *Stroke* 2004;**35**:613-14.
- 6 Derex L, Nighoghossian N, Turjman F, et al. Intravenous tPA in acute ischemic stroke related to internal carotid artery dissection. *Neurology* 2000;**54**:2159-61.
- 7 Arnold M, Schroth G, Nedeltchev K, et al. Intra-arterial thrombolysis in 100 patients with acute stroke due to middle cerebral artery occlusion. *Stroke* 2002;**33**:1828-33.
- 8 Tissue plasminogen activator for acute ischemic stroke. The National Institute of Neurological

Disorders and Stroke rt-PA Stroke Study Group. *N Engl J Med* 1995;**333**:1581-7.

- 9 Qureshi AI. Endovascular treatment of cerebrovascular diseases and intracranial neoplasms. *Lancet* 2004;**363**:804-13.

Bell's palsy: a study of the treatment advice given by Neurologists

Bell's palsy is defined as an isolated unilateral lower motor neurone facial weakness of no obvious cause. The incidence has been estimated at around 23 to 25 cases per 100 000 population annually.¹ Although the prognosis is generally good, around 16% are left with varying degrees of permanent disability.²

The use of steroids and acyclovir in the treatment of Bell's palsy has been addressed in two recent Cochrane reviews.^{3 4} These found no benefit from either but concluded that available studies were insufficiently powered to detect a treatment effect.

Neurologists are often asked by primary care physicians for treatment advice and in view of this uncertainty we were interested in studying the recommendations given. A questionnaire (appendix) was emailed to all consultant neurologists (n = 35) and specialist registrars (n = 21) in Scotland. Responses were collated at six weeks following an interim reminder. Fisher's exact test was used to compare groups; odds ratios with 95% confidence intervals and significance were calculated (table 1).

Replies were received from 27 consultants and 17 registrars, response rates of 77% and

81%, respectively. In all, there had been 69 requests received for treatment advice in the preceding three months. Referral for guidance from neurologists amounted to 26% of the total number of cases predicted by incidence studies.¹

Only 5% of neurologists said they would always see the patient, with further 29% if atypical features were present. The use of steroids depended strongly on the stage of presentation, 76% giving steroids within 24 hours of onset, 62% within three days, and only 28% up to seven days. Fewer gave steroids in certain subcategories (12% in pregnancy, 19% in Ramsay Hunt syndrome, 62% in a complete syndrome, and 45% in a partial syndrome).

The steroid regimen advised was variable, with most advocating 40 to 60 mg of prednisolone, with or without a tapering dose. Only 20% of neurologists gave acyclovir in every instance; a further 20% gave it if there was evidence of Ramsay Hunt syndrome.

On the whole the responses from consultants and registrars were similar. However, while both advised steroids early on, consultants still recommended steroids up to seven days (42%) compared with only 6% of specialist registrars (p = 0.009). Geographical variability was evident; Glasgow neurologists advised steroids more readily, with 95%, 74%, and 21% giving them at 24 hours, three days, and seven days, respectively. This compared with 42% (p = 0.002), 42% (p = 0.065), and 17% (p = 0.34) at Edinburgh. There was also a trend for Glasgow physicians to prescribe more acyclovir (21% v 11% (p = 0.37)).

Table 1 Treatment of Bell's palsy by subcategory

	"Yes" responses by consultants	"Yes" responses by registrars	"No" responses by consultants	"No" responses by registrars	OR (95% CI)	p Value
Do you see the patient?	1	1	14	9	0.642 (0.355 to 11.63)	0.5
Steroids within 24 h?	20	12	6	5	1.389 (0.347 to 5.55)	0.25
Steroids within 3 d?	17	9	9	8	1.68 (0.482 to 5.85)	0.18
Steroids within 7 d?	11	1	15	16	11.7 (1.35 to 102)	0.009
Steroids in pregnancy?	2	3	19	13	0.456 (0.067 to 3.12)	0.27
Steroids in Ramsay Hunt?	5	5	20	11	0.55 (0.13 to 2.32)	0.21
Steroids in complete syndrome?	18	10	8	7	1.58 (0.44 to 5.64)	0.20
Steroids in partial syndrome?	11	7	14	8	0.9 (0.25 to 3.25)	0.25
Do you give acyclovir?	6	3	14	9	1.29 (0.255 to 6.49)	0.30

	"Yes" responses by Edinburgh neurologists	"Yes" responses by Glasgow neurologists	"No" responses by Edinburgh neurologists	"No" responses by Glasgow neurologists	OR (95%CI)	p Value
Do you see the patient?	2	0	5	14	NA	
Steroids within 24 h?	5	18	7	1	0.4 (0.004 to 0.403)	0.002
Steroids within 3 d?	5	14	7	5	0.255 (0.05 to 1.19)	0.07
Steroids within 7 d?	2	4	10	15	0.75 (0.11 to 4.9)	0.35
Steroids in pregnancy?	1	3	9	14	0.52 (0.05 to 5.8)	0.39
Steroids in Ramsay Hunt?	2	5	10	12	0.48 (0.08 to 3.03)	0.26
Steroids in complete syndrome?	3	14	9	5	0.12 (0.02 to 0.63)	0.01
Steroids in partial syndrome?	3	9	8	9	0.38 (0.08 to 1.89)	0.15
Do you give acyclovir?	1	3	8	11	0.46 (0.04 to 5.3)	0.37

CI, confidence interval; OR, odds ratio.