

Case report. A 55-year-old woman, with no personal history of atopic disorders, had a 20-year history of severe PD, currently treated with high doses of L-dopa/carbidopa, L-dopa/benserazide, ropinirole, and amantadine. She was given continuous subcutaneous apomorphine infusion for intractable motor fluctuations and dyskinesia. After 5 weeks of treatment, while on permanent infusion at a dosage of 1 mg/h, a dramatic reduction of dyskinesia and "off" periods allowed complete discontinuation of ropinirole and a dose reduction of L-dopa by 50%. However, apomorphine treatment was complicated by the appearance of multiple, painful subcutaneous nodules measuring up to 15 cm in diameter at all infusion sites, starting 14 days after introduction of the drug. A skin biopsy revealed severe eosinophilic panniculitis (figure) with tissue necrosis (not shown), as previously described.³ She also developed an exanthematous maculopapular eruption of the trunk after 16 days of treatment, which resolved with application of topical corticosteroids. The peripheral blood eosinophil count progressively increased from day 5, reaching values $>2,000 \times 10^6$ cells/L since day 22, with a maximum of $2,739 \times 10^6$ cells/L at day 42 (normal upper limit, 500×10^6 cells/L). Oral prednisone (60 mg daily) was then added, leading to a considerable but insufficient reduction of eosinophilia ($1,368 \times 10^6$ cells/L). Serum levels of eosinophil cationic protein, an inflammatory and cytotoxic mediator released from activated eosinophils, were highly elevated ($>200 \mu\text{g/L}$; normal, <12). Total serum immunoglobulin (Ig) E levels were normal. Skin prick tests, intradermal skin tests with the infused apomorphine preparation (to detect drug hypersensitivity of the immediate type), and a lymphocyte proliferation test (to detect drug-specific lymphocyte responsiveness) remained negative. Other common causes of hypereosinophilia, including parasitosis, hematologic, neoplastic, and vasculitic disorders, and allergy to other drugs, were ruled out by appropriate tests. No signs of internal organ involvement, particularly of the lung, heart, or gastrointestinal tract, were found. Liver function remained normal. Despite a reduction of the blood eosinophil count with prednisone, apomorphine was ultimately stopped 59 days after its introduction because of the potentially deleterious effects of chronic hypereosinophilia. The eosinophil blood count normalized shortly thereafter.

Discussion. This patient developed severe eosinophilic panniculitis at the infusion sites, a transient skin rash, and a highly elevated and persistent blood eosinophil count. The mechanism of these reactions is unclear. The large number of eosinophils in the skin biopsy and the abundance of eosinophils in the blood suggest a systemic rather than a local reaction, which may be related to an allergic reaction despite the negative allergy workup. Another hypothesis involves the direct stimulation of pituitary dopamine receptors by apomorphine, as observed in rats not only with apomorphine but also with other dopamine agonists and with L-dopa.⁴ If this were the case, however, hypereosinophilia would have long been reported with other dopaminergic agents and in this patient would have occurred previously.

Chronic blood hypereosinophilia is potentially dangerous because of infiltration and damage of internal organs, particularly the heart and lungs. Severe eosinophilic reaction necessitating apomorphine withdrawal appears to be exceptional, despite its large use in Europe, Canada, and other countries for at least two decades. Another explanation is that this complication may have been underestimated because blood counts are not routinely performed in this situation. With the recent approval of intermittent apomorphine injections for PD in the United States, as well as the consequent increase of the number of patients treated with apo-

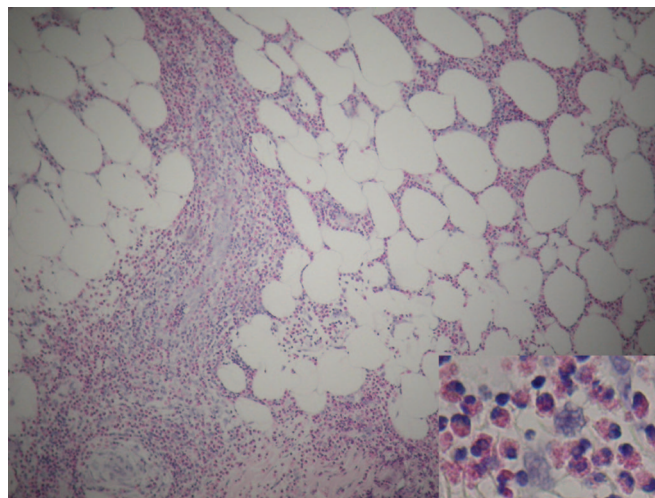


Figure. The histologic pattern of the skin biopsy exhibits lobular and septal panniculitis with massive diffuse eosinophil infiltration (insert shows that approximately two-thirds of the infiltrating cells are eosinophils). Hematoxylin-eosin stain, original magnification $\times 40$.

morphine, we anticipate that this adverse effect may be more frequently recognized, although nodules appear less problematic with intermittent than continuous therapy.^{2,5} We conclude that patients with PD treated with subcutaneous apomorphine infusions should be followed with repeated differential white blood counts.

From the Neurology Department (Drs. Pot, Castillo, Coeytaux, and Burkhard), Allergy Unit, Division of Immunology and Allergy (Drs. Oppliger and Hauser), and Department of Dermatology (Dr. Hauser), Geneva University Hospitals and Medical School, Switzerland.

Received August 1, 2004. Accepted in final form September 15, 2004.

Address correspondence and reprint requests to Dr. Pierre R. Burkhard, Department of Neurology, University Hospital-HUG, 24 rue Micheli-du-Crest, 1211 Geneva 14, Switzerland; e-mail: Pierre.Burkhard@hcuge.ch

Copyright © 2005 by AAN Enterprises, Inc.

References

- Manson AJ, Turner K, Lees AJ. Apomorphine monotherapy in the treatment of refractory motor complications of Parkinson's disease: long-term follow-up study of 64 patients. *Mov Disord* 2002;17:1235-1241.
- Bowron A. Practical considerations in the use of apomorphine injectable. *Neurology* 2004;62(suppl 4):S32-S36.
- Acland KM, Churchyard A, Fletcher CL, Turner K, Lees A, Dowd PM. Panniculitis in association with apomorphine infusion. *Br J Dermatol* 1998;138:480-482.
- Podolec Z, Vetulani J, Bednarczyk B, Szczeklik A. Central dopamine receptors regulate blood eosinophilia in the rat. *Allergy* 1979;34:103-110.
- Deleu D, Hanssens Y, Northway MG. Subcutaneous apomorphine: an evidence-based review of its use in Parkinson's disease. *Drugs Aging* 2004;21:687-709.

Clipping the Eagle's wings: Treatment of an unusual cause of transient cerebral ischemia

Panayiotis N. Varelas, MD, PhD; Grant Sinson, MD; Scott Rand, MD, PhD; and Diane Book, MD

Transient monocular blindness (TMB) associated with hemispheric TIA is indicative of internal carotid artery (ICA) occlusive disease and an increased risk for stroke.¹ However, not all cases of TMB or TIAs reflect intraluminal ICA pathology. We present a patient who had recurrent, stereotypical TMB and hemispheric TIAs from an elongated styloid process compressing the extracra-

nial portion of the ICA, leading to intermittently decreased cerebral blood flow.

Case report. A previously healthy 38-year-old right-handed woman was examined for a 14-month history of recurrent spells, consisting of sudden left eye "graying out," followed by right arm, then right leg heaviness and "shaking," dysarthria, and a feeling of fainting. Symptoms occurred once or twice every 2 to 3 months initially, increasing to three per month. Episodes lasted up to 1 minute and resolved in reverse order. Left head rotation while reaching with her arms was identified as a trigger. Four-vessel cerebral angiography revealed a tortuous left ICA at the mid and distal neck segments and absence of right A1 segment and left posterior communicating artery. A skull base CT revealed bilater-

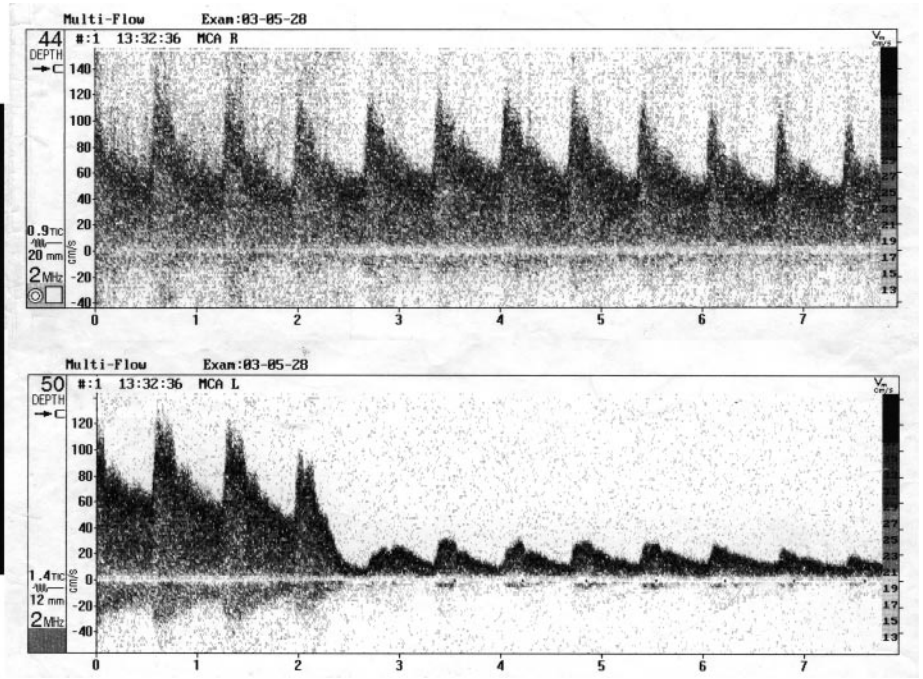
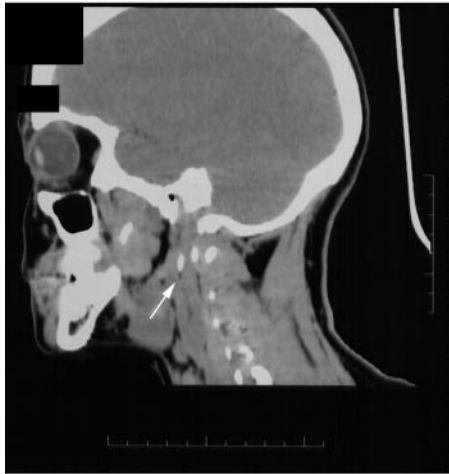

Figure. (Left) Sagittal CT of the head and neck showing abnormal elongation of the left styloid process (white arrow). (Right) Bilateral transcranial Doppler monitoring of the distal middle cerebral arteries (MCAs). There is an abrupt decrease in blood perfusion by head turning to the left in the left MCA (bottom spectral display) but not in the right MCA (top spectral display).

ally elongated (~4 cm) styloid processes. During bilateral transcranial Doppler (TCD) monitoring of the distal middle cerebral artery (MCA), while the patient was standing with the head turned left and the left arm extended, a sudden 72.5% mean cerebral blood flow velocity decrement (from 80 to 22 cm/s) occurred only in the left MCA (figure). The patient became unresponsive and collapsed to the floor. She recovered consciousness on head repositioning. No emboli or change in pulse or blood pressure was detected before and after the episode. After surgical shortening of the 4-cm left styloid process via a cervical incision under general anesthesia, symptoms resolved for a follow-up period of 10 months. On repeat TCD monitoring, there were no positional flow changes.

Discussion. Styloid process syndrome, or Eagle syndrome,² involves mechanical irritation or compression of surrounding neural or vascular structures by an elongated styloid process. The normal styloid process is up to 3 cm long. An elongation occurs in 4 to 7.3% of the general population.³ The highest incidence of symptoms is in those aged 30 to 49 years and is more frequent in women.^{3,4}

Eagle described two distinct groups of patients. In the classic styloid process syndrome, patients report dull, nagging pain in the pharynx radiating into the mastoid area, often after tonsillectomy. In the styloid process–carotid artery syndrome, patients complain of carotidynia, intermittent frontotemporal headaches, otalgia, tinnitus, or syncope.^{2,5} The implicated mechanisms are compression of the neighboring vascular or nerve structures⁶ or dissection of the vessel wall.⁷ Diagnosis of the syndrome is supported by inducing symptoms with direct palpation of the elongated styloid process through the tonsillar fossa. Radiographic studies, such as lateral plain films of the skull or CT of the skull base with three-dimensional reconstruction,⁵ can demonstrate the styloid process length. Surgical excision of the styloid process via neck incision is the preferred treatment in the majority of cases.^{5,6}

Our patient had symptoms of presyncope and ophthalmic and left hemispheric TIAs associated with head position. However, she had never experienced syncopal episodes before the TCD test. The major reduction in the left MCA blood flow velocity with forced head turn probably represents an extreme situation, masking milder left hemispheric and ophthalmic positional ischemic symptoms. We suggest that her incomplete circle of Willis played a

crucial role in developing her focal symptoms. The left carotid territory was isolated from the right side because of an absent proximal anterior cerebral artery segment and from the left posterior circulation because of an absent posterior communicating artery. With mechanical compression of the left cervical carotid by the styloid process, her left carotid territory became hemodynamically deficient. The clinical and sonographic resolution after surgical excision of the styloid process is indicative of ICA decompression. A limitation of our report is that CT angiography of the neck with head rotation, which may have shown the anatomic relation between the styloid and the ICA,⁷ was not available.

From the Departments of Neurology (Drs. Varelas and Book), Neurosurgery (Drs. Varelas and Sinson), and Radiology (Dr. Rand), Medical College of Wisconsin, Milwaukee, WI.

Received June 3, 2004. Accepted in final form September 28, 2004.

Address correspondence and reprint requests to Dr. Panayiotis N. Varelas, Department of Neurosurgery, Froedtert West, 9200 West Wisconsin Avenue, Milwaukee, WI 53226; e-mail: pvarelas@mcw.edu

Copyright © 2005 by AAN Enterprises, Inc.

References

- Benavente O, Eliasziw M, Streifler JY, Fox AJ, Barnett HJ, Meldrum H. Prognosis after transient monocular blindness associated with carotid-artery stenosis. *N Engl J Med* 2001;345:1084–1090.
- Eagle WW. Elongated styloid process. Report of two cases. *Arch Otolaryngol* 1937;25:584–587.
- Harma R. Stylalgia: clinical experiences of 52 cases. *Acta Otolaryngol* 1966;(suppl 224):149+.
- Prasad KC, Kamath MP, Reddy KJ, Raju K, Agarwal S. Elongated styloid process (Eagle's syndrome): a clinical study. *J Oral Maxillofac Surg* 2002;60:171–175.
- Bafaqeh SA. Eagle syndrome: classic and carotid artery types. *J Otolaryngol* 2000;29:88–94.
- Rechtweg JS, Wax MK. Eagle's syndrome: a review. *Am J Otolaryngol* 1998;19:316–321.
- Soo OY, Chan YL, Wong KS. Carotid artery dissection after prolonged head tilting while holding a newborn baby to sleep. *Neurology* 2004;62:1647–1648.

Neurology[®]

Clipping the Eagle's wings: Treatment of an unusual cause of transient cerebral ischemia

Panayiotis N. Varelas, Grant Sinson, Scott Rand, et al.

Neurology 2005;64;393-394

DOI 10.1212/01.WNL.0000149756.32426.56

This information is current as of January 24, 2005

Updated Information & Services	including high resolution figures, can be found at: http://www.neurology.org/content/64/2/393.full.html
References	This article cites 6 articles, 1 of which you can access for free at: http://www.neurology.org/content/64/2/393.full.html##ref-list-1
Subspecialty Collections	This article, along with others on similar topics, appears in the following collection(s): All Cerebrovascular disease/Stroke http://www.neurology.org/cgi/collection/all_cerebrovascular_disease_stroke All Clinical trials http://www.neurology.org/cgi/collection/all_clinical_trials Clinical trials Observational study (Cohort, Case control) http://www.neurology.org/cgi/collection/clinical_trials_observational_study_cohort_case_control CT http://www.neurology.org/cgi/collection/ct Infarction http://www.neurology.org/cgi/collection/infarction
Permissions & Licensing	Information about reproducing this article in parts (figures, tables) or in its entirety can be found online at: http://www.neurology.org/misc/about.xhtml#permissions
Reprints	Information about ordering reprints can be found online: http://www.neurology.org/misc/addir.xhtml#reprintsus

Neurology® is the official journal of the American Academy of Neurology. Published continuously since 1951, it is now a weekly with 48 issues per year. Copyright . All rights reserved. Print ISSN: 0028-3878. Online ISSN: 1526-632X.

