

## Authors:

Marina Babiy, MD  
Michael D. Stubblefield, MD  
Maryann Herklotz, PT  
Michael Hand, PT

Falls

## Affiliations:

From the New York-Presbyterian Hospital; Weill Medical College of Cornell University, New York, New York (MB, MDS); and the Memorial Sloan-Kettering Center, New York, New York (MDS, M. Herklotz, M. Hand).

## Correspondence:

All correspondence should be addressed to Marina Babiy, MD, 436 East 69th Street, 6-C, New York, NY 10021. All requests for reprints should be addressed to Michael D. Stubblefield, MD, Rehabilitation Service, Memorial Sloan-Kettering Center, 1275 York Avenue, New York, NY 10021.

0894-9115/05/8402-0136/0  
*American Journal of Physical  
Medicine & Rehabilitation*  
Copyright © 2005 by Lippincott  
Williams & Wilkins

DOI: 10.1097/01.PHM.0000151943.06257.64

## CASE REPORTS

# Asterixis Related to Gabapentin as a Cause of Falls

## ABSTRACT

Babiy M, Stubblefield MD, Herklotz M, Hand M: Asterixis related to gabapentin as a cause of falls. *Am J Phys Med Rehabil* 2005;84:136–140.

Negative myoclonus, commonly known as asterixis, is often observed in patients with toxic-metabolic encephalopathies or focal brain lesions. It is a movement disorder characterized by postural lapses resulting from brief cessation of tonic muscular contraction. Negative myoclonus has a characteristic appearance on needle electromyography. Lapses in continuous postural muscle activity can lead to falls. This increased risk of falls makes it particularly important to recognize and treat negative myoclonus, especially in patients with multiple medical problems, deconditioning, and gait disturbances. To our knowledge, there have been no published reports implicating negative myoclonus as a cause of falls in adults. We present a case of asterixis as a cause of falls and near falls in a patient with metastatic breast cancer and normal mental status who was receiving gabapentin.

**Key Words:** Falls, Asterixis, Negative Myoclonus, Gabapentin

Falls and near falls occur in about one third of the elderly, and they can lead to major debilities in a large proportion of patients.<sup>1</sup> Falling is associated with injury, immobility, weakness, and isolation. One of the most disabling consequences of falling is the fear of another fall. Falls may occur as the result of a number of disorders, including muscle weakness (stroke, spinal cord injury, and myopathy), syncopal episodes (orthostatic hypotension, aortic stenosis, and cardiac arrhythmias), Parkinsonism, ataxia (vitamin deficiency, cervical spondylosis, cerebellar dysfunction, and spinal cord dysfunction), apraxia (normal pressure hydrocephalus), gait disturbances (Trendelenburg gait from L5 radiculopathy), vertigo, and movement disorders (myoclonus and tremor).<sup>1,2</sup>

Myoclonus can be classified as either positive or negative myoclonus. Positive myoclonus, also known as myoclonus, is a type of movement disorder characterized by involuntary bursts of muscle activity. These bursts of muscle activity cause brief, jerky, shock-like movements. Negative myoclonus is also a motor phenomenon that is characterized clinically by involuntary movements. These movements are superficially similar to those seen with positive myoclonus. Pathophysiologically, however, negative myoclonus differs from positive myoclonus in that the defect is a brief and sudden interruption, as opposed to increase, in muscular activity. Negative myoclonus is synonymous with the

term “asterixis,” a word that was coined by Adams and Foley to describe transient postural lapses resulting from brief cessation of postural tonic electromyographic (EMG) activity.<sup>3</sup> Asterixis is often used to describe the negative myoclonus seen in patients with toxic-metabolic encephalopathies or focal brain lesions.

The combination of positive and negative myoclonus has been known to cause a severe disturbance of balance and gait in patients with myoclonic encephalopathies.<sup>4</sup> Negative myoclonus, in particular, interferes with balance and gait by disrupting control of postural adjustments. This loss of postural control can allow or provoke adverse changes in the position of the body’s center of mass.<sup>2</sup> As a result, patients frequently report feeling unsteady and having a fear of falling. Postural lapses during stance generally occur when a substantial number of muscles are involved or when antigravity muscles are affected.

It stands to reason that the periodic loss of postural control induced by negative myoclonus could lead to falls. Despite the fact that both negative myoclonus and falls are reasonably common, our review of the literature did not reveal previous reports of falls attributable to negative myoclonus in adults. We present a case of negative myoclonus as contributing to falls in a patient with breast cancer who was receiving gabapentin.

## CASE REPORT

A 74-yr-old woman with a medical history of diabetes, hypertension, and stage IV breast cancer with metastasis to bone and liver was admitted to the Memorial Sloan-Kettering Cancer Center for frequent falls and near falls. Her falls had occurred as an outpatient and did not result in injury. When she was seen by the physical therapist as an inpatient, she subjectively reported a fear of falling. Her bilateral lower limbs would buckle transiently and recover spontaneously during transfers and ambulation. She was provided with a rolling walker and began to receive transfer training, gait training, and safety education from the physical therapist. A rehabilitation medicine consult was requested for further evaluation.

The patient had been diagnosed with breast cancer in 1981 and underwent a right-sided modified radical mastectomy followed by chemotherapy with cyclophosphamide, methotrexate, and 5-fluorouracil (CMF). A recurrence of her cancer with bony metastases to the thoracic spine was discovered in 1998. She was treated with tamoxifen, Arimidex, and pamidronate and with radiation therapy to the thoracic spine at the T7 through T9 levels. Radiation was followed by cyclophosphamide, methotrexate, and 5-fluorouracil chemother-

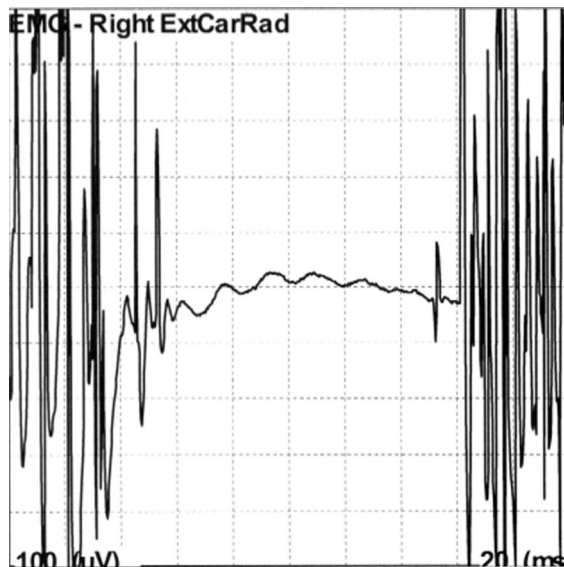
apy. Her disease continued to progress, and by early 2002, she had developed new metastasis to the liver and bone, including the base of the skull and spine. She was treated with doxorubicin, oral dexamethasone, and pamidronate. In mid-2002, she developed T8 epidural spinal cord compression and underwent a posterolateral decompression and fixation without residual neurologic sequelae. Subsequent imaging of her brain and spinal cord did not reveal any additional areas of spinal cord compression, brain metastasis, or leptomeningeal disease. No abnormalities of hepatic or renal function, anoxia, or drug intoxication had been reported in her medical history.

Her medications included gabapentin (300 mg orally twice a day) for neuropathic pain presumed to be secondary to chemotherapy-induced neuropathy, glyburide, metoprolol XL, hydrochlorothiazide/losartan, 100- $\mu$ g fentanyl patch every 3 days, omeprazole, docusate sodium, bisacodyl, epoetin alfa, and sucralfate. Her gabapentin dose had been stable for several months.

On physical examination, her vital signs, including temperature, respiration rate, blood pressure, and pulse were normal. The cardiac, lung, and abdominal examination revealed no abnormalities. Neurologic examination revealed an alert and oriented elderly woman. Her gait was slightly broad based and unsteady, with occasional bilateral knee buckling. The patient demonstrated mild bilateral dysmetria on finger-to-nose-finger and heel-to-shin examination. Negative myoclonus was noted in the bilateral upper limbs by noting a characteristic “flap” while the patient actively extended both hands at the wrists. Negative myoclonus was also noted in the bilateral lower limbs by having the patient actively extend the leg at the knee while the examiner supported the knee. No positive myoclonus was observed and there were no abnormal movements in the face or trunk. Cranial nerves and tone were normal. Sensory examination, including light touch, pinprick, and position sense were normal. Muscle strength was grade 4/5 and symmetric in all muscle groups tested in the bilateral upper and lower limbs. Deep tendon reflexes were absent throughout.

Laboratory values, including sodium, potassium, calcium, glucose, creatinine, prothrombin time, activated partial thromboplastin, and urinalysis, were normal. A limited needle EMG examination of the extensor carpi radialis (Fig. 1) and right vastus lateralis (Fig. 2) was performed and demonstrated intermittent pauses of 40–100 msec on submaximal sustained contraction.

The clinical diagnosis of gait disorder secondary to negative myoclonus and mild ataxia was made. Gabapentin was discontinued because no



**FIGURE 1** Needle electromyographic (EMG) recording from the right extensor carpi radialis (ExtCarRad).

other of the patient's medications had a known association with negative myoclonus. The EMG was not repeated after discontinuation of the gabapentin. The patient was prescribed bilateral soft knee supports for ambulation. Physical therapy continued for lower limb strengthening, gait training, balance training, and safety education for fall prevention. The soft knee supports minimized the buckling of the patient's knees as she ambulated with the rolling walker. Before discharge to a subacute rehabilitation facility, the patient's gait had improved somewhat, and she was able to ambulate safely with supervision and a rolling walker. There were no reported instances of falls during the hospital course. She was lost to follow-up once discharged to the subacute rehabilitation facility, and later died of her metastatic breast cancer.

## DISCUSSION

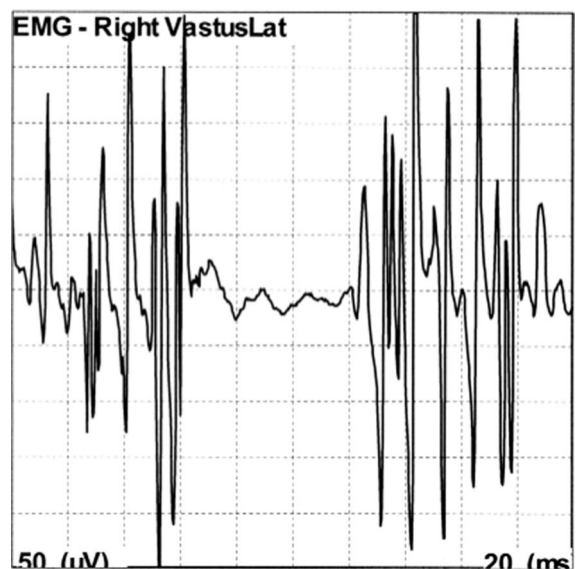
Myoclonus (or positive myoclonus) is a term used to describe involuntary movements that are "brief and shock like."<sup>4</sup> As in clonus, myoclonus is a monophasic phenomenon caused by the involuntary contraction of a muscle, muscle group, or body segment. These contractions are caused by a transient increase in muscle activity. Myoclonic contractions are usually irregular in rhythm and amplitude and involve a muscle group or body segment (segmental myoclonus). These brief bursts of muscle activity (with or without tonic muscular contraction) lead to the abnormal movements that are seen clinically.

Myoclonus can be demonstrated on needle EMG as a burst of electrical muscle activity from

either the resting state or from tonic contraction. The pathophysiology of myoclonus is not well understood and may be a manifestation of a wide variety of pathologic conditions affecting the brain, spinal cord, or even the peripheral nerves. Many types of drugs and toxins have been reported to induce myoclonus, including bismuth salts, valproic acid, lithium, antipsychotic agents, and monoamine oxidase inhibitors.<sup>5</sup> Myoclonus can be seen in epilepsy or in other neurologic conditions.

In contrast to positive myoclonus, the brief, jerky, involuntary movements of negative myoclonus are due to an interruption of muscular activity that causes a sudden postural pause. It usually involves tonically recruited muscles, and the interruption of antigravitational muscle activity results in downward displacement of the joint. Negative myoclonus can be demonstrated in the hands by asking the patient to gently squeeze the examiner's fingers; this results in brief and subtle lapses of tonic muscle activity.<sup>4</sup> Like positive myoclonus, negative myoclonus can be classified as cortical or subcortical, in terms of its origin, and as rhythmic or irregular.<sup>2</sup> It becomes more prominent after sustained activity and is exacerbated by fatigue.

Negative myoclonus interferes with balance and gait by disrupting the control of postural adjustments and thereby provoking abnormal changes in the position of the center of mass.<sup>4</sup> Patients frequently report feeling unsteady, having a fear of falling during walking, and the sensation that knees will "give way." Postural lapses may occur during stance only when significant numbers of muscles involved in antigravity posture are affected simultaneously.<sup>3</sup>



**FIGURE 2** Needle electromyographic (EMG) recording from the right vastus lateralis (VastusLat).

Negative myoclonus can be observed in a variety of clinical conditions ranging from the physiologic form, seen occasionally with the onset of sleep or after prolonged exercise, to the pathologic form observed in patients with toxic-metabolic encephalopathies or with focal brain lesions (asterixis). There is also a paroxysmal form of negative myoclonus known as epileptic negative myoclonus that is seen in epileptic patients.<sup>6</sup> A case report on two children with idiopathic partial epilepsy of childhood has been described. These reports demonstrate epileptic negative myoclonus manifesting as intermittent falls and fecal incontinence.<sup>7</sup>

Asterixis is most easily demonstrated by asking patients to actively extend their wrist with their arms in the extended position.<sup>2</sup> If asterixis is present, the examiner will observe brief and repetitive loss of wrist extension so that the hand seems to flap (liver flap). Asterixis was first described in patients with hepatic encephalopathy, but it is now known to represent a nonspecific neurologic finding associated with multiple forms of toxic and metabolic encephalopathies (hepatic, uremic) and occurs in patients with focal lesions of the central nervous system, including subcortical and brain-stem structural lesions.<sup>6</sup> A number of drugs have been shown to be associated with asterixis, and they include gabapentin, carbamazepine, valproic acid, phenytoin, lithium, clozapine, L-dopa, ifosfamide, and ceftazidime.<sup>5,8,9</sup> A case demonstrating asterixis as a clinical sign of phenytoin toxicity has been described.<sup>9</sup> Asterixis has also been shown to be a primary manifestation of ifosfamide encephalopathy in a patient who had been treated for plasmacytoma.<sup>8</sup> Neurotoxic substances are also associated with asterixis, in particular, ammonia and manganese.<sup>10</sup>

Electrodiagnostically, negative myoclonus is characterized by an interruption of EMG activity for 50–200 msec.<sup>2,4</sup> The duration of the silent period can last up to 400 msec. The longer the duration of postural lapses, the more pronounced and potentially disabling is the movement disorder.<sup>3</sup> Asterixis can be focal or multifocal (involvement of several adjacent muscles simultaneously), but it is usually multifocal in distribution and is very rarely generalized. It often has an arrhythmic presentation and is present only during a tonic, postural muscle contraction. Accordingly, it is never present when a person is at rest.<sup>4</sup>

Involvement of serotonergic, GABA-ergic, benzodiazepine, cholinergic, and dopamine systems could play a role in myoclonic disorders. A number of drugs have been used in the treatment of myoclonus, including 5-hydroxytryptophan, carbidopa, L-dopa, clonazepam, sodium valproate, primidone, apomorphine, ethosuximide, and piracetam.<sup>5,7,10</sup>

There is no study analyzing the effect of antimyoclonic drugs on negative myoclonus. The value of physical therapy has not been evaluated, but it could be potentially beneficial.<sup>4</sup> Our patient responded to physical therapy, safety training, use of an assistive device, and soft knee supports, all of which probably contributed to functional improvement in addition to discontinuation of gabapentin.

Treatment of negative myoclonus should involve identification and correction of metabolic abnormalities and withdrawal of potentially causative or contributing agents, as was done in our patient. Prevention and treatment of hepatic encephalopathy in cirrhotic patients with ammonia-lowering strategies, including lowering dietary protein intake, use of lactulose, neomycin, sodium benzoate, and L-ornithine-aspartate, is recommended. Central nervous system-acting drugs such as benzodiazepine receptor antagonists (flumazenil) and dopamine agonists (L-dopa and bromocriptine) have been used, but with limited success.<sup>5,10</sup> If an offending causative agent has been identified, such as phenytoin or ifosfamide, it should be discontinued or titrated to a lower dosage.

## CONCLUSION

In the present case, multiple medical conditions likely contributed to her history of falls. Although the patient had some degree of what was presumed to be neuropathic pain from chemotherapy, her physical examination did not demonstrate any sensory deficits and the chemotherapeutic agents she had been exposed to are not particularly neurotoxic. She did have symmetrical weakness, likely due to deconditioning, that would be expected to contribute to her falls; however, it was only mild and was out of proportion to the marked knee buckling exhibited on ambulation. It is most likely that the patient's negative myoclonus was a major contributor to her knee buckling and frequent falls.

The cause of this patient's negative myoclonus is also elusive. Her laboratory values did not support a metabolic cause, and save for gabapentin, none of her medications were thought likely to be contributing. The patient did improve when the gabapentin was discontinued, but her physical therapy had been continued and soft knee supports had been added. The relative contributions from each of these modalities cannot be determined.

To the best of our knowledge negative myoclonus has not been described in the literature as a potential cause of falls in adult patients. Because the major clinical manifestation is interruption of tonic postural muscle activity, negative myoclonus may significantly interfere with balance and pos-

tural control during standing and ambulation. It also could result in the subjective sensations of unsteadiness and knee buckling and the fear of falling. The presence of negative myoclonus may be particularly worrisome in patients who are debilitated, deconditioned, or have other disturbances of gait that increase their fall risk. Physicians taking care of such patients need to be particularly vigilant in recognizing negative myoclonus on physical exam. Moreover, negative myoclonus should be considered in the differential diagnosis of patients with multiple falls or near falls that do not have an obvious cause. If necessary, a needle EMG can help confirm the diagnosis of negative myoclonus. Once identified, appropriate treatment of metabolic abnormalities should be instituted, and any offending agents known or suspected to cause negative myoclonus should be discontinued or have their dosages decreased.

#### REFERENCES

1. Braddom RL, Buschbacher RM, Dumitru D, et al: Principles of geriatric rehabilitation, in: *Physical Medicine and Rehabilitation*, ed 2. Philadelphia, W. B. Saunders, 2000, pp 1343–66
2. Shibasaki H: Pathophysiology of negative myoclonus and asterixis. *Adv Neurol* 1995;67:199–209
3. Toro C, Hallett M, Rothwell JC, et al: Physiology of negative myoclonus. *Adv Neurol* 1995;67:211–7
4. Obeso JA, Artieda J, Burleigh A: Clinical aspects of negative myoclonus. *Adv Neurol* 1995;67:1–7
5. Duarte J, Sempere AP, Cabezas MC, et al: Postural myoclonus induced by phenytoin. *Clin Neuropharmacol* 1996; 19:536–8
6. Guerrini R, Dravet C, Genton P, et al: Epileptic negative myoclonus. *Neurology* 1993;43:1078–83
7. Capovilla G, Rubolli G, Beccaria F, et al: Intermittent falls and fecal incontinence as a manifestation of epileptic negative myoclonus in idiopathic partial epilepsy of childhood. *Neuropediatrics* 2000; 31:273–5
8. Meyer T, Ludolph AC, Munch C: Ifosfamide encephalopathy presenting with asterixis. *J Neurol Sci* 2002;199:85–8
9. Chi WM, Chua KS, Kong KH: Phenytoin-induced asterixis: Uncommon or under-diagnosed? *Brain Inj* 2000;14:847–50
10. Butterworth RF: Complications of cirrhosis: Hepatic encephalopathy. *J Hepatol* 2000;32:171–80