

Letter to the Editor

Neurobehavioral changes associated with bilateral caudate nucleus infarctions

In recent years, there has been increasing recognition of the mental and cognitive functions of the basal ganglia.¹ Studies of patients with bilateral lesions localized to the caudate nuclei (CN) could clarify the psychiatric consequences of these structures, but such studies are rare. We recently had the opportunity to observe a patient who presented acute confusional state and other psychiatric symptoms with prefrontal disorders after discrete bilateral caudate infarctions.

A 55-year-old right-handed woman with 12 years of school education was admitted to Seikaen Hospital due to sudden impairment of her mental functions. She went to a mental clinic for depression and mild memory disturbance from 1 year ago. At that time, the Mini Mental State Examination (MMSE) score was 25/30. Also, from 5 months ago, she presented a delusion of persecution that her husband would murder her. On admission she was inattentive and easily distracted. She was grossly disoriented in time, place and person. Her speech was incoherent but was fluent and linguistically intact. There was severe confabulation, perseveration, and circumstantiality. She had very poor concentration and severely impaired short-term memory. Her affect was labile and she often expressed fear. Also, she had visual hallucination. Neurological examination revealed no neurological abnormalities, and in particular no frontal signs and movement disorders. She was normotensive and blood chemistry and hematology were normal. Computed tomography (CT) revealed infarctions involving the bilateral head of CN (Fig. 1). The lesion included the lateral caudate nucleus and the medial caudate nucleus, which are supplied by the lateral lenticulostriate artery. Also, it partly extended to the putamen. The electroencephalogram (EEG) finding on admission showed frontal dominant δ -wave (3 Hz, 100 μ V), and a small quantity of slow α -waves (8–9 Hz, 30 μ V). The slow wave was gradually decreased and the α -waves were increased. After 1 month from admission, treatment was successfully instituted using a haloperidol to achieve some behavioral control. A full psychological assessment was then carried out. She had an average premorbid intellectual function, as indicated by her educational and employment history. Initial MMSE score was 7/30. She tended to repeat her first answer for her perseveration. She did

very poorly on tests of digit span and other tests of frontal function. She could not complete the Trail Making Test, and color–word interaction part of Stroop Test for her perseveration and distractibility. There was poverty on tests of verbal fluency. In contrast, her semantic and episodic memory was intact. During the following weeks, the state of apathy worsened progressively while delusion and anxiety persisted. Her stimulus-bound tendency also continued: she repeatedly pushed the emergency button, being tempted by the sign ‘Push’. Also, she had an obsession: she complained that the idea that her son was killed in a traffic accident repeatedly came into her mind. At 3 months from the admission, such delusion and obsession had disappeared, and the state of apathy worsened. The MMSE score was 17/30. An attempt to stop haloperidol resulted in the emergence of delusion and anxiety. A subsequent administration has resulted in improvement of these symptoms.

Previous reports suggested that the cortical areas that linked to the CN through basal ganglia–thalamo-cortical loops characterized the clinical features of caudate lesions.^{2,3} Our patient initially presented acute agitated delirium characterized by perseveration and stimulus-bound tendency, and then developed general loss of activity and motivation. These symptoms may be accounted for by the fact that the lesions included the areas that linked to the dorsolateral prefrontal cortex.^{1–3} Although the onset of the infarction is not determined, the previous psychiatric symptoms reflected an

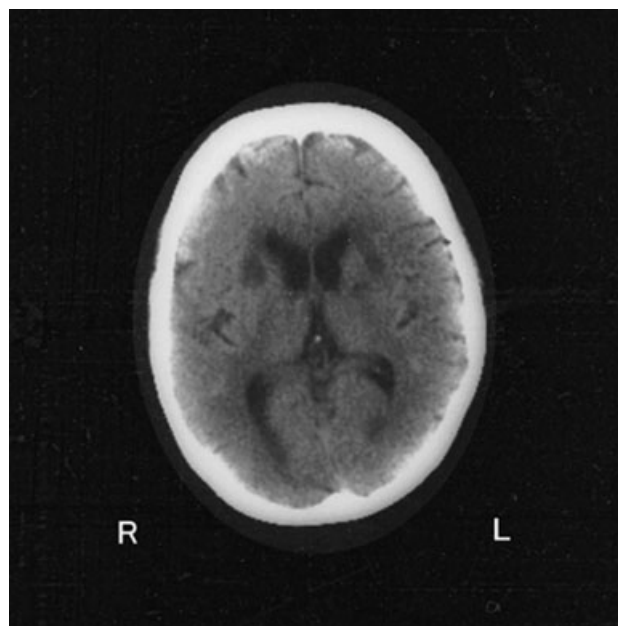


Figure 1. Brain computed tomography demonstrating bilateral caudate infarctions.

ischemic period and the infarction might have occurred on the eve of the presentation of the acute delirium. The clinical symptoms of the vascular lesion of the CN may vary between the stages of the infarction. From a therapeutic standpoint, delusion and unstable emotion were partly responsive to haloperidol. This is in accordance with the report of Petty *et al.* that also reported successful treatment of emotional dyscontrol by haloperidol.⁴ Finally, our patient presented various psychiatric symptoms even after the acute delirium had settled down. Above all, it is interesting that she presented the obsession and the perseveration simultaneously. An obsession is similar to a perseveration in that it repeats without intention. The CN might be critical for intentional control on behavior and thought.

REFERENCES

1. Cummings JL. Frontal-subcortical circuits and human behavior. *Arch. Neurol.* 1993; **50**: 873–880.
2. Mendez MF, Adams NL, Lewandowski KS. Neurobehavioral changes associated with caudate lesions. *Neurology* 1989; **39**: 349–354.
3. Kumral E, Evyapan D, Balkir K. Acute caudate vascular lesions. *Stroke* 1999; **30**: 100–108.
4. Petty RG, Bonner D, Mouratoglou V, Silverman M. Acute frontal lobe syndrome and dyscontrol associated with bilateral caudate nucleus infarctions. *Br. J. Psychiatry* 1996; **168**: 237–240.

JIN NARUMOTO, MD¹
 NOBUKO MATSUSHIMA, MD²
 SYOGO OKA, MD²
 HIROSHI SHIMIZU, MD²
 YUKIKO KOOGUCHI, MD¹
 YURINOSUKE KITABAYASHI, MD¹
 MASAHIRO KUNIZAWA, MD¹
 HIDEKI UEDA, MD¹
 KENJI FUKUI, MD¹

¹Department of Psychiatry, Graduate School of Medical Science, Kyoto Prefectural University of Medicine, Kyoto and
²Seikaen Hospital, Kochi, Japan

Correspondence address: Dr Jin Narumoto, Department of Psychiatry, Graduate School of Medical Science, Kyoto Prefectural University of Medicine, 465 Kajji-cho, Kawaramachi-Hirokoji, Kamigyo-ku, Kyoto 602-8566, Japan. Email: jnarumoto@koto.kpu-m.ac.jp
 Received 2 April 2004; revised 21 May 2004; accepted 31 May 2004.