

Stroke-Associated Acquired Stuttering

By Robert G. Fawcett, MD

FOCUS POINTS

- Sudden onset of stuttering in an adult may have an organic origin, most often a stroke.
- Acquired stuttering can be associated with brain infarcts in various cortical and subcortical areas.
- Acquired stuttering frequently differs from developmental stuttering in speech patterns and associated motor phenomena.

ABSTRACT

In this case report, the syndrome of acquired stuttering is described including its etiology, common presenting features, and differences from developmental stuttering. A case is described in an elderly female patient with sudden acquired stuttering associated with ischemic infarct near the left basal ganglia.

CNS Spectr. 2005;10(2):94-95

INTRODUCTION

Acquired stuttering is an uncommon phenomenon that has been associated most frequently with stroke, but also with head injury and medications, including phenothiazines, tricyclic antidepressants, and selective serotonin reuptake inhibitors.¹⁻⁴ It is usually sudden in onset and may be associated with aphasia, dysarthria, or other neurologic signs. Lesions in all lobes of the cortex as well as subcortical, thalamic, and mid-brain regions have been associated with acquired stuttering.⁵⁻⁷ Acquired stuttering, in contrast to developmental stuttering, often is not restricted to initial phonemes, occurs in monosyllabic and polysyllabic words, does not adapt, does occur during singing, and is not associated with collateral motor phenomena, such as grimacing or clenching of the fist.⁸ Stroke-related cases have been associated with left-sided or bilateral lesions and with difficulties in tests of nonlinguistic motor control.³ Described below is a case of the sudden onset of stuttering remarkable for the paucity of other associated symptoms of acute stroke.

CASE REPORT

An 84-year-old, left-handed widow, whom I had treated for 20 years for recurrent major depression and generalized anxiety disorder, reported a sudden onset of speech difficulty. She had a history of hypertension, gastroesophageal reflux disease, goiter, and hypercholesterolemia. Years before, she had undergone surgery for cervical spinal stenosis and had placement of a ventricular shunt for normal pressure hydrocephalus 2 years previously. Her speech was aprosodic and showed stammering with repetition of initial phonemes but she was able to say several words correctly in the middle of a statement. Speech recognition was good. She could not repeat "No ifs, ands, or buts" because of her stammering, but could say "Ta ta ta." She could sing "Jingle Bells" without stuttering. She displayed dysdiadochokinesis, worse in the right hand and had mild right facial weakness. Neuromuscular signs which had not changed in recent months, included increased muscle tone, decreased strength of lower extremities, slight bradykinesia, and tremor with an intention and postural component. She used a wheeled walker with a slow, wide-based gait. She was mildly disoriented in time, and recalled one of three objects in 3 minutes. However, she was able to perform simple calculations and recall several recent United States presidents. This cognitive performance was consistent with her 27 out of 30 score in a Mini-Mental State Exam⁹ achieved 6 months before the speech difficulty began. She was seen by her neurologist, whose initial recommendation was to target her symptoms of anxiety. Successive individual additions of bupropion sustained-release 100 mg/day, clonazepam 0.25 BID, and primidone 25 mg/day to her regimen of fluoxetine 20 mg/day did not improve her speech.

Increasing depression related to her difficulties in conversing led to a psychiatric hospitalization 3 months after the onset of her speech difficulties. A computed tomography scan performed during that hospitalization (Figure) showed an area of low attenuation lateral to the left basal ganglia con-

Dr. Fawcett is psychiatrist at Little Traverse Psychiatric Associates, PC, in Petoskey, Michigan.

Disclosure: Dr. Fawcett has received honoraria from Abbott, Janssen, Pfizer, and Wyeth. This article was submitted on April 16, 2004, and accepted on August 31, 2004.

Please direct all correspondence to: Robert G. Fawcett, MD, Little Traverse Psychiatric Associates PC, 2206 Mitchell Park Drive, Suite 10, Petoskey, MI 49770; Tel: 231-487-2415, Fax: 231-487-6569; E-mail: 4dripgs@chartermi.net.

sistent with an old lacunar infarct, which had not been present on previous computed tomography scans. The ventriculostomy and mild prominence of her ventricles were unchanged from previous exams.

Speech therapy was begun along with psychotherapy and an increase in her fluoxetine from 20 mg/day to 40 mg/day. Her mood improved. After hospital discharge, speech therapy was continued and she became more confident talking with others and no longer avoided social encounters. Two years later, her speech was still abnormal with some initial stammering and dysprosody but improved from her original presentation.

This patient's acquired stuttering occurred suddenly, not in the context of any medication changes, was associated in time with some impairment of her right-sided motor performance and with a lacunar infarct in her left basal ganglia, an area which has previously been associated with acquired stuttering.³ She had a history of normal pressure hydrocephalus that caused some bilateral cortical changes. Some features of her acquired stuttering, namely restriction to initial phonemes and ability to sing without stuttering, while not typical of acquired stutterers, have been reported previously. Her speech impairment exacerbated her depression. Speech therapy led to sustained improvement of her speech but not an abolition of the acquired stuttering.

CONCLUSION

Acquired stuttering is a syndrome associated with an insult to the brain, physical, or chemical, but most vascular. Lesions in various cortical and subcortical regions have been associated with it. Speech patterns that may distinguish acquired stuttering from developmental stuttering are not always reliable. Acquired stuttering may improve as the underlying pathophysiology improves or with the aid of speech therapy. **CNS**

REFERENCES

1. Meghji C. Acquired stuttering. *J Fam Pract.* 1994;39:325-326.
2. Grant A, Bioussé V, Cook A, Newman N. Stroke-associated stuttering. *Arch Neurol.* 1999;56:624-627.
3. Ciabarra AM, Elkind MS, Roberts JK, Marshall RS. Subcortical infarction resulting in acquired stuttering. *J Neurol Neurosurg Psychiatry.* 2000;69:546-549.
4. Nurnberg H, Greenwald, B. Stuttering: an unusual side effect of phenothiazines. *Am J Psychiatry.* 1981;138:356-357.
5. Ardila A, Lopez M. Severe stuttering associated with right hemisphere lesion. *Brain Lang.* 1986;27:239-246.
6. Balasubramanian V, Max L, Van Borsel J, Rayca KO, Richardson D. Acquired stuttering following right frontal and bilateral pontine lesion: a case study. *Brain Cogn.* 2003;53:185-189.
7. Doi M, Nakayasu H, Soda T, Shimoda K, Ito A, Nakashima K. Brainstem infarction presenting with neurogenic stuttering. *Intern Med.* 2003;42:884-887.
8. Helm N, Butler R, Benson D. Acquired stuttering. *Neurology.* 1978;28:1159-1165.
9. Folstein MF, Folstein SE, McHugh PR. "Mini-mental state": a practical method for grading the cognitive state of patients for the clinician. *J Psychiatry Res.* 1975;12:189-198.

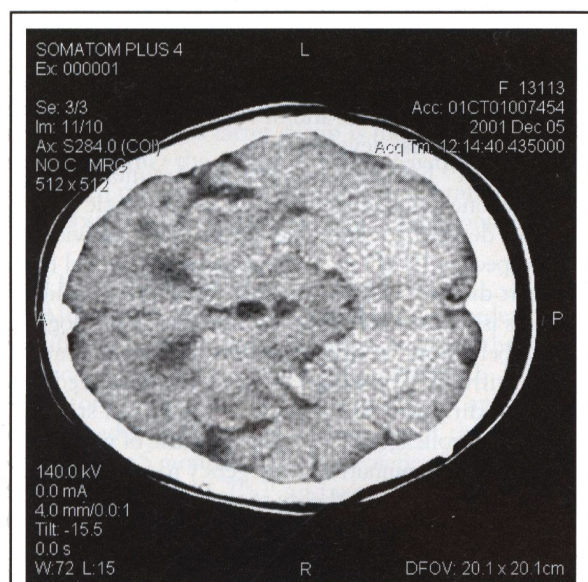


FIGURE. CT scan showing infarct in area of the left basal ganglia

L=left; A=anterior; P=posterior; R=right; Ex=exam; Se=series; Im=image; Ax=axial; NOC=no contrast; MRG=initials of technician; Acc=accession number; Acq Tm=acquisition time; DFOV=defined field of view; CT=computed tomography.

Fawcett RG. *CNS Spectr.* Vol 10, No 2. 2005.