

Celso Agner
Spencer G. Weig

Arterial dissection and stroke following child abuse: case report and review of the literature

Received: 21 January 2004
Revised: 19 April 2004
Published online: 5 February 2005
© Springer-Verlag 2005

C. Agner (✉)
Department of Neurosurgery
Albany Medical Center,
41 Forest Avenue, # 2,
Albany, NY, 12208, USA
e-mail: cagner@nycap.rr.com
Tel.: +1-518-4895164
Fax: +1-518-4895164

C. Agner · S. G. Weig
Department of Neurology
Albany Medical Center,
41 Forest Avenue, # 2,
Albany, NY, 12208, USA

Abstract *Introduction:* Arterial dissection and stroke following trauma are seen frequently. Although similar mechanisms occur for trauma and child abuse, no reports of stroke have been observed in the literature. *Case reports:* Two patients successively presented to our institution with acute onset of neurological deficit and stroke. Further evaluation disclosed child abuse as an underlying condition leading to the strokes. Child protection services were contacted immediately after admission of the patients and further measures were taken. *Conclusions:* Recognition of potential cases of child abuse is

crucial. Early intervention and cessation of interaction between the aggressor and the child are important measures to be taken in all situations when there is strong evidence of suggestive examination of child abuse.

Keywords Trauma · Stroke · Internal carotid · Vertebral artery · Dissection

Introduction

Carotid and vertebral artery dissections have been extensively reported in association with persistent extended position of the neck or in abrupt movement of the cervical region, as occurs in motor vehicle accidents. Although similar mechanisms of trauma occur in some instances of physical child abuse (“shaken baby syndrome”), there are no reports of stroke in association with this condition in the literature.

Subdural hematoma and intraparenchymal hemorrhage are the most frequently encountered intracranial injuries following shaking injury [11, 14, 16, 28]. Concomitant findings of retinal hemorrhage in association with multiple fractures or injuries on bone survey strongly suggest child abuse as an underlying factor contributing to the condition [3, 6, 8, 10, 12]. To date, there have been no descriptions of intracranial dissection of vessels in association with shaking injury.

We describe two cases of arterial dissection and stroke in children who have sustained an abusive shaking injury. The petrosal portion of the internal carotid artery was involved and the stroke represented the same vascular territory. We review the pertinent literature regarding identification and treatment of this specific condition.

Case reports

Patient 1

A 4-month-old girl presented to the emergency department in status epilepticus. The child had no significant previous medical history and had been the normal birth weight product of an uncomplicated pregnancy, labor, and delivery to a 19-year-old primigravida. The child’s health was good and her development was normal for her age. Her biological father was not involved. The family unit consisted of the

mother, infant, and the mother's boyfriend who often watched the child while the mother worked. On the day of admission the mother returned home to find the infant irritable. The boyfriend claimed that the infant slipped from his arms while he was attempting to bathe her in a shower. Shortly thereafter the mother noted acute onset of partial seizures with stiffening of the right leg and arm associated with tonic eye deviation to the left. The seizure persisted on arrival to the emergency room 30 min later, but resolved promptly with intravenous lorazepam. Initial neurological examination was limited by sedation, but a left gaze preference was noted.

A computed tomography (CT) scan showed a 5-cm hypodensity in the left temporal and parietal regions with a second 3-cm hypodensity in the parafalcine region of the left frontal lobe, consistent with acute infarctions. A small amount of extra-axial blood was noted layering along the anterior parafalcine surface of the left frontal lobe. Shortly thereafter a magnetic resonance image (MRI) of the brain, including diffusion-weighted imaging (DWI) sequences, demonstrated large areas of infarction, primarily in the posterior aspect of the left middle cerebral artery distribution, but also involving zones in the left anterior and posterior cerebral artery distribution (Fig. 1a). A magnetic resonance angiogram (MRA) of the neck showed a dissection of the left internal carotid artery in its petrosal portion (Fig. 1b).

On dilated pupil examination, subhyaloid retinal hemorrhages were seen bilaterally. Vitrectomy was ultimately required in the left eye. There was no evidence of sexual abuse. Skeletal survey was normal. The incident was reported to Children's Protective Services as a non-accidental injury and the boyfriend was removed from the home under an order of protection.

Clinically, the child did well. In view of the subdural and subhyaloid bleeding, she was not anticoagulated. A repeat MRI done 3 months following the injury showed areas of encephalomalacia in the left temporal, parietal, and occipital lobes corresponding to the previously noted areas of abnormal DWI signal. Seizures responded promptly to phenobarbital. She remained seizure free and was tapered off phenobarbital after 1 year. At that point her only deficit on examination was decreased vision in the left eye.

Patient 2

A 2-year-old boy presented with a 24-h history of unsteady gait and tremors in the right arm. There was no history of trauma or antecedent illness. The family was known to the Children's Protective Services due to a suspicious puncture injury to the child's right leg several months earlier. On examination he was irritable but awake. Cranial nerve and fundoscopic examination was normal. He was tremulous when reaching for objects with either hand and his gait was very unsteady. No other motor deficits were noted.

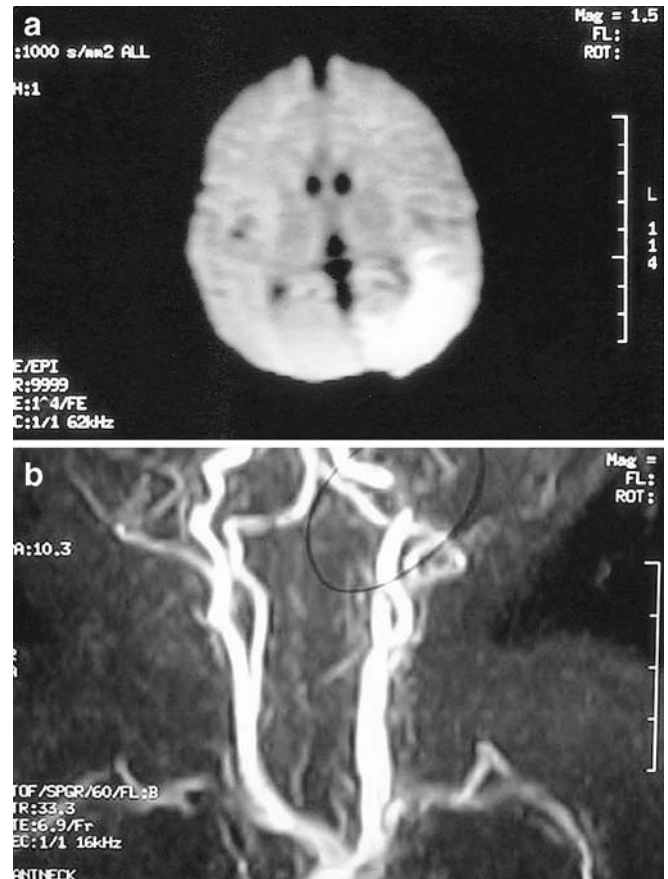


Fig. 1 Representation of radiologic findings in patient 1. **a** MR diffusion-weighted image showing the left posterior parietal stroke. **b** MR angiography showing the left internal carotid artery dissection.

A plain skull X-ray showed a non-comminuted C2 fracture without any particular skull fracture appreciated. There was no spine compression on the MRI of the spine (Fig. 2a). The diffusion-weighted sequence on the brain MRI showed multiple areas of infarction in both cerebellar hemispheres as well as multiple infarcts in the right posterior cerebral artery distribution (Fig. 2b). MRA demonstrated patency of both vertebral arteries in the inferior portion of the neck, but with no flow identified on the left above the C2 level (Fig. 2c). CT of the cervical spine showed anterolysthesis of C2 on C3 with bilateral C2 pars fractures.

The family unit consisted of the mother, her boyfriend, and her three children. Initially the mother claimed that a 4-year-old sibling had stepped on the patient's neck. When informed that did not seem to be a plausible explanation for this degree of injury, the boyfriend admitted to holding the child upside down by the ankles and shaking him vigorously. The incident was reported to Children's Protective Services and the boyfriend was removed from the home under an order of protection.

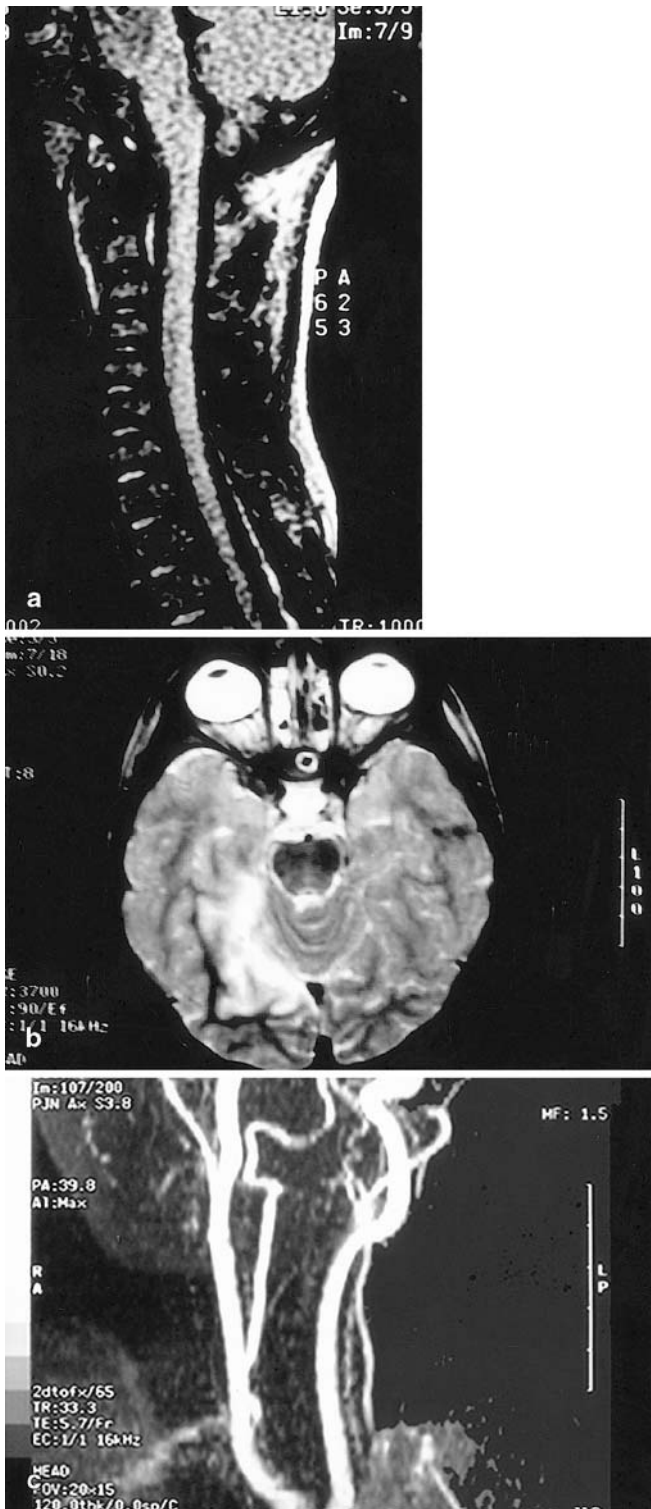


Fig. 2 Representation of the radiologic findings in patient 2. **a** Cervical MRI demonstrating a C2 fracture without spinal cord compression. **b** MRI diffusion-weighted image showing the right posterior cerebral artery territory infarction. **c** MRA of the cervical vessels, demonstrating the presumed vertebral artery dissection.

Clinically, the child did well. He was treated with warfarin for 3 months. The cervical fractures and anterolisthesis responded to immobilization with a firm collar. When last seen 18 months following the injury, his neurological examination was normal.

Discussion

Child abuse is an under-reported condition and varies among different cultures and backgrounds. During 1996, the Department of Health and Human Services reported over two million cases of maltreatment of more than three million children. Currently, over 14 per 1,000 children are victimized, with approximately 1,200 fatalities a year. Physical abuse alone corresponds to 24% of the cases of maltreatment reported. Just in 1996, 25.3% of children were victims of more than one modality of abuse. The majority of victimized children were whites, followed by African-Americans and Hispanics. Fatalities occur mostly among children aged 5 or younger and sexual abuse is more prevalent among girls. Frequently, the perpetrator is a depressed, low-income mid-20s individual who is unable to cope with stressful situations. Every 10 s a child is abused and physical abuse by itself kills more children than accidents. Factors increasing the incidence of child abuse include young age of the mother, substance abuse, lack of parental skills, poverty, domestic violence, and poor understanding of the child's normal developmental path. Reporting of cases of child abuse stems from professionals in 52% of the cases, 18% from families of victims, 9% from friends or neighbors, and 20% anonymous. In less than 1%, reporting comes from the victims [26]. Despite thorough investigation, often the abused victim is encountered after repetitive trauma and dramatic physical consequences. Physical abuse, in particular, is associated with a higher incidence of arterial dissection in adults [19, 21, 24, 27], but the mechanisms of vascular injury differ among the different age groups, as the anatomy of the vessels and the relationship between the bony segments are also changed.

Recognition of child abuse cases depends on search for multiple associated injuries in association with hallmarks of abuse, such as geographic marks, broken bones at different stages of healing, or even a "risky" social environment with a "non-fitting" clinical history. The identification of those cases permits immediate action of the child protection services, identification of the aggressors and of the potential victims, as well as protection of the population at target.

Retinal hemorrhage [1, 3, 7, 17], subdural hematoma [2], subarachnoid hemorrhage [22], and strokes [18] have all been reported in the literature and are generally concomitant to the child abuse presented. Vascular dissection has been observed in a few instances secondary to strangulation in association with child abuse. Evidence of

vascular dissection in shaken babies has been under-reported, although clinical history suggests vascular compromise in association with abrupt movements of the neck in similar situations. Spontaneous cervical vascular dissections have also been reported and may participate in the pathophysiology of some conditions [5]. We described two unusual cases of cervical vascular dissection directly associated with child abuse.

In 1989, Fukuda et al. described a case of bilateral carotid and vertebral artery disruption following child abuse. In those situations, a common circumstance is dissection of the vertebral artery at the origin of the vessel, at the level of the subclavian artery. In children, the mobile point is located at the craniocervical junction and, particularly in situations where there is fracture at the high cervical level, dissection is presumed to occur. In young children, whose skull base bones are not completely formed, there is a tendency for higher ligamentous laxity, permitting mobilization of higher vertebral artery segments [13]. In our second case, fracture at the C2 level might have accounted for the dissection observed. In some cases, artery–artery embolism, in particular from the vertebral artery to the posterior cerebral artery may explain posterior circulation infarcts, as represented in our second patient.

Vascular dissection generally occurs after the fixation point of an artery. Carotid arteries generally dissect intracranially in children, as the basilar skull is somewhat mobile at points where the cartilaginous tissue is not completely ossified. The mechanism of arterial dissection after physical child abuse is not well understood. Presumably, dissection of the intracranial segments of the carotid artery occurs secondary to direct trauma of the petrosal part of the carotid artery, as the cervical segment is more flexible and, thus, less prone to injury [23]. The different structure of the skull base bone in children predisposes the latter to prolongation of the dissection intracranially and stroke in the territories of the middle or anterior cerebral arteries.

Although subdural hematomas may occur spontaneously on rare occasions, evidence of this condition without signs of major trauma suggests abuse and the social environment should be searched thoroughly. Bird et al. recognized, in 1987, strangulation as a cause of subdural hematomas in children [4]. According to them, rupture of small tributaries to the major sinuses contributes to the condition and abuse should be highly suspected. Venous infarcts can also be recognized in association. Computed tomographic analyses helped in identifying the involution of vascular anomalies in victims of child abuse [25]. Moreover, it was able to identify vascular conditions that could not be initially appreciated [20].

In 1991, Thyen and Tegtmeyer reported three cases of child abuse associated with cerebrovascular compromise. In their retrospective review, there was mention of one internal carotid thrombosis and one subarachnoid hemorrhage [29]. According to the authors, the underlying mech-

anisms are direct vascular trauma from shaking or direct blows to the head. Vascular thrombosis could be partially explained by displacement of the intima and exposure of the subendothelial region, with formation and propagation of a clot [9].

We described one case of intracranial carotid dissection secondary to child abuse. Shaking of young children may predispose to rupture of the intimal layer and progressive clotting of the artery upstream from the dissection. In children, due to the malleability of the neck, injury to cervical arteries is not observed frequently. The back-and-forth movement of the head and trauma to bony segments of intracranial vessels may occur as a result of displacement of forces from the rigid skull to cartilaginous portions of tissue that will not lessen the transmission of trauma from one part of the skull to another. In our patient, an arterio-arterial embolism from the dissected vessel to the posterior branch of the middle cerebral artery (M2 segment) could explain the stroke observed. Lack of evidence of arterial dysplasia and the combined conundrum of trauma and social history provided us with the tools to diagnose child abuse as the primary etiology for the reported condition. Treatment with anticoagulation is the gold standard as prevention of further injuries in arterial dissection. It does not, however, resolve the initial problem and, in cases of heparin failure, either combination with antiplatelet agents, such as aspirin or clopidogrel, or even consideration for arterial stenting or angioplasty may play a role.

The management of vascular dissection in children is still debatable. Although anticoagulation is the gold standard of management, there is no literature to support such a decision. In some situations, neuroendovascular approaches, such as placement of intra-carotid stents, intra-arterial thrombolysis, or the use of rheolytic catheters may be attempted with successful results [27]. However, consensus is still far from being reached.

In conclusion, child abuse needs to figure among the differential diagnoses of stroke in young children. Its under-reported nature indicates that the problem may occur much more often than expected and the best prevention is early identification of the aggressors and permission for the protection of children from their deeds.

Prevention and awareness of physical abuse in children may help prevent the occurrence and recurrence of neurological complications related to the condition. Further understanding of the mechanisms of injury may permit novel modalities of treatment that will prevent propagation of clotting in cases of arterial dissection.

Prevention of strokes and rehabilitation are particularly important in the physical abuse of children. Prompt recognition of the condition by neurologists and neurosurgeons permits early investigation of the aggressors and decision on treatment modality, including cervical fixation and/or endovascular approaches for correction of the vascular dissection encountered.

References

1. Altman RL, Kutscher ML, Brand DA (1998) The "shaken-baby syndrome". *N Engl J Med* 339:1329–1330
2. Aoki N, Masuzawa H (1986) Subdural hematomas in abused children: report of six cases from Japan. *Neurosurgery* 18:475–477
3. Bacon CJ, Sayer GC, Howe JW (1978) Extensive retinal haemorrhages in infancy—an innocent cause. *Br Med J* 1:281–292
4. Bird CR, McMahan JR, Giles FH, Senac MO, Apthorp JS (1987) Strangulation in child abuse: CT diagnosis. *Radiology* 163:373–375
5. Brandt T, Grond-Ginsbach C (2002) Spontaneous cervical artery dissection: from risk factors toward pathogenesis. *Stroke* 33:657–658
6. Caffey J (1974) The whiplash shaken infant syndrome: manual shaking by the extremities with whiplash-induced intracranial and intraocular bleedings, linked with residual permanent brain damage and mental retardation. *Pediatrics* 54:396–403
7. Christian CW, Taylor AA, Hertle RW, Duhaime AC (1999) Retinal hemorrhages caused by accidental household trauma. *J Pediatr* 135:125–127
8. Clark BJ (2001) Retinal hemorrhages: evidence of abuse or abuse of evidence? *Am J Forensic Med Pathol* 22:415–416
9. Demaerel P, Casteels I, Wilms G (2002) Cranial imaging in child abuse. *Eur Radiol* 12:849–857
10. Eisenbrey AB (1979) Retinal hemorrhage in the battered child. *Childs Brain* 5:40–44
11. Feldman KW, Brewer DK, Shaw DW (1995) Evolution of the cranial computed tomography scan in child abuse. *Child Abuse Negl* 19:307–314
12. Friendly DS (1971) Ocular manifestations of physical child abuse. *Trans Am Acad Ophthalmol Otolaryngol* 75:318–332
13. Fukuda I, Meguro K, Matsusita S, Shigeta O, Oohashi N, Nakata Y (1989) Traumatic disruption of bilateral vertebral arteries and internal carotid arteries: case report. *J Trauma* 29:263–266
14. Fulton DR (2000) Shaken baby syndrome. *Crit Care Nurs Q* 23:43–50
15. Fung EL, Sung RY, Nelson EA, Poon WS (2002) Unexplained subdural hematoma in young children: is it always child abuse? *Pediatr Int* 44:37–42
16. Geddes JF, Hackshaw AK, Vowles GH, Nickols CD, Whitwell HL (2001) Neuropathology of inflicted head injury in children. I. Patterns of brain damage. *Brain* 124:1290–1298
17. Geddes JF, Whitwell HL, Tasker RC (2003) Shaken baby syndrome. *Br J Neurosurg* 17:18–23
18. Glasier CM, Seibert JJ, Williamson SL (1987) Cerebral infarction in child abuse. Diagnosis by technetium-99 m methylene diphosphonate skeletal scintigraphy. *Clin Nucl Med* 12:897–898
19. Hughes KM, Collier B, Greene KA, Kurek S (2000) Traumatic carotid artery dissection: a significant incidental finding. *Am Surg* 66:1023–1027
20. Levine LM (2003) Pediatric ocular trauma and shaken infant syndrome. *Pediatr Clin North Am* 50:137–148
21. Malek AM, Higashida RT, Halbach VV, Dowd CF, Phatouros CC, Lempert TE, Meyers PM, Smith WS, Stoney R (2000) Patient presentation, angiographic features, and treatment of strangulation-induced bilateral dissection of the cervical internal carotid artery. Report of three cases. *J Neurosurg* 92:481–487
22. Mant AK (1972) Traumatic subarachnoid haemorrhage following blows to the neck. *J Forensic Sci Soc* 12:567–572
23. Massicotte SJ, Folberg R, Torczynski E, Gilliland MG, Luckenbach MW (1991) Vitreoretinal traction and perimacular retinal folds in the eyes of deliberately traumatized children. *Ophthalmology* 98:1124–1127
24. Milligan N, Anderson M (1980) Conjugal disharmony: a hitherto unrecognized cause of strokes. *Br Med J* 281:421–422
25. Ommaya AK, Goldsmith W, Thibault L (2002) Biomechanics and neuropathology of adult and paediatric head injury. *Br J Neurosurg* 16:220–242
26. Rabl W, Ambach E, Tributsch W (1991) Protrahierte Asphyxie nach "Schutteltrauma". *Arch Kriminol* 187:137–145
27. Schroth G, Lovblad KO, Ozdoba C, Remonda L (2002) Non-traumatic neurological emergencies: emergency neuroradiological interventions. *Eur Radiol* 12:1648–1662
28. Starling SP, Holden JR (2000) Perpetrators of abusive head trauma: a comparison of two geographic populations. *South Med J* 93:463–465
29. Thyen U, Tegtmeyer FK (1991) Das Schutteltrauma des Sauglings—eine besondere Form der Kindesmisshandlung. *Monatsschr Kinderheilkd* 139:292–296