
Selected Topics: Toxicology

DELAYED ISCHEMIC STROKE ASSOCIATED WITH METHAMPHETAMINE USE

Keiko Ohta, MD,* Masae Mori, MD,* Asako Yoritaka, MD,* Kouichiro Okamoto, MD,† and
Shuji Kishida, MD*

*Department of Neurology and †Department of Neurosurgery, Tokyo Metropolitan Komagome Hospital, Tokyo, Japan
Reprint Address: Keiko Ohta, MD, Department of Neurology, Tokyo Metropolitan Komagome Hospital, 3-18-22, Honkomagome,
Bunkyo-Ku, Tokyo, Japan, 113-8677

□ **Abstract**—A 19-year-old woman had right occipital infarction 3 months after she had injected methamphetamine. No other possible causes of stroke could be found in this case. Magnetic resonance angiography revealed beading of the right posterior cerebral artery, which suggested vasculitis. Her symptoms were right-sided headache, left superior quadrant hemianopia, and left hypesthesia, which gradually improved without any treatment. Methamphetamine has been known to cause hemorrhagic and ischemic stroke relatively soon after administration. We report here that methamphetamine may also cause chronic cerebral vasculitis and delayed ischemic stroke. © 2005 Elsevier Inc.

□ **Keywords**—methamphetamine; ischemic stroke; cerebral vasculitis; drug abuse; headache

INTRODUCTION

Methamphetamine is the most popular drug among young abusers in Japan. It may lead to hemorrhagic strokes relatively soon after administration (1). We report a delayed ischemic stroke in a methamphetamine user.

CASE REPORT

A 19-year-old woman had used methamphetamine intravenously four times over 2 months. Because she felt

severe headache every time except the second, she stopped injection. But headache continued and about 3 months later she had an attack of severe right-sided headache. She also noticed blurred vision on the left side and numbness of the left arm and leg. She came to our hospital 2 days after the onset. Family history was unremarkable. She suffered from duodenal ulcer at age 16. Otherwise she was healthy and she had not suffered from any other diseases. She had smoked 20 to 40 cigarettes and had drunk 600 to 800 mL of alcoholic drinks daily for a few years. She declared that she had not used methamphetamine for 3 months before the onset, because when she had injected it last time, her headache had been too severe to bear. She also denied use of any other drugs including oral contraceptives.

On physical examination, the patient's blood pressure was 110/70 mm Hg. The general physical examination and mental status evaluation were unremarkable. The visual acuity was normal but visual field evaluation revealed left superior quadrant hemianopia. Motor function was normal. She had slight hypesthesia of the left face, arm and leg. We followed her as an outpatient for several weeks. Her symptoms continued and analgesics were not very effective for her headache. She entered our hospital for further examination.

Results of laboratory investigations including complete blood count, serum chemistry, glucose, total

Selected Topics: Toxicology is coordinated by *Kenneth Kulig*, MD, of Denver, Colorado

RECEIVED: 11 July 2003; FINAL SUBMISSION RECEIVED: 21 May 2004;
ACCEPTED: 8 June 2004

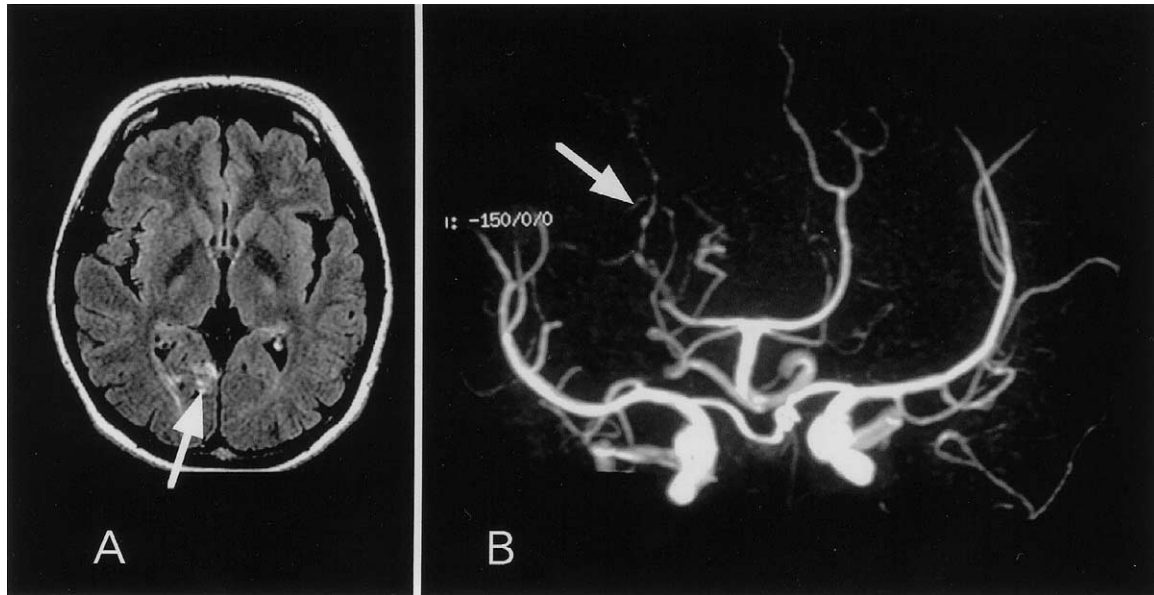


Figure 1. A) Fluid-attenuated inversion recovery (FLAIR) MR image shows high signal intensity in the medial part of the right occipital lobe (arrow). B) MR angiography shows segmental narrowing (beading) of the right posterior cerebral artery (arrow).

cholesterol, C-reactive protein, VDRL, prothrombin time, and partial thromboplastin time were normal. Anti-cardiolipin antibody, lupus anticoagulant, anti-thrombin III, thrombin-antithrombin III complex (TAT), and perinuclear-antineutrophil cytoplasmic antibody (P-ANCA) were all negative. Cerebrospinal fluid was clear with one cell, normal protein and glucose. An electrocardiogram and an echocardiogram were also unremarkable.

An immediate brain computed tomography (CT) scan was obtained, and a magnetic resonance imaging (MRI) study after 10 days showed right occipital infarction (Figure 1A). Magnetic resonance angiography (MRA) revealed segmental narrowing of the right posterior cerebral artery with the beaded appearance characteristic of vasculitis (Figure 1B).

Her symptoms and mild headache continued but she did not want to take analgesics because they were not very effective. She was discharged 1 week after admission.

We checked a repeat brain MRI and MRA about 4 months after the first examination. The right occipital infarction had faded with mild atrophy and the beading of the right posterior cerebral artery had recovered slightly in the proximal portion. Although left superior quadrant hemianopia remained, she said that she got used to the symptom. The headaches also continued but after we explained the result of the MRI, she stopped coming and has not been seen in follow-up since then.

DISCUSSION

The reported case concerns a young woman who had no other risk factors for cerebrovascular accidents than smoking and alcohol consumption. Absent were hypertension, hyperlipidemia, diabetes, intracranial vascular malformation, vasculitis caused by collagen disease, and any coagulation abnormalities. We conclude that the cause of cerebral infarction was methamphetamine abuse.

Methamphetamine and amphetamine are sympathomimetic drugs. They are postulated to be the cause of acute drug-induced hypertension, vasoconstriction, and progressive necrotizing vasculitis (2–4). There are many reports of intracranial hemorrhage occurring soon after administration of methamphetamine or amphetamine (5–7). Some cases were ischemic strokes, of which onset times since last use were up to 2 weeks (8–10). We are unaware of any reported cases of delayed strokes following methamphetamine abuse, but we have noted the case report of 6-month delayed ischemic stroke associated with cocaine use which is also known to cause vascular complications (11). In addition, ephedra is another sympathomimetic drug and may cause vasculitis like methamphetamine. Wooten et al. reported late vasculitis related to ephedrine abuse (12). Recently, there are more reports that show ephedra increasing the risk of strokes (13,14). Because legal dietary supplements contain ephedra, we should expect to see more cases.

In our case the mechanism of delayed stroke remains

unclear. We propose that chronic vasculitis insidiously continued as the patient continued to experience headache. Infarction occurred 3 months after the drug use. It is quite interesting that the beaded vasculitis was limited to the right posterior cerebral artery and was clearly visible in MR angiography in our case.

The number of drug abusers among young people has been increasing in various countries, therefore we should consider delayed strokes such as our case, as well as acute cases, when we encounter unusual cerebrovascular attacks in young adults.

REFERENCES

1. Caplan LR, Hier DB, Banks G. Current concepts of cerebrovascular disease—stroke: stroke and drug abuse. *Stroke* 1982;13:869–72.
2. Citron BP, Halpern M, McCarron M, et al. Necrotizing angiitis associated with drug abuse. *N Engl J Med* 1970;283:1003–11.
3. Margolis MT, Newton TH. Methamphetamine (“speed”) arteritis. *Neuroradiology* 1971;2:179–82.
4. Brust JCM. Vasculitis owing to substance abuse. *Neurol Clin* 1997;15:945–57.
5. Delaney P, Estes M. Intracranial hemorrhage with amphetamine abuse. *Neurology* 1980;30:1125–8.
6. Harrington H, Heller HA, Dawson D, Caplan L, Rumbaugh C. Intracerebral hemorrhage and oral amphetamine. *Arch Neurol* 1983;40:503–7.
7. Imanse J, Vanneste J. Intraventricular hemorrhage following amphetamine abuse. *Neurology* 1990;40:1318–9.
8. Rothrock JF, Rubenstein R, Lyden PD. Ischemic stroke associated with methamphetamine inhalation. *Neurology* 1988;38:589–92.
9. Yen DJ, Wang SJ, Ju TH, et al. Stroke associated with methamphetamine inhalation. *Eur Neurol* 1994;34:16–22.
10. Perez JA Jr, Arsura EL, Strategos S. Methamphetamine-related stroke: four cases. *J Emerg Med* 1999;17:469–71.
11. Deringer PM, Hamilton LL, Whelan MA. A stroke associated with cocaine use. *Arch Neurol* 1990;47:502.
12. Wooten MR, Khangure MS, Murphy MJ. Intracerebral hemorrhage and vasculitis related to ephedrine abuse. *Ann Neurol* 1983;13:337–40.
13. Haller CA, Benowitz NL. Adverse cardiovascular and central nervous system events associated with dietary supplements containing ephedra alkaloids. *N Engl J Med* 2000;343:1833–8.
14. Chen C, Biller J, Willing SJ, Lopez AM. Ischemic stroke after using over the counter products containing ephedra. *J Neurol Sci* 2004;217:55–60.